Note: This copy is for your personal non-commercial use only. To order presentation-ready copies for distribution to your colleagues or clients, contact us at www.rsna.org/rsnarights.

RadioGraphics

MR Imaging of Patellar Instability: Injury Patterns and Assessment of Risk Factors[1]

Gerd Diederichs, MD • Ahi S. Issever, MD • Sven Scheffler, MD

ONLINE-ONLY CME

See www.rsna.org/education/rg_cme.html

LEARNING OBJECTIVES

After reading this article and taking the test, the reader will be able to:

- Evaluate MR images to identify typical injuries that are seen in patients after patellar dislocation.
- Identify the most important risk factors that contribute to patellar instability.
- Describe current treatment options and surgical procedures.

TEACHING POINTS

See last page

First-time patellar dislocation typically occurs with twisting knee motions, during which the medial ligamentous stabilizers rupture, and the patella strikes against the lateral femoral condyle. The typical injury pattern is a tear of the medial patellofemoral ligament (MPFL) and bone bruises of the patella and the lateral femoral condyle. Additionally, complex injuries to bone, cartilage, and ligaments may occur. The ensuing loss of medial restraint favors future patellar dislocations, especially if additional risk factors are present. Recurrent patellar dislocations usually occur in individuals with anatomic variants of the patellar stabilizers, such as trochlear dysplasia, patella alta, and lateralization of the tibial tuberosity. Magnetic resonance (MR) imaging is reliable in identifying risk factors for chronic patellar instability and in assessing knee joint damage associated with patellar dislocation. MR imaging can thus provide important information for individually tailored treatment. Patients with primary patellar dislocation without severe internal derangement who lack major risk factors can be treated conservatively. Patients with pronounced ligamentous tears or large osteochondral lesions require prompt surgery. In addition, surgical correction of anatomic variants will help reduce the potential for chronic instability. The most common procedures, in addition to MPFL reconstruction, include trochleoplasty, medialization of the tibial tuberosity, and medial capsular plication. For comprehensive assessment of patellar dislocation, a radiologist should be able to identify typical injury patterns, know standard methods to assess risk factors for patellar instability, and be familiar with surgical options.

©RSNA, 2010 • *radiographics.rsna.org*

Abbreviation: MPFL = medial patellofemoral ligament

RadioGraphics 2010; 30:961–981 • **Published online** 10.1148/rg.304095755 • **Content Codes:** MK MR

[1]From the Department of Radiology (G.D., A.S.I.) and the Center for Musculoskeletal Surgery (S.S.), Charité-Universitätsmedizin Berlin, Campus Charité Mitte, Charitéplatz 1, 10117 Berlin, Germany. Received September 30, 2009; revision requested December 15 and received January 6, 2010; accepted January 18. For this CME activity, the authors, editors, and reviewers have no relevant relationships to disclose. **Address correspondence to** G.D. (e-mail: *gerd.diederichs@charite.de*).

©RSNA, 2010

Introduction

Most patients with patellar dislocation are young and active individuals, with women in the 2nd decade of life having a high risk (1). The prevalence of acute patellar dislocation is 6–77 per 100,000 population (1,2). Nearly half of all patients with a first-time dislocation will sustain further dislocations after initial conservative management (3). During the recovery period, most patients have restricted mobility, and two-thirds of them report limitations in strenuous activities (4). Chronic instability of the patellofemoral joint and recurrent dislocation may lead to progressive cartilage damage and severe arthritis if not treated adequately.

Magnetic resonance (MR) imaging of the knee is widely used after first-time or recurrent patellar dislocation. MR imaging is recognized as a standard procedure and has replaced diagnostic arthroscopy as the primary diagnostic modality. MR imaging has been shown to be a highly sensitive cross-sectional imaging modality for detecting capsular, ligamentous, cartilaginous, and bone injuries associated with patellar dislocation (5–11). Moreover, MR images can be used to assess anatomic variants that may contribute to chronic patellar instability (12–16). The most important factors predisposing to patellar instability include trochlear dysplasia, patella alta (high position of the patella), and excessive lateral distance between the tibial tubercle and the trochlear groove (lateralization of the tibial tuberosity). Characterization and quantification of these anatomic anomalies will reveal the individual mechanism of patellar instability and help the orthopedic surgeon choose the optimal treatment. The aim of surgery is twofold: to repair the knee damage caused by patellar dislocation and to correct those anomalies that are known to contribute to future dislocations.

Teaching Point

The purpose of this article is to review the typical MR imaging findings in the knee after dislocation of the patella, including predisposing anatomic factors, and to provide a short outline of the most important surgical techniques currently in use.

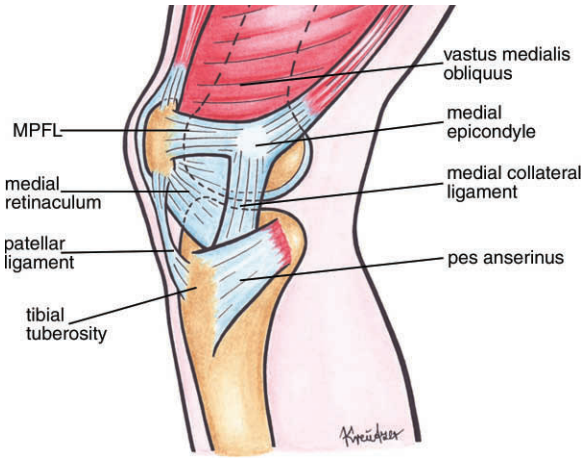

Figure 1. Drawing of anatomic structures of the knee (medial view). Anatomic structures obscuring the MPFL have been left out.

Normal Anatomy

Normal function of the patellofemoral joint is ensured by passive stabilizers (bones and ligaments) and active stabilizers (extensor muscles). Joint geometry is crucial for stabilization during movement. The femoral sulcus must be deep enough and the lateral trochlea high enough to ensure safe tracking throughout the range of patellofemoral flexion. The medial ligamentous stabilizers prevent lateral displacement of the patella during movement. The most important ligamentous stabilizers are the medial patellar retinaculum and the medial patellofemoral ligament (MPFL) (Fig 1). In the routine clinical setting, the medial patellar retinaculum and MPFL are best demonstrated with axial and sagittal T2-weighted fast spin-echo or gradient-echo pulse sequences at MR imaging. The medial patellar retinaculum and MPFL are depicted as well-defined low-signal-intensity bands and are often difficult to distinguish from each other. The patellar third of the MPFL blends with the vastus medialis obliquus muscle, which results in a broader attachment and greater conspicuity at MR imaging. The femoral third of the ligament is thin and may not be depicted (5). The vastus medialis obliquus, which arises from the medial part of the femur and attaches to the proximal

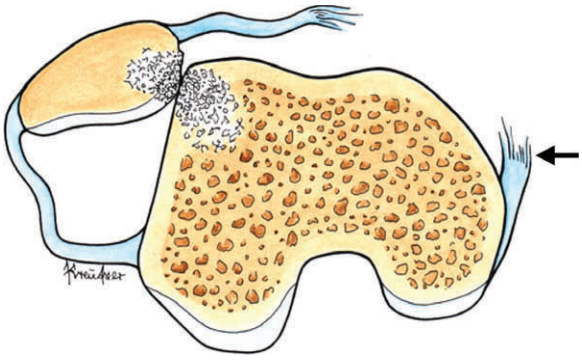

Figure 2. Drawing of complete lateral patellar dislocation, as seen from below. The MPFL is ruptured (arrow), and the inferomedial border of the patella touches the lateral femoral condyle.

portion of the patella, also has an important role in medial stabilization.

Warren and Marshall (17) proposed a model that distinguishes three layers of patellar support on the medial side of the knee: The outer superficial layer (layer I) is made up of the fascia of the sartorius muscle. The intermediate layer (layer II) consists of the MPFL, which extends in a fan-shaped manner from the medial patellar edge to the femur along the medial epicondyle. The patellar attachment of the MPFL blends with the medial patellar retinaculum, which also attaches to the medial patellar edge. The joint capsule is the innermost layer (layer III).

Patellofemoral Instability

Patellar dislocation is characterized by the complete loss of contact between the patellofemoral joint surfaces. In almost all cases, the patella dislocates laterally. The most common mechanism of first-time patellar dislocation is a flexed position of the knee with internal rotation on a planted foot with a valgus component (18). In addition, a traumatic component in the form of a mild to severe external force may be involved, which results in disruption of medial ligaments (Fig 2). Because a dislocated patella is unlikely to return to its normal position, healing and scar formation of the soft-tissue structures occur with the patella out of place. Therefore, there may be persistent medial instability even after the patella has been repositioned. When combined with additional risk factors precluding adequate containment and tracking of the patella, this residual laxity of medial ligaments may lead to severe chronic instability with time. Trauma alone rarely causes patellar dislocation in an individual without underlying predisposing factors. The most common predisposing factors for patellar instability include trochlear dysplasia, patella alta, and lateralization of the tibial tuberosity. How these anomalies can be diagnosed and characterized with MR imaging is described in the following paragraphs. Important secondary factors contributing to patellofemoral instability are femorotibial malrotation, genu recurvatum (back-knee), and ligamentous laxity (Ehlers-Danlos and Marfan syndromes).

Teaching Point

Risk Factors and Assessment with MR Imaging

Trochlear Dysplasia

Trochlear dysplasia has been identified as one of the main factors contributing to chronic patellofemoral instability (19). In individuals with trochlear dysplasia, the trochlear joint surface is flattened proximally, and the concavity is less pronounced distally. This combination results in considerable loss of lateral patellar tracking and in lateral dislocation of the patella at the initiation of flexion. In the more severe expressions of trochlear dysplasia, the trochlear surface may even become convex with increasing hypoplasia of the medial joint surface. Because of its high frequency of occurrence bilaterally, trochlear dysplasia is believed to be a developmental anomaly.

The classic criteria for diagnosing trochlear dysplasia were defined for conventional radiographs: The "crossing sign" is a line represented by the deepest part of the trochlear groove crossing the anterior aspect of the condyles, assessed from lateral radiographs. The "double contour sign" is a double line at the anterior aspect of the condyles and is present if the medial condyle is hypoplastic. A decreased trochlear depth and a large sulcus

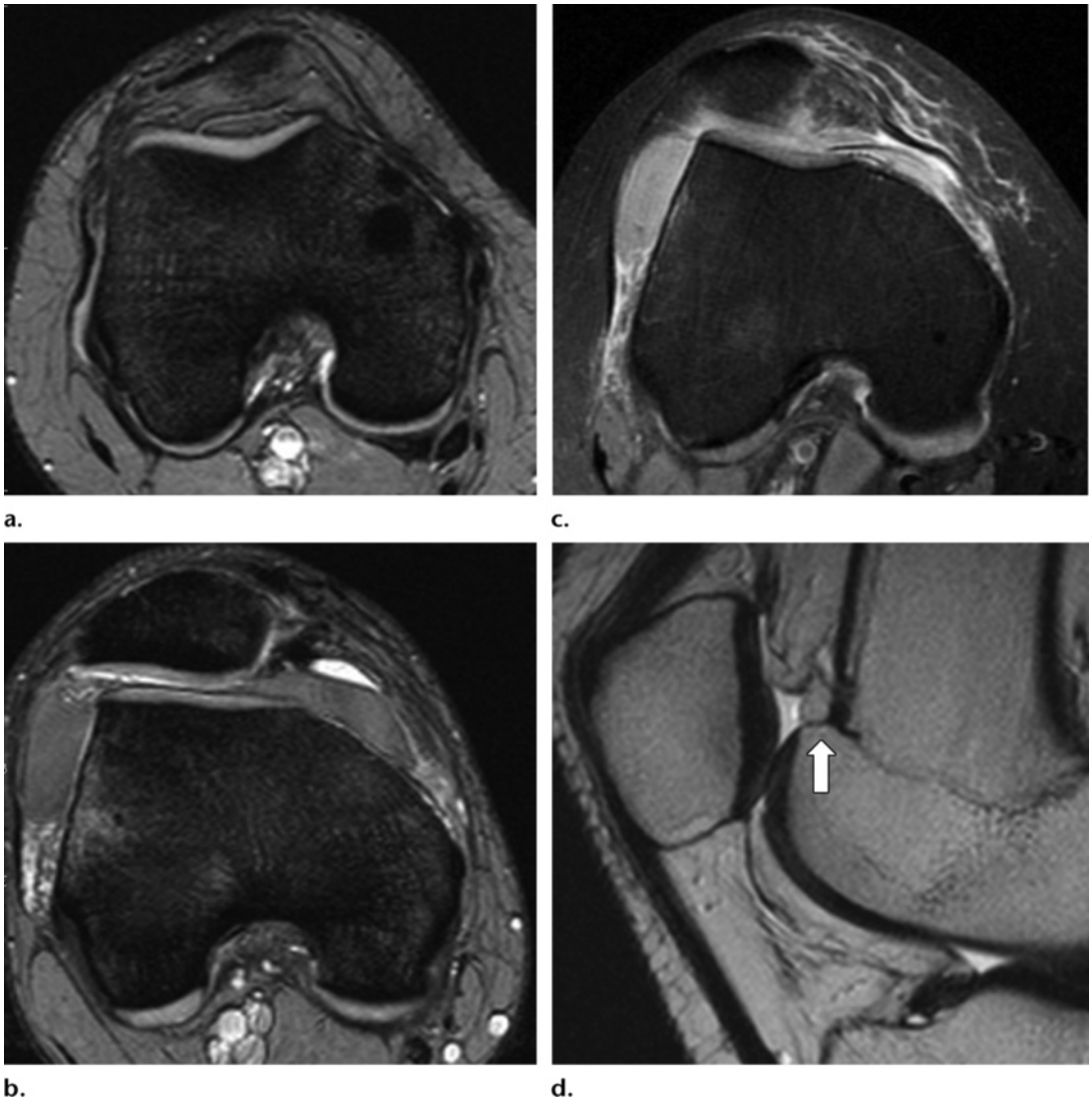

Figure 3. Four types of trochlear dysplasia, according to the classification of Dejour et al (19,20), on fat-saturated T2-weighted MR images. **(a)** Axial image shows type A dysplasia: Trochlear morphologic structures are preserved, but the sulcus is shallow. **(b)** Axial image shows type B dysplasia: flat, horizontally oriented trochlear joint surface. **(c)** Axial image shows type C dysplasia: flat, obliquely oriented trochlear joint surface with facet asymmetry. **(d)** Sagittal image shows type D dysplasia: same as type C but with a prominent bone protrusion (arrow) on the parasagittal view (cliff pattern).

angle can be assessed from standard axial radiographs. Signs of trochlear dysplasia are found in more than 85% of patients with patellar dislocation (19). On the basis of these criteria, Dejour et al (20) proposed a classification distinguishing four morphologic types of trochlear dysplasia: *(a)* type A: normal shape of the trochlea preserved but a shallow trochlear groove; *(b)* type B: markedly flattened or even convex trochlea; *(c)* type C: asymmetric trochlear facets, with the lateral facet being too high and the medial facet being hypoplastic, which results in the flattened joint surface forming an oblique plane; and *(d)* type D: in addition to the features of type C, a vertical link between medial and lateral facets (cliff pattern on

RadioGraphics

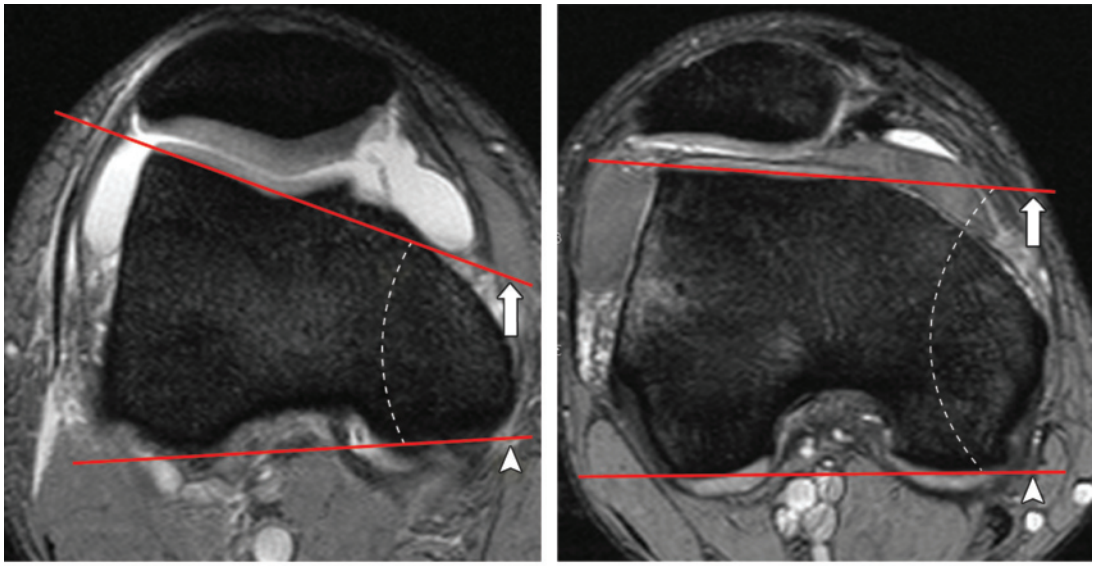

a. b.

Figure 4. Lateral trochlear inclination assessed on axial fat-saturated T2-weighted MR images (11). A line (arrow) is drawn along the subchondral bone of the lateral trochlear facet, and a second line (arrowhead) is drawn along the posterior aspect of the femoral condyles. The angle between the two lines is the inclination angle (dashed line). An inclination angle of less than 11° indicates trochlear dysplasia. **(a)** Image shows a normal trochlea, with an inclination angle of 24°. **(b)** Image shows type B trochlear dysplasia, with an inclination angle of only 7°.

parasagittal images). The four types of trochlear dysplasia have direct implications for the best surgical approach to correct patellar instability. However, the effects of two-dimensional imaging may lead to misinterpretation of the patellar morphologic structure on conventional radiographs (21). In comparison, axial and sagittal MR images allow accurate identification of the type of trochlear anomaly (Fig 3) (22).

Numerous quantitative methods have been proposed for diagnosing trochlear dysplasia with conventional radiographs. For instance, a sulcus angle of more than 150° has been defined as indicating pathologic flattening of the joint surface on axial projections. Investigators correlating measurements of this angle obtained with conventional radiography and with MR imaging found substantial differences and showed that measurements with conventional radiographs underestimate the angle and are subject to other pitfalls that may lead to misinterpretation (22). MR imaging has been shown to allow highly accurate and reproducible measurements of the femoral sulcus from both the subchondral bone and the articular cartilage; measurement from the articular cartilage may be more relevant because it constitutes the actual joint surface (16). Techniques for quantifying the degree of dysplasia have been standardized for MR imaging. Trochlear dysplasia can be evaluated at MR imaging by determining lateral trochlear inclination, trochlear facet asymmetry, or trochlear depth (12,15).

Lateral Trochlear Inclination.—The most superior section showing trochlear cartilage is selected from the axial dataset. This image serves to measure the angle (inclination angle) between a line drawn along the subchondral bone of the lateral trochlear facet and a tangential line connecting the posterior aspect of the femoral condyles (Fig 4). The threshold for trochlear dysplasia is an inclination angle of 11°, with an inclination angle of less than 11° indicating trochlear dysplasia (sensitivity of 93%, specificity of 87%) (12).

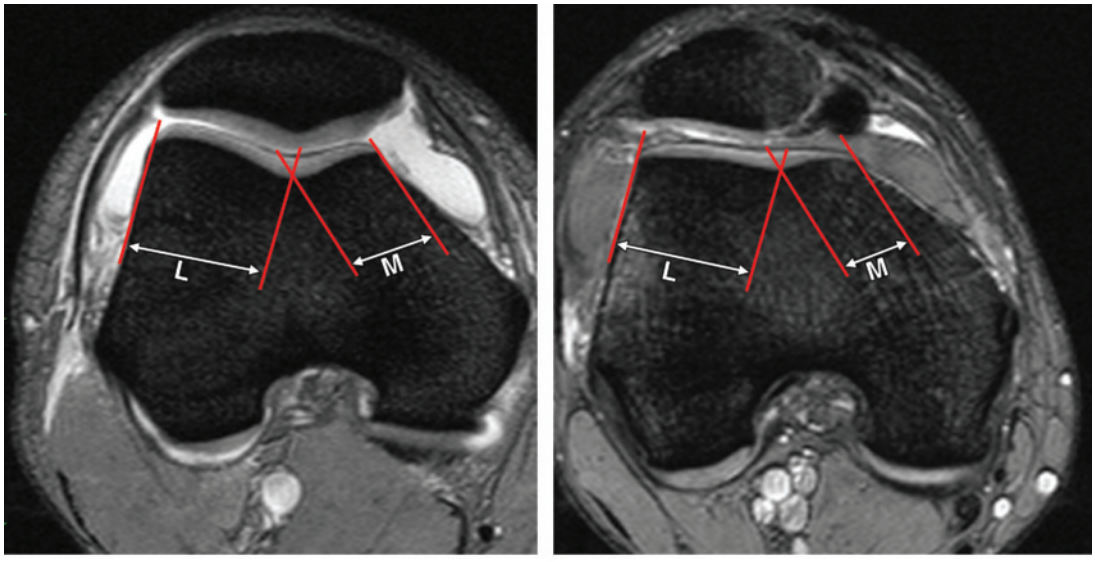

a. b.

Figure 5. Trochlear facet asymmetry assessed on axial fat-saturated T2-weighted MR images (15). Asymmetry of the medial facet length *(M)* and the lateral facet length *(L)* is calculated as the ratio of the medial facet length divided by the lateral facet length expressed as a percentage ($M/L \times 100\%$). A trochlear facet ratio of less than 40% indicates dysplasia. **(a)** Image shows a normal trochlea, with a facet ratio of 68%. **(b)** Image shows a dysplastic trochlea, with a facet ratio of 38%.

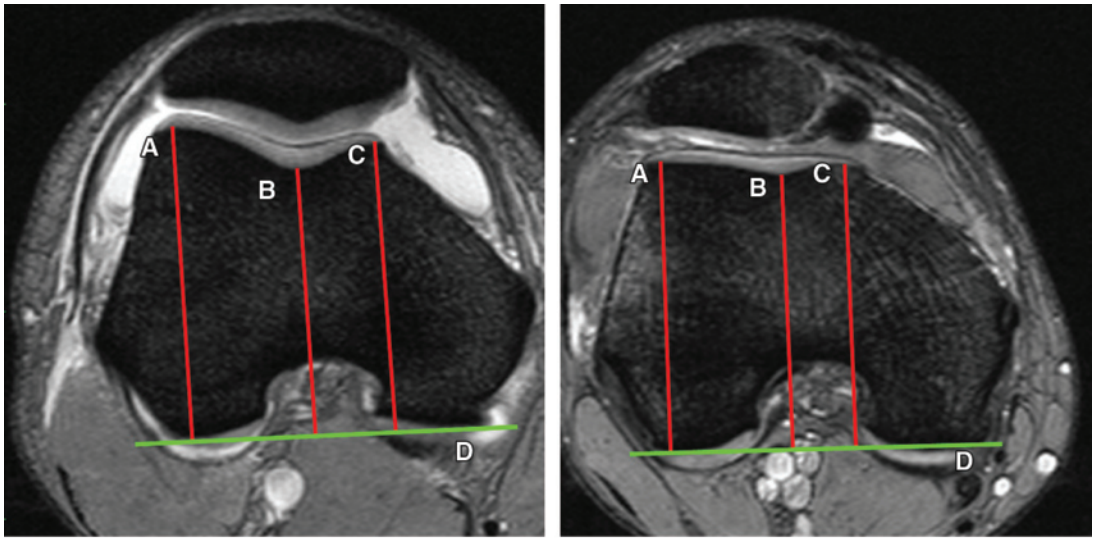

a. b.

Figure 6. Trochlear depth assessed on axial fat-saturated T2-weighted MR images (15). A line drawn parallel to the posterior aspect of the femoral condyles serves as a reference line (line *D)*. The lines drawn perpendicular to the reference line indicate the largest anteroposterior diameters of the lateral (line *A)* and medial (line *C)* trochlear facets and the deepest point of the sulcus (line *B)*. Trochlear depth is calculated as follows: $(A + C/2) - B$. A trochlear depth of 3 mm or less is assumed to indicate dysplasia. **(a)** Image shows a normal trochlea, with a trochlear depth of 12 mm. **(b)** Image shows a dysplastic trochlea with marked flattening, indicated by a trochlear depth of 1.5 mm.

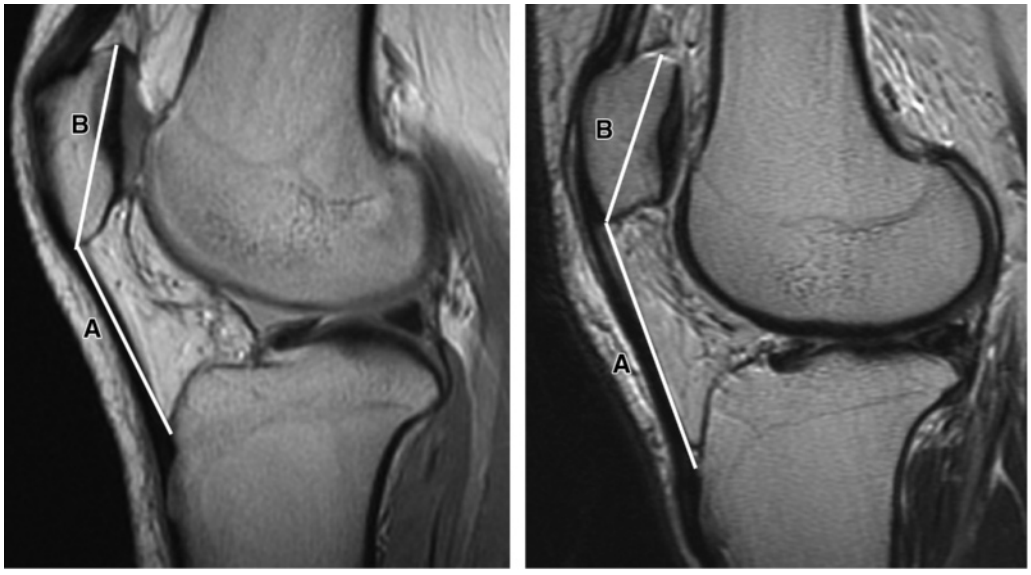

a. b.

Figure 7. Patellar height ratio assessed on sagittal intermediate-weighted MR images. The length of the patellar tendon (line *A)* is measured posteriorly from the patellar apex to its attachment to the tibial tuberosity and is divided by the longest superoinferior diameter of the patella (line *B)* to obtain the patellar height ratio (PHR), as follows: PHR = *A*/*B*. A patellar height ratio of more than 1.3 indicates a high-riding patella (patella alta). **(a)** Image shows a knee with a patellar height ratio of 1, which is in the normal range. **(b)** Image shows a high-riding patella, with a patellar height ratio of 1.4.

Trochlear Facet Asymmetry.—Trochlear facet asymmetry is calculated as the ratio of the length of the medial trochlear facet to the length of the lateral trochlear facet measured at 3 cm above the tibiofemoral joint cleft (Fig 5). A trochlear facet ratio of less than 40% is defined as indicating dysplasia (sensitivity of 100%, specificity of 96%) (15).

Trochlear Depth.—The deepest point of the sulcus is determined at the same level as trochlear facet asymmetry is determined (Fig 6). Trochlear dysplasia is assumed if the trochlear depth is 3 mm or less (sensitivity of 100%, specificity of 96%) (15).

Patella Alta

A patella alta, or high-riding patella, is a patella that is too high above the trochlear fossa and occurs when the patellar tendon is too long (Fig 7) (23). Patella alta is considered a main factor in patellofemoral misalignment because with patella alta, the degree of flexion needs to be higher for the patella to engage in the trochlea, compared with a normal knee (24). This problem leads to reduced patellar contact area and decreased bone stability in shallow degrees of flexion. Also, a genu varum deformity of the knee contributes to a patella alta configuration by shortening the distance between the quadriceps myotendinous junction and the tibial tuberosity. In this setting, the extensor mechanism becomes the hypotenuse of a triangle, and this configuration may predispose to lateral patellar subluxation.

About 25% of the patients with acute patellar dislocation have a high-riding patella depicted on MR images, and as many as 50% of the patients have a high-riding patella depicted on projection radiographs (5,14). Note, however, that patella alta is a normal anatomic variant that is asymptomatic in most individuals (25). Nevertheless, the diagnosis of a high-riding patella is important because it increases the risk of patellar dislocation in conjunction with other factors.

Numerous parameters for measuring the vertical distance of the patella from the trochlear joint surface have been proposed for conventional

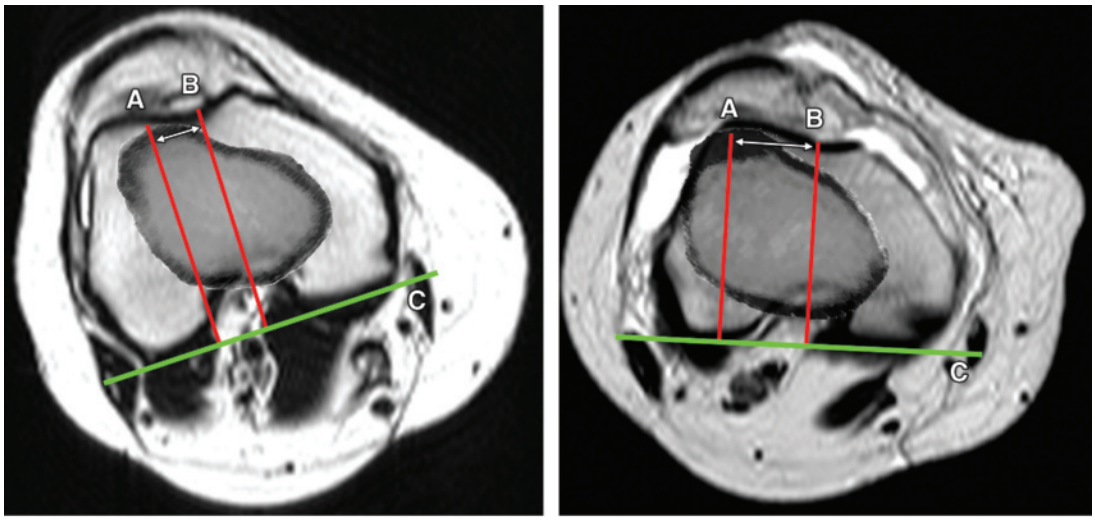

a. b.

Figure 8. Distance from the tibial tubercle to the trochlear groove assessed on axial fast T2-weighted MR images. The distance (double-headed arrow) from the deepest point of the trochlea (line *B)* to the middle of the tibial tubercle (line *A)* is measured, again by using the posterior plane of the condyles as the reference line (line *C)*. A distance between the tibial tubercle and the trochlear groove of less than 15 mm is considered normal. Distances between 15 and 20 mm are borderline, and distances of more than 20 mm indicate marked lateralization of the tuberosity. **(a)** Image shows a normal distance of 12 mm between the tibial tubercle and the trochlear groove. **(b)** Image shows a distance of 22 mm, which is higher than the normal range. For illustration, the image of the tibia was cut out at the level of the tuberosity and superimposed on the axial image through the trochlea. In the clinical setting, the lines can be transferred from the axial image of the sulcus to the axial image of the tuberosity on the workstation.

radiographs (26). These parameters are based on osseous landmarks and usually determine the patellar length in relation to its distance from the tuberosity or the femorotibial joint cleft. Some of these parameters have also been determined with MR images, and the results suggest that, in general, these techniques can be transferred to MR imaging (13,23,25–28). However, unlike conventional radiographs, MR images depict the true three-dimensional anatomic structure of the patellofemoral joint and its ligamentous structures. The length of the patellar tendon can be reliably measured on MR images, which results in a higher sensitivity for predicting instability compared with the classic indices used at conventional radiography (22).

For MR imaging, the measurement of the patellar height ratio is recommended because published normal values are available. The patellar height ratio is calculated as the length of the patellar tendon measured posteriorly from the apex of the patella to its attachment to the tibial tuberosity on a sagittal MR image, divided by the longest superoinferior diameter of the patella (Insall-Salvati index) (Fig 7). The normal patellar height ratio reported is 1.1 (standard deviation, 0.1). Patella alta is defined as a patellar height ratio of more than 1.3, which is the normal ratio plus two standard deviations (sensitivity of 78%, specificity of 68%) (13,24,27).

The patellotrochlear index has recently been proposed as a more accurate reflection of the functional height of the patella. This index is a measure of the patellofemoral contact area determined from sagittal MR images (29). A mean patellotrochlear index of 32% has been reported for a normal population (standard deviation, 12%), whereas patients with patellofemoral instability have a mean value of 15% (27). Studies remain to be done to validate thresholds and give clinically applicable recommendations.

Distance from Tibial Tubercle to Trochlear Groove

The position of the tibial tubercle is crucial for the inferolateral force vector of the patella. In a normal joint, the tibial tuberosity lies vertically

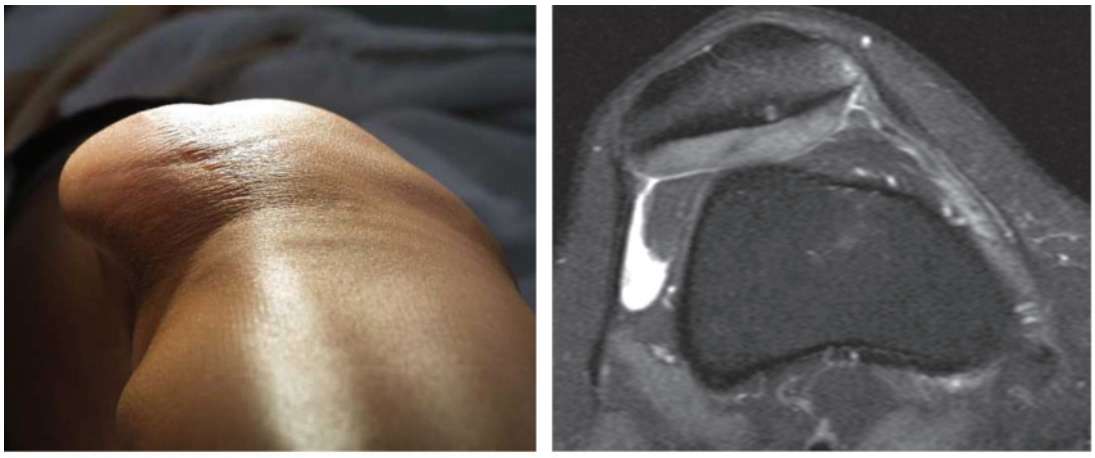

a. b.

Figure 9. Lateralized position of the patella after dislocation. **(a)** Photograph shows subluxation of the patella in a 27-year-old woman. **(b)** Corresponding axial T2-weighted fat-saturated MR image shows that the patella is displaced over the lateral trochlear facet by nearly half of its transverse diameter.

under the femoral sulcus, directing the force vector inferiorly during knee bending. However, if there is excessive lateralization of the tibial tuberosity, the patella is pulled laterally during flexion. Therefore, excessive lateral displacement is considered a risk factor for instability (19,30). A tibial tubercle–trochlear groove distance of more than 20 mm is nearly always associated with patellar instability (19). Values of 15–20 mm are considered borderline. On MR images, the mediolateral distance of the tibial tuberosity from the deepest point of the trochlea can be measured (Fig 8) (31). Axial fast T2-weighted MR images from above the patella to below the tibial tuberosity can be acquired in less than 1 minute. However, measurement of the lateral distance between the tibial tubercle and the trochlear groove is less accurate in individuals with severe trochlear dysplasia because no deepest point of the trochlea can be defined.

MR Imaging Findings after Patellar Dislocation

After an acute trauma to the knee, severe pain and effusion may limit the clinical examination, and functional tests may be precluded. Some patients may be aware that patellar dislocation has occurred, or the patella is still displaced at clinical examination (Fig 9a). However, the exact mechanism of injury may not be elucidated if the patient does not recall the event or if the patella has spontaneously returned to its normal position. Thus, patellar dislocation is not suspected beforehand in as many as 50% of the patients undergoing imaging (8). MR imaging can be used to diagnose prior patellar dislocation on the basis of typical injury patterns. In general, deformity or edema of the inferomedial patella and the lateral condyle, in conjunction with MPFL disruption and patellar lateralization, is diagnostic for recent patellar dislocation (5–11,18). Additionally, marked knee effusion and internal derangement of the knee may be present.

Teaching Point

Injuries to Medial Patellar Stabilizers

Disruption of medial ligamentous stabilizers, such as the MPFL and the medial patellar retinaculum, is diagnosed on MR images in 70%–100% of the patients examined after lateral patellar dislocation (5–11). MR imaging has a sensitivity of more than 80% when correlated with open exploration (8,9). The MPFL and the medial patellar retinaculum may be difficult to differentiate, especially at their patellar insertion, where they blend with each other. Dividing the ligaments into three regions appears to be useful for reporting the site of the tear: *(a)* the patellar insertion (anterior third), *(b)* the midsubstance, and *(c)* the femoral origin (posterior third) (5). Between 50% and 90% of the injuries to the medial ligaments involve the patellar insertion (5,6). About one-fourth of these patients

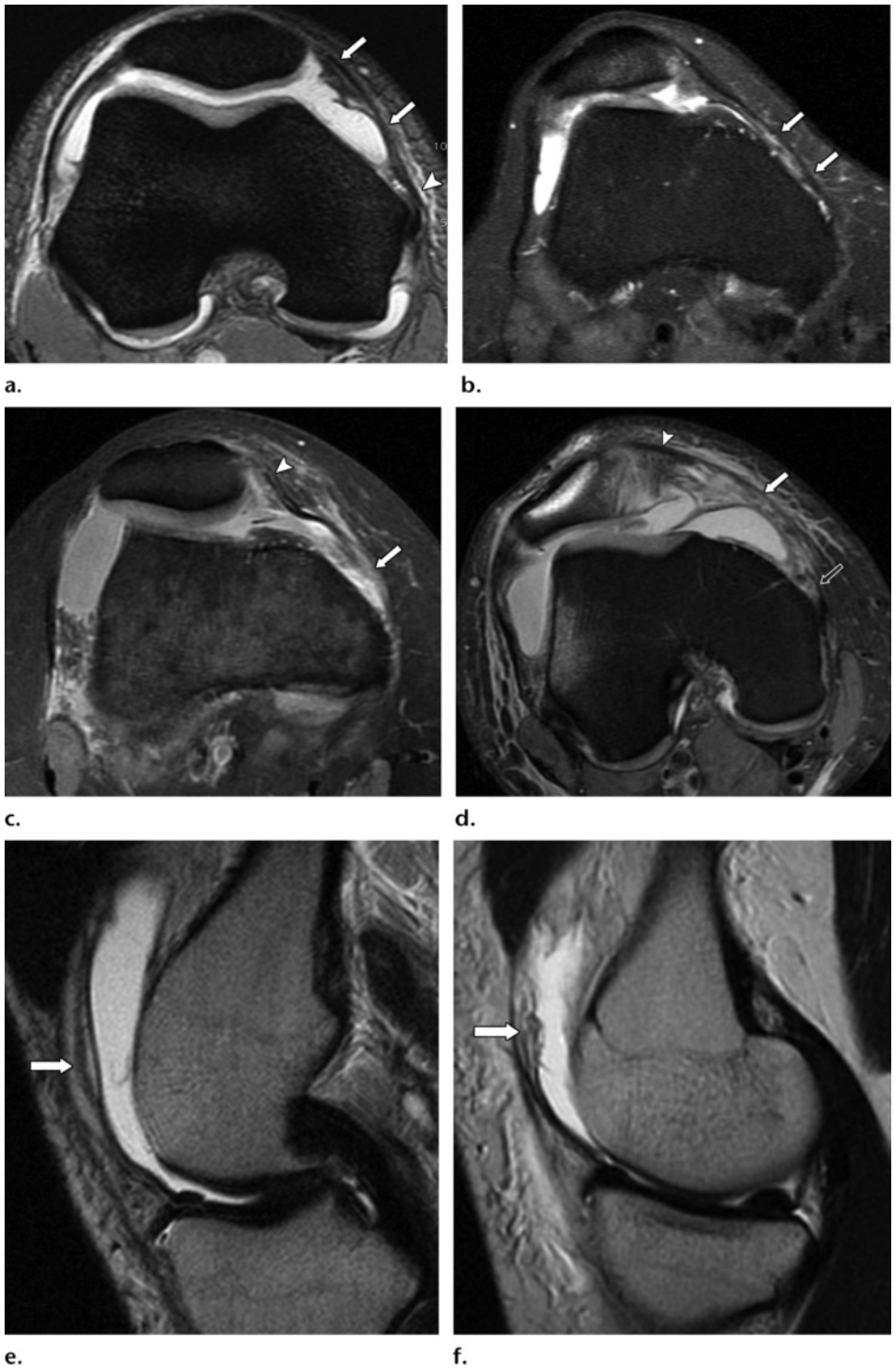

Figure 10. Medial stabilizers assessed on T2-weighted fat-saturated MR images. **(a)** Axial image shows an intact MPFL (arrows) in a 27-year-old man. There is also continuous depiction of the MPFL attachment to the medial epicondyle (arrowhead). **(b)** Axial image shows relevant lateralization of the patella in a 24-year-old woman. The MPFL appears irregular and is surrounded by edema in the femoral third, which is caused by a long partial tear (arrows). **(c)** Axial image shows detachment of the femoral MPFL insertion (arrow) and a partial tear of the patellar insertion (arrowhead) in a 39-year-old woman. **(d)** Axial image shows complete disruption of the medial stabilizers (solid arrow) in a 25-year-old man. Only fragments of the patellar insertion (arrowhead) and the femoral insertion (open arrow) are depicted. Note that sagittal images can be helpful in assessing damage to the MPFL. **(e)** Sagittal image of a 28-year-old man shows a normal MPFL (arrow) forming the intermediate layer of the medial stabilizers. **(f)** Sagittal image of the same patient as in **c** shows a full-thickness tear (arrow) of the MPFL in the femoral third.

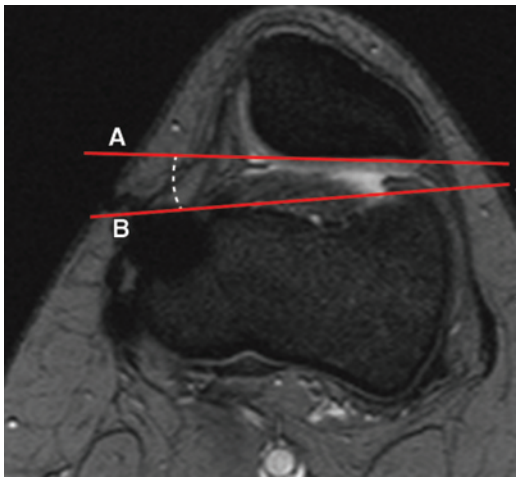

Figure 11. Lateral patellofemoral angle assessed on an axial T2-weighted fat-saturated MR image, which shows patellar tilt caused by rupture of medial ligaments in an 18-year-old woman after prior surgery. The patellofemoral angle (dashed line) is demonstrated as the angle between a line drawn along the lateral joint surface of the patella (line *A)* and a line drawn along the anterior aspect of the condyles (line *B)*. A patellofemoral angle opening laterally is considered normal. An angle opening medially indicates patellar tilt.

have additional damage to a second region, and one-fifth of the patients show injury to all three portions (5). In one-fourth of the cases, the MPFL is ruptured at the femoral attachment (5,6), which can also occur in the form of an avulsion tear of the epicondyle (8). Accurate characterization of the type of ligamentous tear is important because the findings from the most recent studies indicate that femoral avulsion is a predictor of chronic instability, which is why the site of the tear may directly affect surgical planning (32).

A full-thickness tear of a medial stabilizer is seen at MR imaging as complete disruption of the ligament and the presence of local soft-tissue edema, which has high signal intensity on T2-weighted images (Fig 10). Wavy or retracted fibers surrounded by effusion are conspicuous for complete disruption. If there are multiple injuries involving all compartments, no intact low-signal-intensity ligament may be seen on T2-weighted images.

A partial tear is characterized by an irregular appearance or partial discontinuity of the ligament and the presence of tendinous or peritendinous edema. Disruption of the ligaments at the patellar insertion is partial in two-thirds of the cases and complete in one-third. Overall, the finding of typical edema of the patellar border and femoral condyles makes it likely that there is damage to at least one compartment of the medial ligamentous stabilizers.

Patellar Defects

After rupture of the medial compartment, the patella typically does not fully return to its normal position, even after reduction. The majority of patients will show subluxation or tilt of the patella at MR imaging (5,7). Subluxation is defined as partial lateral dislocation of the patella from the femoral groove and is evaluated subjectively (Fig 9). Patellar tilt is diagnosed by determining the lateral patellofemoral angle, which is calculated from lines drawn along the patella and along the condyles (Fig 11) (33). It should be noted that accurate patellofemoral alignment cannot be truly assessed in normal MR imaging settings because the knee is positioned in full extension. Also, a large effusion may influence patellofemoral alignment.

Bone edema resulting from contusion of the medial aspect of the patella and the femoral condyle is a typical finding after patellar dislocation. Bone edema has high signal intensity on T2-weighted images and low signal intensity on T1-weighted images (Fig 12). The MR imaging appearance varies with the force of dislocation, the interval between the event and imaging, and also the amount of T2 weighting.



a.



b.

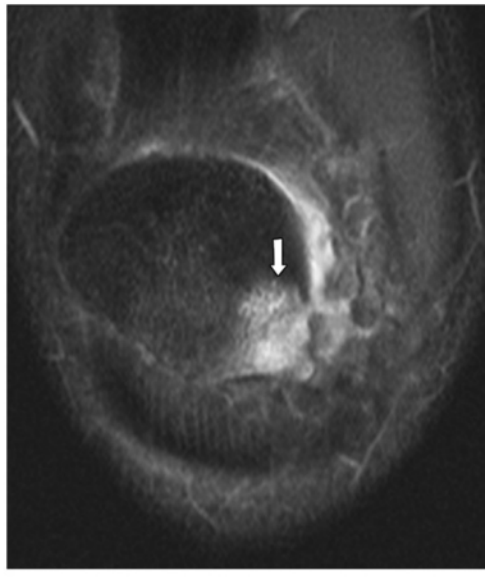

c.

Figure 12. Bone edema after patellar dislocation with contusion of the patella and lateral femoral condyle. **(a)** Axial slightly T2-weighted fat-saturated MR image shows circumscribed edema (arrow) of the lateral condyle in a 23-year-old woman. **(b)** Coronal heavily T2-weighted fat-saturated MR image depicts extensive bone edema (arrow) in an 18-year-old man. **(c)** Coronal heavily T2-weighted fat-saturated MR image shows a bone bruise (arrow) of the inferomedial aspect of the patella in a 24-year-old man.

More than two-thirds of the patients will show chondral or osteochondral lesions of the medial patella (Fig 13), which are detected at MR imaging with a sensitivity of more than 90% but are overlooked on conventional radiographs in 40%–60% of the cases (34–38). Nearly half of the cases with osteochondral defects have the classic finding of a concave impaction deformity of the inferomedial patella, which is considered a highly specific sign of prior patellar dislocation (Fig 13c) (5,7). Impression of the osteochondral surface of the patella is predominant in impaction-type injuries, and separated bone fragments are the major finding in avulsion-type injuries. The radiologist's diagnosis is pivotal because prompt surgery is indicated if lesions are larger than about 1 cm^2, and surgery ideally should be performed within 1 week of the event.

For detection of central cartilage defects, standard clinical pulse sequences are highly reliable if the lesions are large, for example, grade III or IV lesions (Fig 14) (35,37–40). The diagnostic

Figure 14. Different grades of chondral defects of the patellar cartilage on axial T2-weighted fat-saturated MR images. ▶ **(a)** Image shows a small superficial chondral defect (arrow) of the central portion of the patella (grade II defect) in an 18-year-old woman. **(b)** Image depicts a high-grade full-thickness cartilage lesion (arrow) (grade IV defect) with a deep vertical tear in a 21-year-old woman. **(c)** Image shows a broad defect (arrow) of the medial facet, with a dislocated cartilage fragment, in a 25-year-old man. **(d)** Image depicts extensive damage to the central portion of the patellar cartilage (arrows) in a 19-year-old woman. A cartilage flake measuring almost 2 cm is dislocated into the tibiofemoral joint space.

RadioGraphics

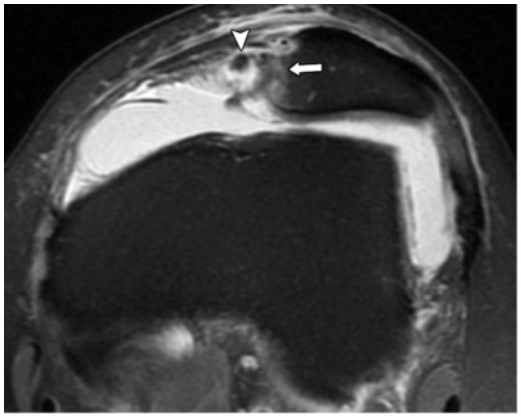

a.

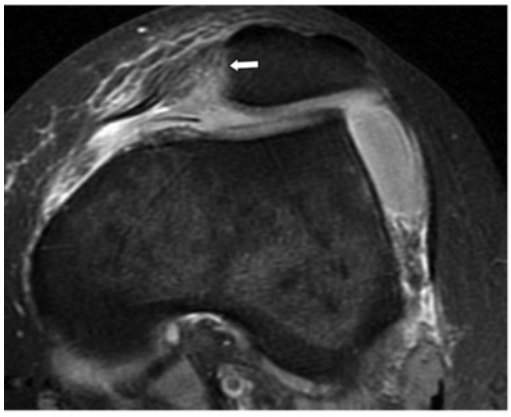

b.

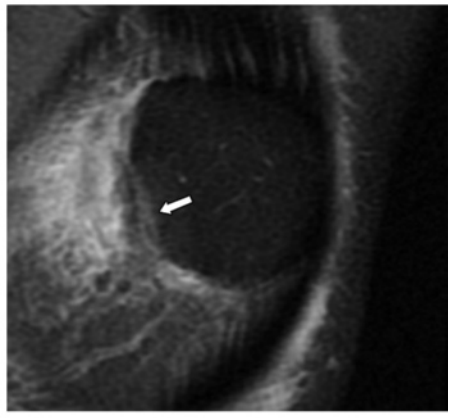

c.

Figure 13. Osteochondral defects of the inferomedial patellar border on T2-weighted fat-saturated MR images. **(a)** Axial image shows a patellar avulsion defect (arrow) with a small bone fragment (arrowhead) in a 39-year-old woman. **(b)** Axial image shows a patellar impaction deformity (arrow) resulting from contusion against the lateral condyle in a 23-year-old woman. **(c)** Coronal image of same patient as in **b** depicts a concave impaction deformity (arrow), which is the severe form of bone impression on the patellar border and is considered a specific sign for prior patellar dislocation.

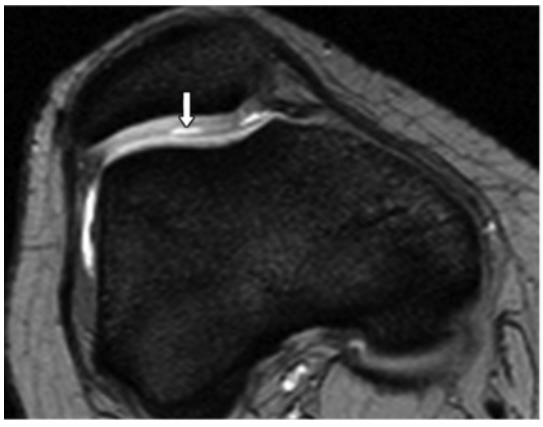

a.

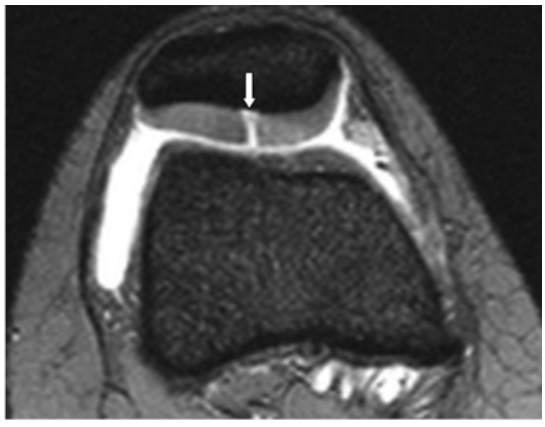

b.

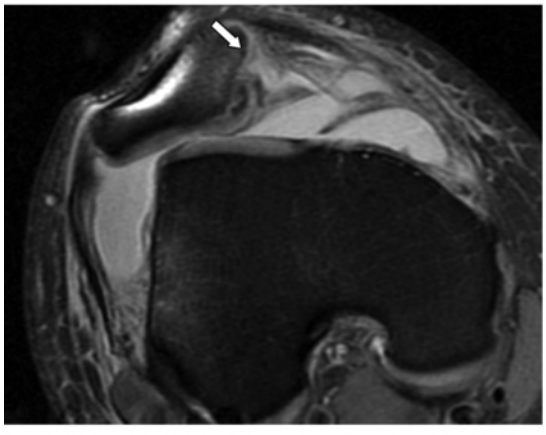

c.

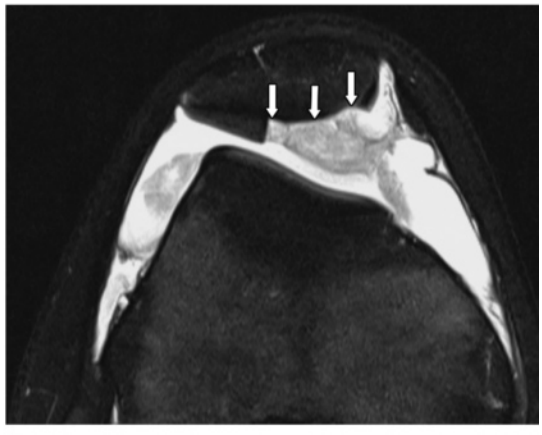

d.

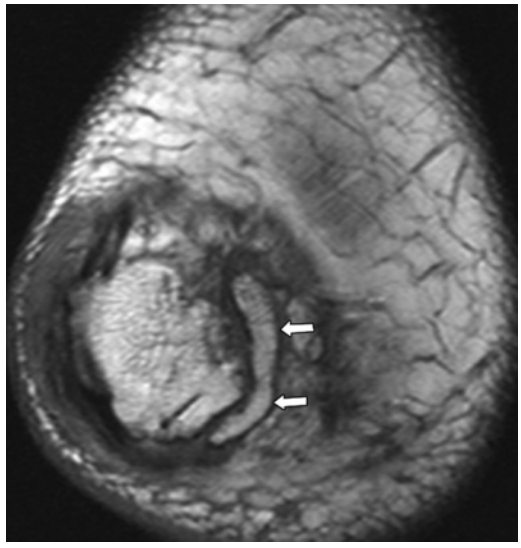

Figure 15. Parapatellar bone formation (arrows) on a coronal T1-weighted MR image obtained after multiple dislocations and chronic instability in a 38-year-old-man. This condition differs from bipartite patella in that the bone formation is typically found at the medial border of the patella. Ossifications are attributed to repetitive stress to the MPFL.

accuracy for circumscribed thinning of patellar cartilage involving less than 50% of the cartilage thickness (grade I or II) is lower. Defects of the trochlear cartilage are rare, and care must be taken not to overlook them because they also require prompt surgery if they are large.

Long-term changes in the patellofemoral joint may occur after chronic instability. With regard to such long-term changes, MR imaging demonstrates signs of early osteoarthritis and ligamentous ossifications of the medial patella in most cases (41) (Fig 15).

Lateral Condylar Defects

In nearly all of the patients (80%–100%), bone edema of the lateral femoral condyle resulting from impaction of the patella will be seen (5–11) (Fig 12). However, edema may resolve by the time that imaging is performed after acute dislocation. In rare cases, the force of impact may lead to condylar fracture. A unicortical fracture line is best seen on coronal T1-weighted images as a serrated horizontal line of low signal intensity surrounded by low-signal-intensity bone edema. Around 40% of the patients present with osteochondral lesions of the anterolateral or midlateral aspect of the condyle (10) (Fig 16). Completely separated bone fragments may be depicted as intraarticular bodies in the joint space, which are an indication for surgery.

Effusion

Knee joint effusion is a typical finding after patellar dislocation and will be seen in most patients, especially when imaging is performed immediately after the event (7,10,42). The amount of effusion decreases with time. The presence of effusion is not specific and may also be associated with other conditions. The amount of hyperintense fluid depicted with T2-weighted sequences can be determined in the sagittal plane to differentiate abnormal effusion from the normal amount of joint fluid present. Joint effusion is defined as a fluid depth of more than 4 mm in the suprapatellar recess on midline sagittal images and more than 10 mm in the lateral recess on lateral sagittal images (43). If hemorrhage is present, fluid-fluid levels will be seen as a result of sedimentation of blood components, which may have intermediate or low T2 signal intensity, depending on the age of the effusion (Fig 17). Effusion is often absent in patients with habitual dislocations. Because such patients have considerable instability, redislocation rarely causes new injury to the lax medial stabilizers.

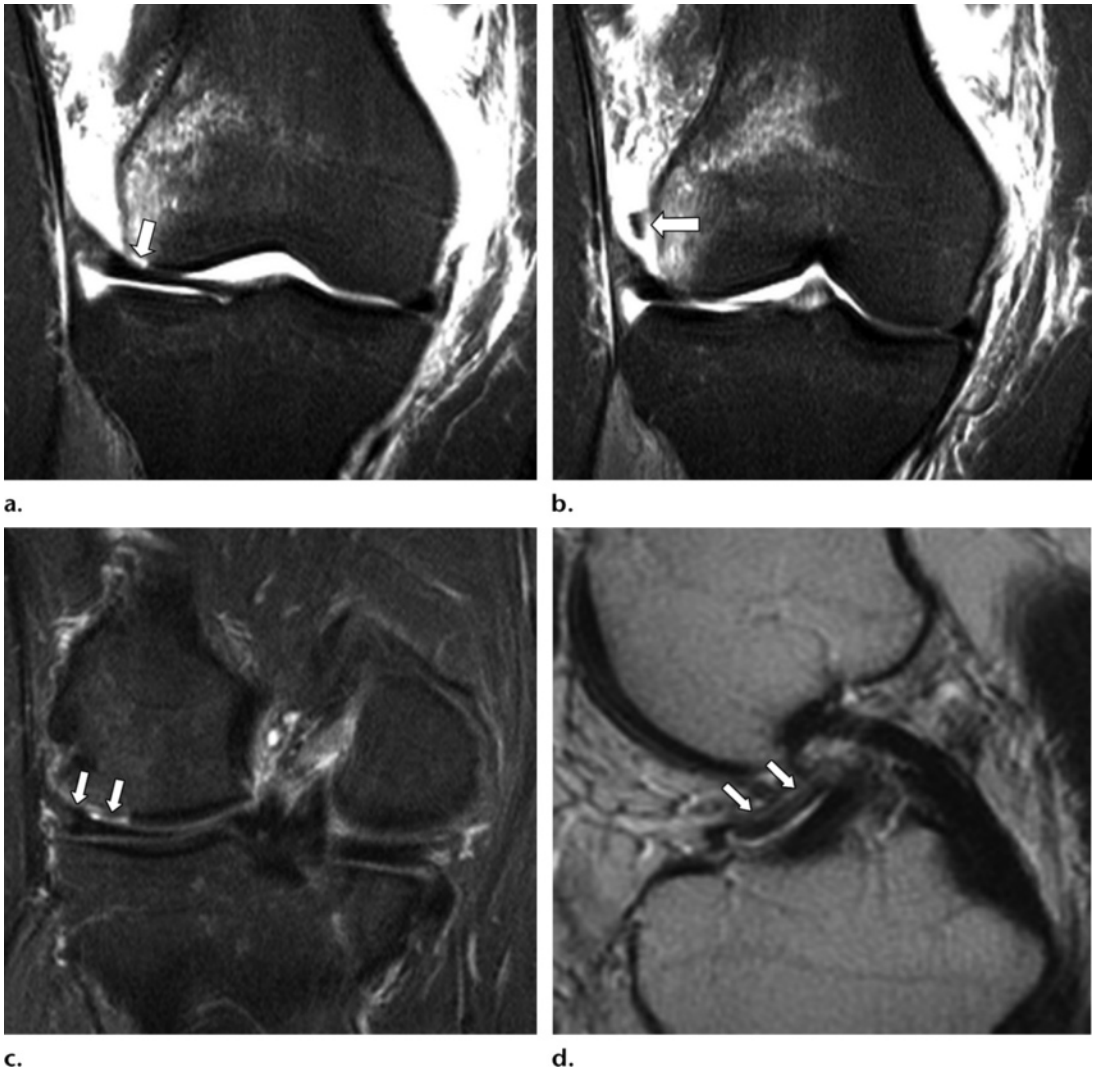

Figure 16. Osteochondral defects of the lateral condyle. **(a, b)** Coronal strongly T2-weighted fat-saturated MR images of a 20-year-old woman show a short osteochondral defect (arrow in **a**) of the lateral edge of the condyle that is filled with fluid from the joint effusion. The loose body (arrow in **b**) is seen directly lateral to the condyle on the subsequent coronal section. **(c, d)** Larger osteochondral defect of the lateral condyle in a 26-year-old woman. **(c)** Coronal strongly T2-weighted fat-saturated MR image demonstrates the defect as a disruption of the subchondral signal void (arrows). **(d)** Sagittal T2-weighted MR image depicts a free body anterior to the anterior cruciate ligament (arrows).

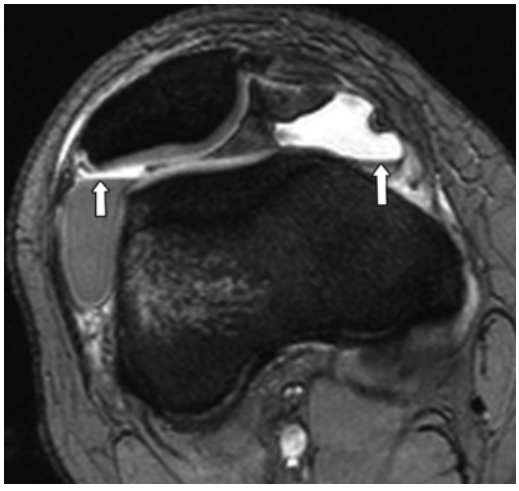

Figure 17. Hemarthrosis after patellar dislocation in a 27-year-old woman. Axial T2-weighted fat-saturated MR image shows a horizontal fluid level (arrows) in the large joint effusion; the fluid level is attributable to sedimentation of blood components.

Other Findings

Patellar dislocation can also cause edema or hemorrhage of the vastus medialis obliquus adjacent to the MPFL, which will be seen on coronal T2-weighted images (10,44) (Fig 18). Moreover, the vastus medialis obliquus may be elevated from its attachment at the adductor tubercle. Disruption of muscle fibers may be interstitial or insertional, and the fibers can be reattached by suturing. Intraarticular bodies are well-defined focal structures of low signal intensity within the joint fluid (Fig 16). Such bodies are present in as many as one-third of the patients after patellar dislocation, and these bodies represent avulsed osteochondral fragments of the patella or of the lateral condyle (5,7). Injury to a meniscus, collateral ligament, or even a cruciate ligament may also occur. Fresh defects are primarily attributable to recent traumatic dislocation. As many as one-fifth of the cases will show rupture of the medial collateral ligament and the medial meniscus (5,6), which may be attributable to the close anatomic relationship of these structures to the femoral attachment of the medial stabilizers.

The clinical symptoms of combined injury to the medial collateral ligament and medial meniscus may be almost the same as the clinical symptoms of patellar dislocation, which may lead to misdiagnosis if imaging is not performed. The radiologist's report should always mention injury to the medial collateral ligament and meniscus or should state that these structures are intact. Damage to the anterior cruciate ligament is also important for surgical planning because repair of this ligament is usually done after 3–6 weeks and is ideally combined with patellofemoral stabilization.

Repair Techniques

A number of surgical options are available to treat patients with patellar dislocation, and proper diagnosis is decisive for selecting the most promising treatment (45,46). Diagnostic evaluation includes identification and characterization of underlying anomalies because the aim of surgery is to correct such anomalies and the damage caused by the event.

Teaching Point

Immediate surgical measures are rarely indicated after patellar dislocation. Timely surgical reattachment or resection is indicated in patients with a loose body after an osteochondral shearing fracture. This finding usually requires an open surgical approach and can therefore be combined with the correction of any underlying anomalies in the same session. Another indication for surgical stabilization is a femoral avulsion injury of the medial stabilizers because nonsurgical treatment alone may not fully restore the patella to its normal position if there is severe damage to these structures. MR imaging findings are therefore important for both therapeutic decision making and planning of the surgical procedure.



Figure 18. Edema (arrows) of the inferior portion of the vastus medialis obliquus on a coronal strongly T2-weighted fat-saturated MR image of a 24-year-old man.

The most common surgical procedures after patellar dislocation involve the medial and lateral stabilizers (MPFL reconstruction, medial capsular plication, and lateral release). Bone procedures include reconstruction of a dysplastic trochlea (trochleoplasty) and tibial tuberosity transfer in patients with an abnormal distance between the tibial tubercle and the trochlear groove. The optimal time of surgery depends on the individual constellation of findings. Most authors recommend nonsurgical management for first-time dislocations because functional outcome and redislocation rates appear to be the same after surgical MPFL stabilization and nonsurgical management (47,48). Nevertheless, surgery may be beneficial after first-time patellar dislocation in individuals with severe dysplasia or marked lateral displace-

Teaching Point

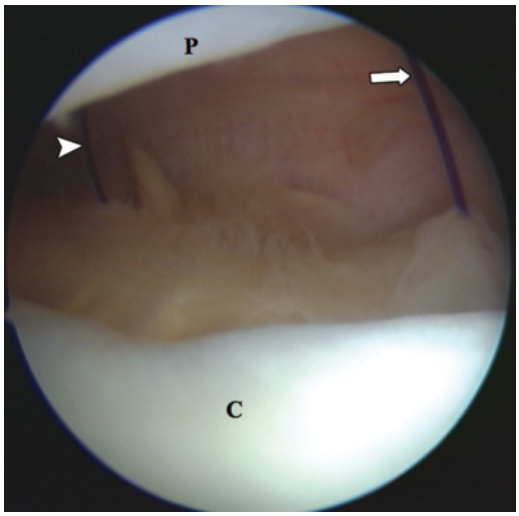

Figure 19. Arthroscopic view of an MPFL suture (medial view through the patellofemoral joint cleft) shows the undersurface of the patella *(P)* and the cartilage of the lateral femoral condyle *(C)*. The inner surface of the joint capsule is intact. Sutures are placed by passing the needle through all three layers from the outside (arrowhead) and then outside again (arrow), where the knots are placed subcutaneously. Accurate identification of the level of ligamentous rupture with preoperative MR imaging is important because the MPFL is part of the intermediate layer and therefore is not visible to the surgeon.

ment of the tibial tuberosity (49). Nonsurgical treatment options include bracing and physical therapy, focusing on strengthening of the medial muscles.

MPFL Reconstruction

The aim of surgical MPFL reconstruction is to restore the restraining function of the medial stabilizers, which can be achieved by replacement of a torn MPFL with an autograft (gracilis tendon) or an allograft (eg, semimembranosus) (46). Different techniques of MPFL repair have been described, but they all aim at stabilizing the attachment of the MPFL to the medial femoral condyle, the lowest point of the MPFL, or its attachment to the medial patellar facet. The approaches use different anchoring techniques and graft materials. The mechanical stability often surpasses that of an intact native MPFL, which is necessary to compensate for additional anomalies contributing to instability and predisposing patients to future patellar subluxations or dislocations.

Medial Capsular Plication

Plication of the medial capsuloligamentous stabilizers is the most common surgery performed after patellar dislocation worldwide. Such plication is now mostly an arthroscopic intervention. Medial capsular plication is accomplished by suturing of the site of rupture with a variable number of stitches (Fig 19). Tears near the femoral attachment usually require open surgery, and arthroscopy achieves good stabilization of tears near the patella. Because the medial stabilizers are extraarticular (layer II), the site of rupture is typically not seen through the arthroscope. It is therefore of paramount importance to determine the exact site of the tear with preoperative MR imaging. Isolated medial capsular plication does not provide adequate stability to prevent future dislocations if additional advanced risk factors such as patella alta or trochlear dysplasia are present (49). Medial capsular plication is increasingly being performed in conjunction with additional surgical procedures.

Lateral Capsular Release

Lateral capsular release is still a widely used standard surgical technique and is the primary surgical intervention for patellar dislocation when combined with medial capsular plication (50). This procedure is accomplished by surgically severing the lateral ligament. However, biomechanical studies have shown that lateral release may contribute to instability of the patellofemoral joint when the knee is in nearly full extension (51). Therefore, lateral release appears to be beneficial only in conjunction with procedures addressing anatomic anomalies in patients with patellar dislocation occurring in deep flexion (which is rare). MR images obtained after lateral release may show extensive scar formation at the site of intervention, which may occasionally cause additional compression and tilting of the lateral patellofemoral joint.

Trochleoplasty

Mild trochlear dysplasia (types A and B according to Dejour et al [20]) does not require surgical correction. However, good clinical outcome and prevention of future patellar dislocations are achieved with surgery in advanced trochlear dysplasia (types C and D) (46,52,53). In a trochleoplasty, an osteochondral strip several millimeters

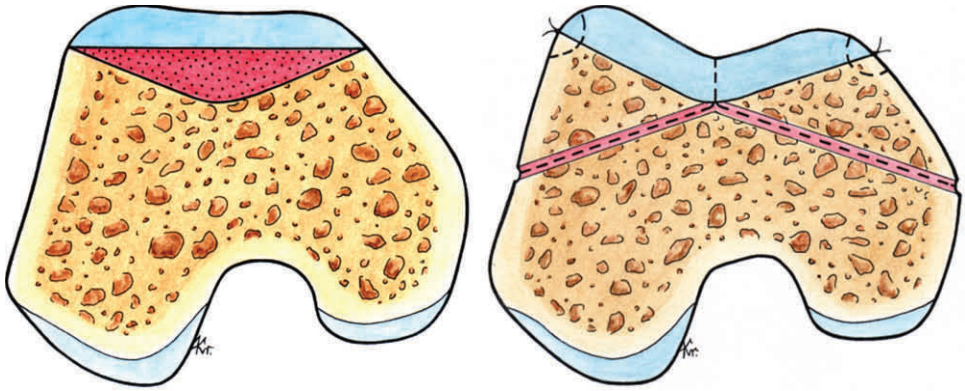

a. b.

Figure 20. Drawings of trochleoplasty (inferior axial views). The aim of trochleoplasty is to deepen the trochlear groove for reliable patellar containment and tracking. **(a)** Drawing shows the initial situation: type B trochlear dysplasia according to the classification of Dejour et al (19,20). To perform trochleoplasty, the trochlear joint area is removed as a first step. Next, a new groove is drilled and shaped in the subchondral bone, corresponding in site to the anatomic sulcus (red area). **(b)** Drawing shows how the removed joint area fragment is modeled into the deepened groove and then fixed. Sutures (dashed lines) are tunneled through the condyles to the deepest point of the sulcus. At the notch, the suture needle is pierced through the cartilage from below and knotted with a second thread from above (not shown). Additional knots are placed at the lateral borders of the trochlear facets.

thick is elevated from the proximal third of the joint area by using a curved osteotomy to create a new trochlear groove at its normal anatomic site (Fig 20). Next, the osteochondral flap is impacted into the newly created groove and fixed in place with sutures or pins. The resulting groove is deeper and steeper, ensuring more secure tracking of the patella. At postoperative imaging, successful trochlear reshaping is reflected by improvement of trochlear depth, lateral inclination, and sulcus angle (54,55). Overall functional outcome is good, and trochleoplasty appears to be highly efficient in preventing redislocation. It remains to be determined to what extent the changes in patellofemoral kinematics after trochleoplasty affect patellofemoral contact pressures and how these changes in turn may affect patellofemoral symptoms and the development of arthrosis.

Tibial Tuberosity Transfer

Different types of surgical medialization of the tibial tuberosity have been described (21,56,57). The aim is to transfer the distal attachment of the patellar tendon, thereby shifting the force vector medially and ensuring proper tracking of the patella during flexion of the knee (Fig 21). Lateralization can be quantified by preoperative measurement of the distance between the tibial tubercle and the trochlear groove, and such measurement is important for determining the desired correction. Tibial tuberosity transfer alone has increasingly been abandoned in recent years because its efficiency in preventing future patellar dislocations depends on the actual amount of patellar tendon lateralization present. Overmedialization can massively increase the contact forces acting on the medial patellofemoral groove, which results in gradual destruction of the groove within a few years. Tibial tuberosity transfer can simultaneously correct a high-riding patella. The procedure has also been combined with anterior transfer of the patellar tendon to minimize contact pressures. This latter procedure is no longer recommended in patients with patellofemoral instability because it can lead to redislocation, a decreased range of motion, and persistent anterior knee pain.

Conclusions

MR imaging is the imaging modality of choice in patients in whom patellar dislocation is suspected. MR imaging allows evaluation of typical

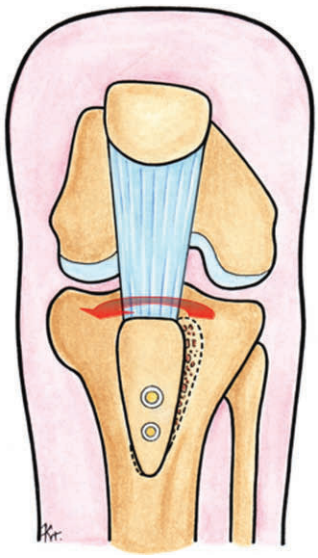

Figure 21. Drawing of tibial tuberosity transfer (frontal view). The aim of this operation is to shift the tibial tuberosity medially so that the force vector is directed centrally during knee flexion. First, the tibial tuberosity is severed from the tibia with a long bone chip. Depending on the preexisting distance between the tibial tubercle and the trochlear groove, the tibial tuberosity, which gives attachment to the patellar tendon, is transferred medially (red arrow), where it is fixed with a cortical bone screw and a cancellous bone screw. In patients with patella alta, the tibial tuberosity can additionally be transferred inferiorly.

injury patterns and can be used to diagnose anatomic variants contributing to the development of patellofemoral instability. Different surgical options are available to stabilize the patellofemoral joint and correct predisposing factors. Imaging findings help physicians in selecting the optimal treatment. A wide variety of measures and techniques are available to evaluate the underlying anatomic structures. To ensure the best diagnostic yield, the radiologist should select the most suitable evaluation parameter in consultation with the referring orthopedic surgeon.

Acknowledgment.—The authors thank the artist, Mrs. Stephanie Kreutzer, Charité Campus Mitte, Universitätsmedizin Berlin, Berlin, Germany, for the drawings.

References

1. Fithian DC, Paxton EW, Stone ML, et al. Epidemiology and natural history of acute patellar dislocation. Am J Sports Med 2004;32(5):1114–1121.
2. Sillanpää P, Mattila VM, Iivonen T, Visuri T, Pihlajamäki H. Incidence and risk factors of acute traumatic primary patellar dislocation. Med Sci Sports Exerc 2008;40(4):606–611.
3. Hawkins RJ, Bell RH, Anisette G. Acute patellar dislocations: the natural history. Am J Sports Med 1986;14(2):117–120.
4. Atkin DM, Fithian DC, Marangi KS, Stone ML, Dobson BE, Mendelsohn C. Characteristics of patients with primary acute lateral patellar dislocation and their recovery within the first 6 months of injury. Am J Sports Med 2000;28(4):472–479.
5. Elias DA, White LM, Fithian DC. Acute lateral patellar dislocation at MR imaging: injury patterns of medial patellar soft-tissue restraints and osteochondral injuries of the inferomedial patella. Radiology 2002;225(3):736–743.
6. Guerrero P, Li X, Patel K, Brown M, Busconi B. Medial patellofemoral ligament injury patterns and associated pathology in lateral patella dislocation: an MRI study. Sports Med Arthrosc Rehabil Ther Technol 2009;1(1):17.
7. Kirsch MD, Fitzgerald SW, Friedman H, Rogers LF. Transient lateral patellar dislocation: diagnosis with MR imaging. AJR Am J Roentgenol 1993;161(1):109–113.
8. Lance E, Deutsch AL, Mink JH. Prior lateral patellar dislocation: MR imaging findings. Radiology 1993;189(3):905–907.
9. Nomura E, Horiuchi Y, Inoue M. Correlation of MR imaging findings and open exploration of medial patellofemoral ligament injuries in acute patellar dislocations. Knee 2002;9(2):139–143.
10. Sanders TG, Paruchuri NB, Zlatkin MB. MRI of osteochondral defects of the lateral femoral condyle: incidence and pattern of injury after transient lateral dislocation of the patella. AJR Am J Roentgenol 2006;187(5):1332–1337.
11. Virolainen H, Visuri T, Kuusela T. Acute dislocation of the patella: MR findings. Radiology 1993;189(1):243–246.
12. Carrillon Y, Abidi H, Dejour D, Fantino O, Moyen B, Tran-Minh VA. Patellar instability: assessment on MR images by measuring the lateral trochlear inclination—initial experience. Radiology 2000;216(2):582–585.

13. Escala JS, Mellado JM, Olona M, Giné J, Saurí A, Neyret P. Objective patellar instability: MR-based quantitative assessment of potentially associated anatomical features. Knee Surg Sports Traumatol Arthrosc 2006;14(3):264–272.
14. Miller TT, Staron RB, Feldman F. Patellar height on sagittal MR imaging of the knee. AJR Am J Roentgenol 1996;167(2):339–341.
15. Pfirrmann CW, Zanetti M, Romero J, Hodler J. Femoral trochlear dysplasia: MR findings. Radiology 2000;216(3):858–864.
16. Toms AP, Cahir J, Swift L, Donell ST. Imaging the femoral sulcus with ultrasound, CT, and MRI: reliability and generalizability in patients with patellar instability. Skeletal Radiol 2009;38(4):329–338.
17. Warren LF, Marshall JL. The supporting structures and layers on the medial side of the knee: an anatomical analysis. J Bone Joint Surg Am 1979;61(1):56–62.
18. Kramer J, White LM, Recht MP. MR imaging of the extensor mechanism. Semin Musculoskelet Radiol 2009;13(4):384–401.
19. Dejour H, Walch G, Nove-Josserand L, Guier C. Factors of patellar instability: an anatomic radiographic study. Knee Surg Sports Traumatol Arthrosc 1994;2(1):19–26.
20. Dejour H, Walch G, Neyret P, Adeleine P. Dysplasia of the femoral trochlea [in French]. Rev Chir Orthop Reparatrice Appar Mot 1990;76(1):45–54.
21. Koëter S, Bongers EM, de Rooij J, van Kampen A. Minimal rotation aberrations cause radiographic misdiagnosis of trochlear dysplasia. Knee Surg Sports Traumatol Arthrosc 2006;14(8):713–717.
22. Salzmann GM, Weber TS, Spang JT, Imhoff AB, Schöttle PB. Comparison of native axial radiographs with axial MR imaging for determination of the trochlear morphology in patients with trochlear dysplasia. Arch Orthop Trauma Surg 2010;130(3):335–340.
23. Neyret P, Robinson AH, Le Coultre B, Lapra C, Chambat P. Patellar tendon length: the factor in patellar instability? Knee 2002;9(1):3–6.
24. Ward SR, Terk MR, Powers CM. Patella alta: association with patellofemoral alignment and changes in contact area during weight-bearing. J Bone Joint Surg Am 2007;89(8):1749–1755.
25. Shabshin N, Schweitzer ME, Morrison WB, Parker L. MRI criteria for patella alta and baja. Skeletal Radiol 2004;33(8):445–450.
26. Seil R, Müller B, Georg T, Kohn D, Rupp S. Reliability and interobserver variability in radiological patellar height ratios. Knee Surg Sports Traumatol Arthrosc 2000;8(4):231–236.
27. Barnett AJ, Prentice M, Mandalia V, Wakeley CJ, Eldridge JD. Patellar height measurement in trochlear dysplasia. Knee Surg Sports Traumatol Arthrosc 2009;17(12):1412–1415.
28. Miller TT, Staron RB, Koenigsberg T, Levin TL, Feldman F. MR imaging of Baker cysts: association with internal derangement, effusion, and degenerative arthropathy. Radiology 1996;201(1):247–250.
29. Biedert RM, Albrecht S. The patellotrochlear index: a new index for assessing patellar height. Knee Surg Sports Traumatol Arthrosc 2006;14(8):707–712.
30. Tsujimoto K, Kurosaka M, Yoshiya S, Mizuno K. Radiographic and computed tomographic analysis of the position of the tibial tubercle in recurrent dislocation and subluxation of the patella. Am J Knee Surg 2000;13(2):83–88.
31. Schoettle PB, Zanetti M, Seifert B, Pfirrmann CW, Fucentese SF, Romero J. The tibial tuberosity-trochlear groove distance: a comparative study between CT and MRI scanning. Knee 2006;13(1):26–31.
32. Sillanpää PJ, Peltola E, Mattila VM, Kiuru M, Visuri T, Pihlajamäki H. Femoral avulsion of the medial patellofemoral ligament after primary traumatic patellar dislocation predicts subsequent instability in men: a mean 7-year nonoperative follow-up study. Am J Sports Med 2009;37(8):1513–1521.
33. Laurin CA, Lévesque HP, Dussault R, Labelle H, Peides JP. The abnormal lateral patellofemoral angle: a diagnostic roentgenographic sign of recurrent patellar subluxation. J Bone Joint Surg Am 1978;60(1):55–60.
34. Dainer RD, Barrack RL, Buckley SL, Alexander AH. Arthroscopic treatment of acute patellar dislocations. Arthroscopy 1988;4(4):267–271.

RadioGraphics

35. Disler DG, McCauley TR, Kelman CG, et al. Fat-suppressed three-dimensional spoiled gradient-echo MR imaging of hyaline cartilage defects in the knee: comparison with standard MR imaging and arthroscopy. AJR Am J Roentgenol 1996;167(1):127–132.
36. McCauley TR, Disler DG. MR imaging of articular cartilage. Radiology 1998;209(3):629–640.
37. Recht MP, Piraino DW, Paletta GA, Schils JP, Belhobek GH. Accuracy of fat-suppressed three-dimensional spoiled gradient-echo FLASH MR imaging in the detection of patellofemoral articular cartilage abnormalities. Radiology 1996;198(1):209–212.
38. Ruehm S, Zanetti M, Romero J, Hodler J. MRI of patellar articular cartilage: evaluation of an optimized gradient echo sequence (3D-DESS). J Magn Reson Imaging 1998;8(6):1246–1251.
39. Disler DG, McCauley TR. Clinical magnetic resonance imaging of articular cartilage. Top Magn Reson Imaging 1998;9(6):360–376.
40. Schmid MR, Pfirrmann CW, Koch P, Zanetti M, Kuehn B, Hodler J. Imaging of patellar cartilage with a 2D multiple-echo data image combination sequence. AJR Am J Roentgenol 2005;184(6):1744–1748.
41. Jerabek SA, Asnis PD, Bredella MA, Ouellette HA, Poon SK, Gill TJ 4th. Medial patellar ossification after patellar instability: a radiographic finding indicative of prior patella subluxation/dislocation. Skeletal Radiol 2009;38(8):785–790.
42. Spritzer CE, Courneya DL, Burk DL Jr, Garrett WE, Strong JA. Medial retinacular complex injury in acute patellar dislocation: MR findings and surgical implications. AJR Am J Roentgenol 1997;168(1):117–122.
43. Schweitzer ME, Falk A, Berthoty D, Mitchell M, Resnick D. Knee effusion: normal distribution of fluid. AJR Am J Roentgenol 1992;159(2):361–363.
44. Sallay PI, Poggi J, Speer KP, Garrett WE. Acute dislocation of the patella: a correlative pathoanatomic study. Am J Sports Med 1996;24(1):52–60.
45. Arendt EA, Fithian DC, Cohen E. Current concepts of lateral patella dislocation. Clin Sports Med 2002;21(3):499–519.
46. Colvin AC, West RV. Patellar instability. J Bone Joint Surg Am 2008;90(12):2751–2762.
47. Christiansen SE, Jakobsen BW, Lund B, Lind M. Isolated repair of the medial patellofemoral ligament in primary dislocation of the patella: a prospective randomized study. Arthroscopy 2008;24(8):881–887.
48. Sillanpää PJ, Mäenpää HM, Mattila VM, Visuri T, Pihlajamäki H. Arthroscopic surgery for primary traumatic patellar dislocation: a prospective, nonrandomized study comparing patients treated with and without acute arthroscopic stabilization with a median 7-year follow-up. Am J Sports Med 2008;36(12):2301–2309.
49. Schöttle PB, Scheffler SU, Schwarck A, Weiler A. Arthroscopic medial retinacular repair after patellar dislocation with and without underlying trochlear dysplasia: a preliminary report. Arthroscopy 2006;22(11):1192–1198.
50. Haspl M, Cicak N, Klobucar H, Pecina M. Fully arthroscopic stabilization of the patella. Arthroscopy 2002;18(1):E2.
51. Christoforakis J, Bull AM, Strachan RK, Shymkiw R, Senavongse W, Amis AA. Effects of lateral retinacular release on the lateral stability of the patella. Knee Surg Sports Traumatol Arthrosc 2006;14(3):273–277.
52. Utting MR, Mulford JS, Eldridge JD. A prospective evaluation of trochleoplasty for the treatment of patellofemoral dislocation and instability. J Bone Joint Surg Br 2008;90(2):180–185.
53. von Knoch F, Böhm T, Bürgi ML, von Knoch M, Bereiter H. Trochleaplasty for recurrent patellar dislocation in association with trochlear dysplasia: a 4- to 14-year follow-up study. J Bone Joint Surg Br 2006;88(10):1331–1335.
54. Fucentese SF, Schöttle PB, Pfirrmann CW, Romero J. CT changes after trochleoplasty for symptomatic trochlear dysplasia. Knee Surg Sports Traumatol Arthrosc 2007;15(2):168–174.
55. Schöttle PB, Fucentese SF, Pfirrmann C, Bereiter H, Romero J. Trochleaplasty for patellar instability due to trochlear dysplasia: a minimum 2-year clinical and radiological follow-up of 19 knees. Acta Orthop 2005;76(5):693–698.
56. Barber FA, McGarry JE. Elmslie-Trillat procedure for the treatment of recurrent patellar instability. Arthroscopy 2008;24(1):77–81.
57. Servien E, Verdonk PC, Neyret P. Tibial tuberosity transfer for episodic patellar dislocation. Sports Med Arthrosc 2007;15(2):61–67.

MR Imaging of Patellar Instability: Injury Patterns and Assessment of Risk Factors

Gerd Diederichs, MD • Ahi S. Issever, MD • Sven Scheffler, MD

RadioGraphics 2010; 30:961–981 • **Published online** 10.1148/rg.304095755 • **Content Codes:** MK MR

Page 962
The most important factors predisposing to patellar instability include trochlear dysplasia, patella alta (high position of the patella), and excessive lateral distance between the tibial tubercle and the trochlear groove (lateralization of the tibial tuberosity). Characterization and quantification of these anatomic anomalies will reveal the individual mechanism of patellar instability and help the orthopedic surgeon choose the optimal treatment.

Page 963
The most common mechanism of first-time patellar dislocation is a flexed position of the knee with internal rotation on a planted foot with a valgus component (18).

Page 969
MR imaging can be used to diagnose prior patellar dislocation on the basis of typical injury patterns. In general, deformity or edema of the inferomedial patella and the lateral condyle, in conjunction with MPFL disruption and patellar lateralization, is diagnostic for recent patellar dislocation (5–11,18).

Page 976
Diagnostic evaluation includes identification and characterization of underlying anomalies because the aim of surgery is to correct such anomalies and the damage caused by the event.

Page 976
The most common surgical procedures after patellar dislocation involve the medial and lateral stabilizers (MPFL reconstruction, medial capsular plication, and lateral release). Bone procedures include reconstruction of a dysplastic trochlea (trochleoplasty) and tibial tuberosity transfer in patients with an abnormal distance between the tibial tubercle and the trochlear groove. The optimal time of surgery depends on the individual constellation of findings.