PROSCAN MRI ONLINE

IMAGING GUIDE

Soft-Tissue Masses

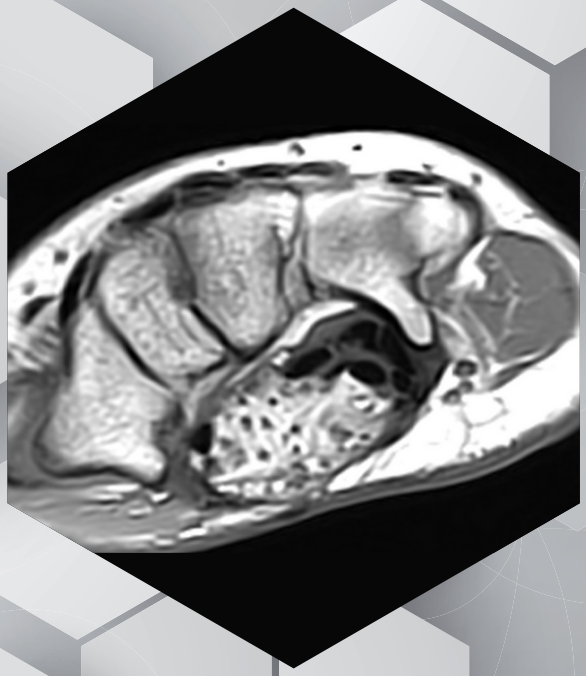

CONTENTS

Introduction 4
Definition: 4
Classifications: 4
Approach to Soft Tissue Masses on MRI 7
Signs: 8

Anatomy and Conditions 10
Predilections of anatomy 10
Summary of Position / Space 11
Typical Low and High Grade Soft Tissue Tumors 12
Vascular Lesions 12
Benign Fibrohistiocytic Lesions 13
Sarcoma on MR: Summary and Differential Diagnosis 14
Intermediate Malignancy Fibrohistiocytic Lesions 15
Malignant Fibrohistiocytic Lesions 15
"Malignant Fibrous Histiocytoma" Myxofibrosarcoma 16
Lipomatosis of Nerve 16
Other Benign Fatty Masses 17
Liposarcoma 21
Liposarcoma (Well-differentiated) 22
Liposarcoma (Myxoid) 22
Liposarcoma (Round Cell and Pleomorphic) 22
Liposarcoma (Dedifferentiated) 23
Tumors of Connective Tissue 23
Tumors of Connective Tissue (Rules) 23
Benign Fibrous Masses 24
Specific Signals: Very Low T2 Collagenous Solitary Fibroma 24
T2 Hypointensity: Collagenous Fibroma and Family of Fibrotic Lesions 24
Fibromatoses (nonaggressive variants) 25
Perineural Fibroma - Morton's "Neuroma" 25
Sign: Elastofibroma Dorsi "Snowstorm" 25
Fibrous Masses 26
Extra-Abdominal Desmoids 26
Extra-Abdominal Desmoids Appearance 26
Extra-Abdominal Desmoids Differential Superficial Masses 26
Abdominal Desmoids 27
Nodular Fasciitis 27
Fibroma of Tendon Sheath 27
Nuchal Fibroma 27
Collagenous Fibroma 28
Intermediate Grade Fibromyoblastic Tumors 28
Malignant Fibromyoblastic Tumors 29
Fibrous Tumors of Infancy 29
Infantile Fibromatosis / Fibrosarcoma 30
Neural Tumors 30

Vascular Lesions 31
Vascular Lesions (Angiomatosis) 31
Vascular Lesions (Mulliken Classification of Cutaneous Vascular Lesions) 31
Vascular Lesions (Vascular Simple Combined Classification) 31
Vascular Masses 32
Vascular Tumors of Intermediate Malignancies 34
Vascular Tumors of High Malignancies 35
Tumors of Muscle Origin 36
Masses of Tendon Origin 36
Angiomatous Syndromes 37
Hemangioendothelioma 38
Angiosarcoma 38
Squamous Cell Carcinoma 38
Musculoskeletal Masses on MR: Compartment Syndromes; Inflammations and Infections 39
Pearls of Foot / Ankle: Soft Tissue Masses 41
Malignancy in the Foot 42
Most Common Malignant Soft Tissue Tumors of the Foot and Ankle 42

Soft Tissue Appendix 43
Soft Tissue Masses By Signal 43
Musculoskeletal Masses on MR 44
More About Signal: 45

References 48

INTRODUCTION

Definition:

Mesenchyme, a tissue that has the potential to differentiate into various soft-tissues (e.g. fat, skeletal muscle, peripheral nerves, blood vessels, and fibrous tissue), can be comprised of tumors that are histologically classified as benign, intermediate, or malignant. [7]

Classifications:

Abbreviated WHO Classification of Soft-Tissue Tumors [7]

Adipocytic	
Benign	• Lipoma • Lipomatosis • Lipomatosis of nerve • Lipoblastoma • Lipoblastomatosis • Hibernoma
Intermediate (locally aggressive)	• Atypical lipoma • Well-differentiated liposarcoma
Malignant	• Liposarcoma • Dedifferentiated • Myxoid • Round cell • Pleomorphic • Mixed type • Not otherwise specified

Fibroblastic / Myofibroblastic	
Benign	• Nodular fasciitis • Myositis ossificans • Elastofibroma • Fibromatosis coli • Fibroma of tendon sheath • Gardner fibroma
Intermediate (locally aggressive)	• Superficial fibromatosis • Desmoid-type fibromatosis • Lipofibromatosis
Intermediate (rarely metastasizing)	• Solitary fibrous tumor and hemangiopericytoma • Infantile fibrosarcoma
Malignant	• Adult fibrosarcoma • Myxofibrosarcoma

So-Called Fibrohistiocytic	
Benign	• Giant cell tumor of tendon sheath • Diffuse-type giant cell • Benign fibrous histiocytoma
Intermediate (rarely metastasizing)	• Giant cell tumor of soft tissues
Malignant	• Pleomorphic fibrous histiocytoma or undifferentiated pleomorphic sarcoma • Giant cell fibrous histiocytoma or undifferentiated pleomorphic sarcoma with giant cells • Inflammatory fibrous histiocytoma or undifferentiated pleomorphic sarcoma with prominent inflammation

Smooth Muscle	
Benign	• Angioleiomyoma • Leiomyoma of deep soft tissue
Malignant	• Leiomyosarcoma

Pericytic (perivascular)	
	• Glomus tumor • Myopericytoma

Skeletal Muscle	
Benign	• Rhabdomyoma
Malignant	• Rhabdomyosarcoma: - Embryonal - Alveolar - Pleomorphic

Vascular	
Benign	• Hemangioma • Epithelioid hemangioma • Angiomatosis • Lymphangioma
Intermediate (locally aggressive)	• Kaposiform hemangioendothelioma
Intermediate (rarely metastasizing)	• Retiform hemangioendothelioma • Kaposi sarcoma
Malignant	• Epithelioid hemangioendothelioma • Angiosarcoma of soft tissue

Chondro-Osseous	
	• Soft-tissue chondroma • Mesenchymal chondrosarcoma • Extraskeletal osteosarcoma

Uncertain Differentiation	
Benign	• Intramuscular myxoma • Juxta Articular myxoma • Ectopic hamartomatous thymoma
Intermediate (rarely metastasizing)	• Angiomatoid fibrous histiocytoma • Ossifying fibromyxoid tumor
Malignant	• Synovial sarcoma • Epithelioid sarcoma • Clear cell sarcoma of soft tissue • Extraskeletal myxoid chondrosarcoma • Extraskeletal Ewing tumor • Intimal sarcoma

Approach to Soft Tissue Masses on MRI

- **Patient age**
- **Patient gender**
- **Past medical history**
- **Body part: Thigh, neck, finger, etc.**
- **Compartment: Dermis, subcutis, fascia, muscular, galeal, intermuscular, etc.**
- **Position: Central (e.g. abdomen, head, neck, retroperitoneum) vs extremity or peripheral**
- **T2 relaxivity**
- **T1 relaxivity**
- **T2* blooming (e.g. siderosis)**
- **Homo vs Heterogenity**
- **“Signs” (e.g. tail, tetherball, etc.)**
- **Size**
- **Shape: Round, flat, irregular, serpiginous**
- **Zone of transition: narrow vs wide**
- **Edema: Present or absent**
- **Mass vs. Non-mass-like**

Signs:

- **“Shoulder pad sign”**
- **Ball on a string - “Tethered ball sign”, “Tail sign”**
  - Aneurysm
  - Neural tumor
  - Ganglion
  - Capsular cyst
  - Varix
- **Brain sign**
  - Myeloma
- **Speckled sign**
  - Schwannoma
  - Glomus
  - Hemangioma / Vascular
- **Rice bodies**
  - Synovial hyperplasia
- **Jewelry sign**
  - Synovial chondromatosis
- **Dark boulders**
  - Pigmented villonodular synovitis (PVNS)
- **Ring sign**
  - Osteoid osteoma
  - Melanoma
  - Abscess
  - Hematoma
  - Some tendon injuries (e.g. rectus femoris tear)
- **Concentric rings**
  - Aneurysm
  - Pseudoaneurysm
- **Hollow vertebra sign**
  - Myeloma
- **High / Low sign**
  - Chondromyxoid fibroma (CMF)
- **Concentric rings sign - “Ring in a ring”**
  - Aneurysm
  - Pseudoaneurysm

- **Shoulder pad sign - amyloid**
- **Spaghetti or cable sign - lipofibroneuroma median nerve**
- **Parallel wavy lines - desmoid**
- **Linear: Tendon, nerve, air / gas, vessel**
- **Periskeletal growth: Malignant fibrous histiocytoma (MFH)**
    - May present as pathologic fracture

ANATOMY AND CONDITIONS

Predilections of anatomy

- **Finger**
  - Glomus
  - Epidermoid
  - Infection (GCTS)
- **Knee**
  - PVNS
  - Synovial sarcoma
  - Cysts
  - Pseudocysts
- **Forearm**
  - Epithelioid sarcoma
  - Pseudotumor
- **Foot**
  - Fibromatosis, Foreign body, Callus
  - And certain malignancies (e.g. synovial sarcoma, fibrosarcoma, extraosseous, myxoid fibrosarcoma)
- **Toe**
  - Epidermoid
  - Morton's callus, Adventitial cyst, Osteomyelitis
- **Arm**
  - Varix, Nodes-Cat cratch
  - Mononucleosis
- **Scapula**
  - Elastofibroma dorsi
- **Elbow**
  - Hemophilic pseudotumor
  - Gout
- **Hip**
  - Paralabral and Bursal cysts
  - Dissection from abdomen pathology
- **Thigh**
  - MFH, Myxoid liposarcoma

- **Metacarpal**
  - Enchondroma, cyst
- **Carotid space**
  - Chemodectoma
  - Glomus
  - Schwannoma
- **Hand / Wrist**
  - Ganglia
  - Aneurysm pseudoaneurysm
  - Capsular cysts
  - Dupuytren's
- **Spine**
  - Nerve sheath, Root sheath, Mets VS Osteoblastoma, ABC, OO
- **Presacral**
  - Meningocele
  - Pheochromocytoma

Summary of Position / Space

- **Subcutaneous**
  - Lipoma
  - Sebaceous cyst
  - Epidermoid
    - Foreign body reaction
- **Muscle**
  - Myxoma
  - Sarcoma
  - Myoma
- **Fascial**
  - Desmoid
  - Fibromatosis
  - Epithelioid sarcoma
- **Peri-skeletal, Periarticular**
  - MFH
  - Synovial sarcoma
  - GCTS
- **Nerve**
  - Neural tumor

- **Peritendinous**
  - Ganglion
  - Epithelioid sarcoma
  - Fibrosarcoma
  - Fibroma of tendon sheath
    - Granular cell tumors (GCTs)

Typical Low and High Grade Soft Tissue Tumors [3]

- **Low grade (LG)**
  - Myxoid liposarcoma
  - Lipoma-like liposarcoma
  - Angiomatoid malignant fibrous histiocytoma
  - Synovial sarcoma
- **High grade (HG)**
  - Malignant fibrous histiocytoma
  - Pleomorphic liposarcoma (round cell)
  - Rhabdomyosarcoma
  - Alveolar cell sarcoma
  - Undifferentiated

Vascular Lesions

- **Arteriovenous malformation (AVM)**
  - Flow void
  - Infiltrative
  - T2 even echo rephasing
  - Slice entry
  - Steal
  - Phase mismapping
  - Serpiginous “wormian”
- **Hemangioma**
  - Gray signal T1, Superficial
  - May have fat
  - Phleboliths
- **Glomus**
  - Flow voids / Speckled
- **Varix**
  - Slow or no flow attached to vein

Benign Fibrohistiocytic Lesions

- **Giant cell tumor of tendon sheath or pigmented villonodular synovitis**
  - Hip
  - Knee
  - Elbow
  - Finger
- **Xanthoma**
  - Achilles
  - Less pain - Familial Type 2 and 3
  - DM, PBC, Nephrotic, Hypothyroidism
  - Cutaneous = Neoplasia / Malignancy
- **Juvenile xanthogranuloma**
  - < 2 Years
  - Nonhistiocytosis X
  - Have dendritic cell origin in skin
- **Reticulohistiocytoma**
  - Rare pseudotumor of middle-aged women
  - Females 2:1
  - Localized
  - Cutaneous and diffuse
    - Multicentric reticulohistiocytosis
    - Lipoid dermato arthritis
    - Giant cell reticulohistiocytosis
    - Giant cell histiocytosis - More aggressive
- **Benign fibrous histiocytoma**
  - One of most common benign tumors of skin in young adults
  - Flat
  - Multiple 30%
  - Deep
    - Lower Limb
    - Head / Neck
    - Abdomen
  - Aneurysmal angiomatoid variant
  - Atypical “plaque-like” polypoid variant
  - Invades 30%

Sarcoma on MR: Summary and Differential Diagnosis [5]

- **Rule of thumb for lesions in the soft tissues**
  - If it's not pure blood, pure water or pure fat, the lesion should be followed in 2-4 weeks or biopsied
- **Chondrosarcoma (particularly cystic / clear cell)**
  - May be cystic and demonstrate hyperintense signal on T2, frequently accompanied by hyperintense edema on T2 (matrix is hyperintense but calcium is hypointense); arcs; whorls
- **Fibrosarcoma**
  - A mixed, bland or gray signal on T1 and T2, sometimes completely hypointense simulating pigmented villonodular synovitis, has a propensity for the foot: not siderotic
- **Osteosarcoma**
  - Matrix hyperintense, large mass - periosteal, classic, periosteal, telangiectatic (expansile); ivory or cloudy matrix
- **Lymphosarcoma**
  - Flat bone or diaphyseal, sclerotic, gray homogeneous signal on T1 and T2, does not bleed, older patients, not as destructive
- **Ewing's sarcoma**
  - Flat bone or diaphyseal, young, large soft tissue mass, hemorrhagic, "bowl of fruit," heterogeneous T1 and T2 signal
- **Epithelioid sarcoma**
  - Propensity for upper extremities, grows in a peritendinous locale, demonstrates mixed gray signal ± hemorrhage
- **Malignant fibrous histiocytoma, synovial sarcoma**
  - Demonstrates inhomogeneous bright signal on T2, may resemble the bowl of fruit sign, thigh, large muscle groups, may erode bone, most common soft tissue sarcoma
- **Myxoid liposarcoma**
  - Hyperintense T1 and T2 or very hypointense T1, very hyperintense T2, thigh, large muscle groups (a large myxoid component may mimic a seroma), often smooth borders, second most common soft tissue sarcoma
- **Leiomyosarcoma**
  - Mixed cystic ± hemorrhage, uterus, abdomen
- **Soft part sarcoma**
- **Mixed T1 and T2 signal, thigh, retroperitoneum**
- **Synovial sarcoma**
  - Thigh, storiform, not usually intra- articular, arises from muscle

Intermediate Malignancy Fibrohistiocytic Lesions

- **Dermatofibroma protuberans:**
  - Trunk, Head, Neck extremities
  - 10-50 y.o.
  - Red plaque-like
  - Slight male preponderance
  - Recurs 50%
  - No Ca+
  - Heterogeneous hemorrhage or necrosis
- **Bednar tumor**
  - As above but with melanin
  - (5%) of dermatofibromas
- **Plexiform fibrohistiocytic tumor**
  - Rare and may be related to XRT
- **Giant cell fibroblastoma**
  - Thigh, groin and chest wall of infants and kids
- **Angiomatoid fibrous histiocytoma (used to be angiomatoid malignant fibrous histiocytoma)**
- **Giant cell tumor of soft tissues (Not the same as GCTs which like digits; thumb)**
  - Lower or upper limb
  - Head neck
  - Trunk
  - Superficial
  - Used to be giant cell MFH (now use this term for aggressive histology)
  - Prognosis varies

Malignant Fibrohistiocytic Lesions

- **Atypical fibroxanthoma**
- **Malignant fibrous histiocytoma (see Myxofibrosarcoma)**

"Malignant Fibrous Histiocytoma" Myxofibrosarcoma

- **Cortical erosion common; Uncommon for other sarcomas**
- **Fluid-like components, but no fat = MFH (blood may simulate fat)**
- **Less likely considerations:**
  - Synovial sarcoma (knee, thigh - "granular internal architecture")
  - Leiomyosarcoma
  - Soft-tissue Ewing's (bleeds creating "bowl of fruit" appearance)
  - Myxoid tumors (Myxoid liposarcoma) - Very bright on T2
  - Previous histologic subtypes
- **Storiform**
  - Pleomorphic - Bleeds, "bowl of fruit"
- **Myxoid**
  - Myxofibrosarcoma - Hyperintense T2
- **Giant cell**
  - Malignant giant cell tumor of soft parts
- **Angiomatoid**

Lipomatosis of Nerve

- **Neural fibrolipoma; Fibrolipomatous hamartoma; Lipofibroma - one and the same**
- **Children and young adults**
- **M > F**
- **Upper >>> Lower extremities (esp. Median Nerve)**
- **Macrodactyly or Macrodystrophia lipomatosa occasionally**
- **"Cable or Spaghetti sign"**
- **Signal**
  - Fibrous
  - Neural
  - Fatty but not vascular
- **Must differentiate from nerve sheath lipoma**

Other Benign Fatty Masses

- **Lipoma**
  - Intramuscular (also called atypical lipoma); Intermuscular; Subcutaneous
  - Most common mesenchymal tumor
  - 50-70 years-old
  - More common in obese
  - Subcutaneous:
    - Upper back
    - Neck
    - Shoulder
    - Abdomen
  - Deep:
    - Chest wall
    - Subfascial hands and feet
  - Deep:
    - Larger and less well circumscribed
  - Look for linear streaks [5]
    - Septa or bands of muscle
  - Benign provided no foci of hyperintensity inside lesion on STIR fat suppression sequence, chemical saturation fat suppression sequence or heavily T2 weighted image. No edema.
  - Most common soft tissue mass
  - Intraosseous lipomas rare, 5-15% can calcify and occasionally fracture (esp. calcaneus)
  - 10% are within calcaneus
  - Narrow zone of transition, can have hypointense pseudocapsule, no perilesional edema unless fractured
  - May have scant or delicate internal architecture, however, increasing intralesional signal raises possibility of lipoma with atypia (spindle cell lipoma), hibernoma, or even liposarcoma
  - Hyperintense signal foci when fat saturation techniques used also worrisome
  - Pearl: Fatty proliferation, especially in upper trunk seen in Dercum's disease (painful), and Madelung's disease (liver insufficiency)

- **Lipoblastoma**
  - Under age 3
  - Extremities
  - Contains septations, lipocytes and lipoblasts with poorly differentiated mesenchymal cells in a myxoid stroma
  - Extends across anatomic spaces (Lipoblastomatosis) - More deeply located
  - Lipoblastoma 2X as common as lipoblastomatosis
  - 80% below age 3
  - 55% below age 1
  - Boys > Girls
  - Extremities most common
  - 60% less than 5 cm
  - Can mature into more well-differentiated lesions
  - Higher T1 and T2 signal than standard lipoma
  - Scant enhancement
  - Pearl: “Liposarcoma is very rare before age 10”
- **Hibernoma**
  - Brown fat
  - Neck
  - Axilla
  - Described by Merkel in 1906
  - Brown fat seen in neonate and plays role in thermogenesis
  - Lobular pattern
  - Septa
  - Vascularized
  - Mixed type of fat and brown fat most common
  - Median age 26 and mean age 32
  - Interscapular
  - Mediastinum
  - Upper thorax most common but anywhere
  - Painless, slow growing but may accelerate
  - Occasionally painful and overlying skin is warm due to hypervascularity
  - Average 5-10 cm
  - Heterogeneous variable enhancement
  - Slightly hypointensity T1 to fat
  - Variable T2
  - Incomplete fat suppression
  - Excision due to similarity to liposarcoma often occurs
  - May be bright on PET

- **Spindle Cell / Pleomorphic**
  - Triad
    - Thymoma
    - Myasthenia gravis
    - Pure red cell aplasia
  - Spindle
    - Collagen forming spindle cells
  - Pleomorphic
    - Pleomorphism and bizarre giant cells
  - Associated
    - Thymoma
    - Myasthenia gravis
    - Pure red cell aplasia
  - Subcutis and neck over age 45 years (older than hibernoma)
  - Relaxation prolongation
- **The others: Fibrolipoma, Lipohemangioma, Hemangioma**
- **Ossifying lipoma (Osteolipoma)**
- **Myxolipoma**
- **Chondroid lipoma**
- **Myelolipoma**
- **Angiolipoma**
- **Heterotopic lipoma**
- **Inter- and Intramuscular lipoma**
  - Intramuscular called "Infiltrative lipoma" and "Atypical lipoma"
  - Usually large muscles of trunk; thigh; arm; shoulder
  - Males > Females
  - Scant or NO enhancement favors benignity VS first pass DCE MRI 3:1 Ratio increase supports malignancy
  - Unilobularity favors benignity
  - Unlike muscle atrophy, muscle is enlarged with intramuscular lipoma
- **Lipoma of tendon sheath / Joint**
- **Lipoma arborescens (Intra-articular subtype of synovial metaplasia)**
  - Synovial metaplasia
  - Intra-articular fat globules
  - Effusion
  - Etiology
    - Underlying irritation of joint
    - Diabetes
    - Rheumatoid
    - Joint trauma

  - Other metaplasias
    - Non-pigmented villonodular synovitis
    - Pigmented villonodular synovitis (diffuse or multifocal)
    - Localized intra-articular giant cell tumor of tendon sheath = Localized PVNS
    - Synovial chondromatosis (Osteochondromatosis)
    - Hemangiomatosis
    - Lipomatosis of nerve
- **Parosteal lipoma**
  - Age
    - 40-60 Years Old
  - Arm, forearm, thigh, calf
  - Large areas of ossification may show marrow signal
  - Slow growing
  - Periosteal lipomas rare
- **Diffuse lipomatosis**
  - Infiltrates muscles and tissues
  - Limbs common (esp. large muscles)
  - Associated osseous hypertrophy with some cases of diffuse lipomatosis is a macrodactyly, but unlike macrodystrophia lipomatosa and neural lipomatosis, no neural involvement
  - Usually age two or less
  - Rare association of face involvement with cytomegalovirus (CMV)
- **Multiple symmetrical lipomatosis**
  - Madelung disease or Launois-Bensaude syndrome
  - Associated with:
    - Liver disease
    - Alcoholism
    - Diabetes
    - Hyperlipidemia
    - Hyperuricemia
    - Malignant upper airway tumors
    - Neuropathy
  - Underlying mitochondrial genetic disorder
  - Painless, progressive
  - Trapezius, sternocleidomastoid, supraclavicular, paraspinous
  - Subcutaneous tissue may be atrophic
  - Preferential locales differentiates from obesity
  - Deep upper airway may compress / Produce hoarseness or caval syndrome

- **Adiposis dolorosa (Dercum disease)**
  - Nodular, painful, multiple subcutaneous lesions
  - Post-menopausal women
  - Pelvic girdle and thigh
  - Asthenia, depression, psychomotor disturbance
  - Autosomal dominant with variable penetrance
- **Shoulder girdle lipomatosis**
  - Described by Enzi
  - Adult females
  - May be asymmetric
  - +/- Airway compression
  - "Bannayan-Zonana syndrome
    - Males
    - Autosomal dominant
    - Macrocephaly
    - Hemangiomas
    - SQ Visceral lipomas

Liposarcoma

- **50% have no radiologically detectable fat**
- **M > F 57%**
- **50-60 y.o.**
- **Usually deep and rare in subcutis**
- **Well-differentiated liposarcoma may dedifferentiate or recur but does not metastasize**
- **Retroperitoneal liposarcoma most likely to metastasize**
- **35% of round cell and myxoid liposarcomas metastasize some 5-10 years later**
- **Poor prognosis**
  - Age > 45
  - > 25% round cell histology
  - Necrosis
- **Calcification only in well-differentiated**
- **Fifth to seventh decades 5**
- **Deceptively well circumscribed, multilobulated, but more inhomogeneous and lower signal on T1 than lipomas**
- **Hemorrhage, necrosis and cyst formation common**
- **Commonly show contrast enhancement**

- **Variants**
  - Well differentiated
  - Round cell
  - Myxoid
  - Pleomorphic

Liposarcoma (Well-differentiated)

- **Enhancing thick septa or nodules > 2 mm**
- **Fat-like**
- **Lower extremities; retroperitoneum; trunk (size and proximity to the center of the body increases risk)**
- **Three subtypes**
  - Lipoma-like
  - Inflammatory
  - Sclerosing

Liposarcoma (Myxoid)

- **2nd most common type = 20.5%**
- **Thigh or lower extremities**
- **> 70-90% ground substance**
- **Mean age 42**
- **In 10%, another (or second) myxoid liposarcoma occurs in retroperitoneum in two years**
- **Commonly involves thigh or popliteal regions 5**
- **Slightly hyperintense relative to muscle, with hypointense pseudocapsule common**
- **Relatively narrow zone of transition with mild peritumoral edema**
- **Fat suppression techniques helpful in evaluating architecture**
- **Intermediate prognosis**

Liposarcoma (Round Cell and Pleomorphic)

- **Many are myxoid with pleomorphic or round cell features by percent**
- **Often no fat seen on MRI**
- **Hypervascular**
- **Both look alike, so it's a histologic diagnosis**

Liposarcoma (Dedifferentiated)

- **Most often to myxofibrosarcoma > 60%**
- **Average 7.7 years to change**
- **Others that may occur from de-differentiation**
  - Fibrosarcoma
  - Leiomyosarcoma
  - Rhabdomyosarcoma
  - Hemangiopericytoma
  - Osteogenic sarcoma

Tumors of Connective Tissue

- **Fibrous tissue = Fibroblasts, matrix (either collagen or gel-like) and myofibroblasts (smooth muscle-like makes collagen and procollagen)**
- **Ground substance (Glycosaminoglycans)**
  - Hyaluronic acid
  - Chondroitin 4 sulfate
  - Chondroitin 6 sulfate
- **Many spindle cell and pleomorphic sarcomas are probably myofibroblastic and accurate designation only consistent with the less aggressive**
- **New to this category:**
  - Solitary fibrous tumor
  - Hemangiopericytoma
  - Myxofibrosarcoma; Gardner fibroma
  - Desmoplastic fibroblastoma
  - Ischemic fasciitis
  - Low grade fibromyxoid sarcoma
  - Myxoinflammatory fibroblastic sarcoma
  - Myo- and Angiomyofibroblastoma
  - Epithelioid fibrosarcoma

Tumors of Connective Tissue (Rules)

- **Pediatric involvement rare**
- **Recur after resection**
- **Hypercellular early and collagenous late**
- **Some have specific locales**
  - Elastofibroma dorsi (scapula, serratus anterior)
  - Fibromatosis, nonaggressive - central cord plantar fascia
  - Fibroma of tendon sheath - Toe
  - Fibromatosis colli - Sternocleidomastoid muscle, unilateral

Benign Fibrous Masses

- **Solitary fibroma: Mature ovoid**
- **Fibromatosis foot**
- **Juvenile aponeurotic fibroma**
- **Aggressive fibromatosis (technically benign but recurs with a vengeance)**
- **Callous**
- **Perineural fibroma (Morton's neuroma) (Intermetatarsal entrapment neuropathy)**
- **Scar or foreign body**
- **Elastofibroma dorsi**

Specific Signals: Very Low T2 Collagenous Solitary Fibroma

- **T2 (Water-Weighted) dark**
    - Fast flow
    - Metal
    - Air
    - Blood / Acute
    - Susceptibility
    - Hemosiderin
    - Fibrous tissue
    - Cortical Bone, tendon, ligament
    - Iatrogenic (Glass, plastic, etc.)
    - Fat (?) - with high quality fat suppression (SPIR, SPAIR, Special)

T2 Hypointensity: Collagenous Fibroma and Family of Fibrotic Lesions

- **Differential Diagnoses:**
    - Fibromatosis
    - Desmoid
    - Chronic hematoma
    - Cancerous hematoma
    - Aggressive fibromatosis
    - Hemangiopericytoma
    - Fibrolipoma
    - Elastofibroma dorsi

Fibromatoses (nonaggressive variants)

- **Specific locales (Hands and feet esp. distal central cord)**
- **Older in hand; Younger in foot**
- **Flat (hand or foot) or nodular (foot)**
- **Signal = Recurrence and mitotic figure (frequency raises T2 relaxivity); More cellular in the middle**
- **Depth clinically important**
- **Familial tendency**
- **Bilateral in hand 50%**
- **In Foot – Ledderhose disease and in hand Dupuytren's disease**
- **Foot bilateral 19% but multifocal 35%**
- **Must excise with 0.5cm clear margin**
- **Recurrence 50%**
- **Plantar fibromatosis**
- **More frequent in men, caucasians, history of epilepsy and:**
    - 5% have knuckle pad fibromatosis
    - 20% Dupuytren's

Perineural Fibroma - Morton's "Neuroma"

- **Disorganized nerve in the middle**
- **Fibrosis with matrix and collagen in periphery**
- **Plantar > Dorsal**
- **Peanut or oval shape**
- **Intermetatarsal**
- **Target-like appearance in short axis view with mild enhancement**
- **Scan short axis to the metatarsal**
- **2-3 and 3-4 Intermetatarsal spaces most commonly affected**
- **RX: Orthotics and / or shoes, injections, endoscopy**

Sign: Elastofibroma Dorsi "Snowstorm"

- **Women**
- **Periscapular at least**
- **May be bilateral (10-20%)**
- **Recurs**
- **A desmoid-type lesion**
- **"Striated appearance"**
- **Most best left unresected**
- **No metastatic potential**

Fibrous Masses

- **Desmoid**
- **Benign fibroblastic**
  - Nodular fasciitis
- **Fibroma of tendon sheath**
- **Nuchal fibroma**
- **Knuckle pads**
- **Desmoplastic fibroma**

Extra-Abdominal Desmoids

- **Means “Band-like” or “Tendon-like”**
- **Names: Musculoaponeurotic fibromatosis; or Aggressive fibromatosis**
- **Age: 25-40 years-old**
- **Association: Surgery, trauma, pregnancy, estrogen**
- **Location: Lower limb; limb girdle; shoulder**
- **Multiplicity 20% and frequent recurrence above site of excision (“aggressive fibromatosis”)**
- **Dense collagen peripherally and fibroblasts in center (Myxoid; hemorrhagic; vascularity; inflammation)**
- **Recurrence increases aggressiveness**
- **Infiltrative growth in kids, but nodular growth in adults**

Extra-Abdominal Desmoids Appearance

- **Inhomogeneous SI (97%)**
- **Poor margination (89%)**
- **Neurovascular involvement (58%)**
- **Fibrosis (90 %)**
- **Intermediate signal higher than muscle but less than fat (65%)**
- **Higher T2 SI = Higher enhancement after contrast**
- **Multicentricity: Distal lesions darker and more heterogeneous**

Extra-Abdominal Desmoids Differential Superficial Masses

- **Superficial fibromatoses**
- **Foreign body reaction**
- **Granuloma annulare (Shin)**
- **Pentazocine induced myopathy and SQ fibrosis**
- **Postsurgical scar**
- **GCTS**
- **Hemorrhage**

Abdominal Desmoids

- Rectus and external oblique
- 20 to 40 years-old in 70%
- W >> M
- 5-15 cm
- Rectus origin does not cross midline
- May occur in cesarean section incision
- Typical hyperdensity on CT and fibrous on MR
- DDX: Endometrioma; Neural tumor

Nodular Fasciitis

- Names: Pseudosarcomatous fasciitis or proliferative fasciitis
- Local injury or inflammation triggers
- Mean age 39 and my own series W > M
- Three types: SQ > Muscle > Fascial
- Older more fibrous
- 3-6 weeks of peak growth and then start to “burn out”
- Forearm flexor surfaces!
- Histologic Types: Myxoid; Cellular and fibrous
- Histologies evolve from myxoid to fibrous
- Recurrence is rare
- Peripheral intense enhancement (“Reverse target sign”)
- Myxoid-type resembles myxofibrosarcoma and fibrous-type fibromatosis or fibrosarcoma
- Looks aggressive on MRI

Fibroma of Tendon Sheath

- Thumb, great toe, middle and index finger and volar wrist 80%
- Foot less common but rather adventitial burso- callous cyst simulates
- Men 2X women
- Usually < 2 cm
- Hands and feet almost exclusively
- Slow growth, not in the forearm like nodular fasciitis

Nuchal Fibroma

- Interscapular and paraspinous
- Entrapped adipose tissue and nerve proliferation present on pathology
- Linked to: Diabetics; Gardner’s; fibromatosis and dermatofibroma protuberans
- Small foci of high T1 signal due to trapped fat

Collagenous Fibroma

- **Men 75%**
- **5th to 6th decade**
- **Sharp, well-demarcated; oval; moveable mass in skeletal of subcutaneous tissue**
- **Sharp zone of transition and low on T1 and T2**

Intermediate Grade Fibromyoblastic Tumors

- **Solitary fibrous tumor**
    - Mesenchymal tumor with hemangiopericytoma-type vascular branching
    - SQ 40%
    - Pleura; face; meninges
    - Slow-growing painless mass
    - 10-15% malignant
    - Lower but heterogeneous on MR
- **Hemangiopericytoma** [5]
    - Does not metastasize
    - Middle-aged females
    - Pelvis and retroperitoneum
    - Resembles solitary fibrous tumor with branching vessels; thin, staghorn-like
    - Middle aged or elderly patients
    - Hemangioma-like in conjunction with multiple phleboliths
    - May simulate a large gastrocnemius semimembranosus bursal cyst about knee
    - Multiloculated, invasive
    - Density packed areas of signal void seen within hyperintense tumor on T2
    - Areas with slower flow may be intermediate on T1, hyperintense on T2
- **Inflammatory myoblastic pseudotumor**
- **Infantile fibrosarcoma**
- **Inflammatory myoblastic sseudotumor:**
    - Children young adults with fever, weight loss and pain
- **Infantile fibrosarcoma:**
    - First year of life
    - Rapid growth
    - Large size
    - Resembles infantile fibromatosis

Malignant Fibromyoblastic Tumors

- **Adult fibrosarcoma**
- **Myxofibrosarcoma "Malignant fibrous histiocytoma"**
    - Cortical erosion common - Uncommon for other sarcomas
    - Fluid-like components, but no fat = MFH (blood may simulate fat)
    - Less likely considerations:
        - Synovial sarcoma
        - Leiomyosarcoma
        - Soft-tissue Ewing's
        - Myxoid tumors
- **Fibrosarcoma multiforme**
- **Fibromyxoid sarcoma**

Fibrous Tumors of Infancy

- **Fibrous hamartoma of infancy**
- **Infantile digital fibromatosis**
- **Infantile myofibromatosis**
- **Juvenile hyaline fibromatosis**
- **Gingival fibromatosis**
- **Fibromatosis colli**
    - Newborn; Torticollis 40%
    - Sternocleidomastoid: Ischemia; Fibroblastic reaction, little siderosis
    - 0.4% of newborns
    - Breech or complicated delivery 4%
    - 2nd to 4th week
    - 2-3 cm mass initially grows rapidly and subsides by 2 years
    - Never, ever recurs: T2 mild hyperintensity
- **Infantile aggressive fibromatosis (Desmoid-type)**
- **Solitary**
- **Painless**
- **< 2 cm**
- **Shoulder, axilla, upper arm**
- **Some collagen and fat**
- **Recurs often proximally**

Infantile Fibromatosis / Fibrosarcoma

- **Infantile musculoaponeurotic desmoid**
- **Head and neck unifocal (> Shoulder, arm, thigh)**
- **When multifocal; Abdomen**
- **Often detected in first three months**
- **Names:**
    - Aggressive fibromatosis
    - Infantile fibrosarcoma
    - Desmoplastic fibrosarcoma of infancy
    - Medullary fibromatosis

Neural Tumors

- **Schwannoma**
    - Often isolated, common, sometimes cystic, speckled internal T2 signal, scattered fat on T1 due to Antoni B cells
- **Neurofibroma**
    - Rarely cystic; occasional fibrous center; associated with NF1
- **Neurilemmoma**
    - Synonym for schwannoma
- **Stump neuroma**
    - History of trauma or transection; target sign with lower perineural fibrosis and higher signal center due to disorganized inflamed nerve
- **Morton's neuroma**
    - Friction neuroma from entrapment neuropathy
- **Neurofibrosarcoma**
    - Large, disorganized, invasive, vascular, may have NF1

Vascular Lesions

- Vascular malformations are NOT real tumors and can be divided into high and low flow states
- Hemangioendothelioma may be benign or malignant (epithelioid type may arise in bone)
- Angiosarcoma is aggressive
- Younger children and adults vascular lesion presentation more common
- Endothelial growth characterizes and distinguishes hemangiomas from vascular lesions
- Hemangiomas characterized by phase of proliferation and a stationary period followed by involution
- Superficial: Capillary; cavernous; venous; arteriovenous
- Hemangiomas are grouped as muscular, synovial, and intramural
- Cutaneous lesions best diagnosed clinically
- Intramuscular hemangioma resembles angiolipoma
- Superficial: Small vessel; Large vessel; and mixed (SM Vessel Simluates Sarcoma)

Vascular Lesions (Angiomatosis)

- Large segments of the body; large vessels; large size
- Large amount of pure fat
- The distinction between intramuscular hemangioma and angiomatosis is made clinically

Vascular Lesions (Mulliken Classification of Cutaneous Vascular Lesions)

- Rapid growth, stabilize, and then involution; Female predominance not present at birth. These are called infantile hemangioma; majority do not need treatment
- Some lesions generate cellular proliferation not present at birth
- Some hemangiomas are hormonally responsive and grow at puberty and during pregnancy!

Vascular Lesions (Vascular Simple Combined Classification)

- Proliferative phase: Capillary malformation: AV fistula, malformation; Cap-lymphatic venous malformation (Klippel-Trenaunay Weber)
- Involutive phase: Lymphatic malformation: Lymphatic venous malformation; capillary AVM; (Parkes-Weber) Capillary-Lymphatic AVM
- Other tumors: Venous malformation

Vascular Masses

- **Hemangiomas**
  - Infantile type
    - 3-5 X more frequent in females
    - Unique immunophenotype - Glucose transporter protein-1 shared by placental microvessels
    - Face and neck (60%); trunk (25%); extremities (15%)
    - Two biologic phases
      - > Proliferative phase rapid growth in first few months stabilizes at 9-10 months
      - > Involuting phase for next several years progresses to fibrofatty appearance by 7-10 years
  - Congenital
    - Males = Females; head and neck; extremities near a joint; pink to purplish rather than strawberry (Infantile-type); no glucose protein
      - > Rapidly involuting-type: Present at birth; involutes by 14 months;
      - > Noninvoluting-type: Grows proportionally with the child; skin of head; more heterogeneous +/- flow voids; fat stranding
    - 7% of all benign soft tissue tumors
    - Usually skin and subcutaneous
    - Capillary for the largest sub-group
  - Juvenile type
    - Occurs superficial head and neck a few weeks after birth
    - Maximal size at 6 months and then regress
    - Subtypes: Tufted; verrucous and senile
  - Cavernous
    - Larger
    - Less circumscribed
    - May be locally destructive
    - Epithelioid and granulation-type
    - Epithelioid
      - > Well formed but immature vessels and a prominent inflammatory component. Nodular masses in forehead and digits may simulate epidermoid.
    - 80-90% occur in muscle in first three decades
    - Synovial and peripheral nerve hemangioma are rare (usually suprapatellar pouch of knee joint)
    - May simulate hemophilic pseudotumor

- **Capillary malformation**
  - Dermis
  - “Port-wine” stain (as in encephalotrigeminal angiomatosis - Sturge Weber)
  - Image the brain for deeper lesions in encephalotrigeminal angiomatosis
- **High and low flow musings**
  - Low flow-types
    - Venous, capillary, lymphatic combined
  - High flow state
    - Arteriovenous malformations; fistulas (including dialysis shunts)
  - Arteriovenous malformations
    - At birth but no involution
    - Enlarge with trauma, puberty, pregnancy, iatrogenic
  - Arteriovenous fistula
    - Single large channel
    - Head and neck or due to venous puncture complication (iatrogenic)
  - Venous malformation
    - Blue purple when superficial - Head / neck (40%), extremities (40%)
    - Trunk (20%) - Slow flow and phleboliths
  - Combined malformation
    - Slow flow-types
      - Klippel - Trenaunay syndrome (Capillary, lymphatic, venous)
      - Proteus syndrome
      - Maffucci’s syndrome
    - Fast flow-types: Parkes – Weber; (Capillary or AV shunting with fistulas)
- **Lossless flow void**
  - Family of vascular masses
    - AVM (Void)
    - Venous
    - Mixed
    - Cavernomas
    - Hemangiomas
    - Aneurysm, pseudoaneurysm
- **Specialized vascular or vascular organ receptor lesions**
  - Glomus tumor
  - Pheochromocytoma
  - Ganglion cell neoplasm
  - Angiosarcoma / Lymphosarcoma
  - Hemangioendothelioma / hem angioendotheliomatosis
  - Kaposi’s sarcoma

- **Lymphangioma**
  - 75% head and neck
  - Microcystic
  - Macrocystic variety
  - Often mixed with other malformations (especially venous; particularly orbit)
  - High T2 signal
  - Does not accumulate Gadolinium
  - Signals:
    - T2 (water-weighted) very bright signal causes or differential
      - > Pure fluid
      - > Chronic blood
      - > Proteinaceous fluid
      - > Gel or myxoid material
      - > High cytoplasm
      - > Slow flow
      - > CSF, urine, bile, seroma, lymphocele
- **Venous wall lymphoma**
  - Solid
  - Hypoechoic
  - Low T2
  - Intermediate T1
  - Enhances
  - Infiltrates
  - Homogeneous or smooth

Vascular Tumors of Intermediate Malignancies

- **Glomus**
  - Pacinian corpuscles (thermoregulatory structure)
  - Nail bed
  - Enhances
  - Speckled void signals
  - Does not destroy bone
  - Very bright on T2

- **Hemangiopericytoma** [5]
  - Does not metastasize
  - Middle-aged females
  - Pelvis and retroperitoneum
  - Resembles solitary fibrous tumor with branching vessels; Thin, staghorn-like
  - Middle aged or elderly patients
  - Hemangioma-like in conjunction with multiple phleboliths
  - May simulate a large gastrocnemius semimembranosus bursal cyst about knee
  - Multiloculated, invasive
  - Density packed areas of signal void seen within hyperintense tumor on T2
  - Areas with slower flow may be intermediate on T1, hyperintense on T2
  - Composed of Pericytes
- **Kaposiform hemangioendothelioma**
  - Infiltrative growth
  - Endothelial spindling
  - Microthrombi
  - Hemosiderin
  - Lymphatic abnormalities
    - Antibody D2-40 positive detects podoplanin
    - Occasionally metastasizes to nodes
    - No distant metastases
    - Usually first year of life
    - Differential
      - > Spindle cell hemangioendothelioma; Adults
  - Rapid growth occasionally regresses
    - > 50% have assabach-Merritt Syndrome (KMS) - Also seen with tufted angioma - clinical Dx (Nakagawa Angioblastoma)
    - KMS or local infiltration produce 10-15% mortality
    - MR: ill-defined; siderosis; stranding

Vascular Tumors of High Malignancies

- **Angiosarcoma arises from highly differentiated cells but characterized by irregular anastomotic vascular channels**
- **Kaposi's sarcoma**
  - Vascular channels and HHV-8
  - Associated with immune dysfunction (e.g. HIV)

Tumors of Muscle Origin

- **Smooth muscle**
  - Benign: Leiomyoma
  - Malignant: Leiomyosarcoma
- **Striated muscle**
  - Benign: Rhabdomyoma (adult, fetal, genital)
  - Malignant: Rhabdomyosarcoma (embryonal; pleomorphic; alveolar)

Masses of Tendon Origin

- **Ganglion pseudocyst**
  - Signal
    - Very high T2 signal (homogeneous)
    - Water signal
    - Relative homogeneity (septa only - no synovitis)
    - Tail arising from tendon sheath or capsule
    - Pseudocyst with fibrous rim, firm
    - Proteinaceous fluid, T1 lower than muscle
  - Pearls [5]
    - Water signal lesion
    - Homogeneous hyperintense T2, hypointense T1
    - Post-traumatic due to friction biomechanics therefore characteristic locations such as dorsal scaphocapitolunate capsule or posterosuperolateral / posterosuperomedial retrofemoral
    - Peritendinous or pericapsular
    - May have a small tail-like protrusion of decreased T1 or increased T2 signal appearing to emanate from the joint or adjacent tendon
    - Not a true cyst.
    - Presents as a soft tissue mass, tender to firm palpation. Under pressure!
    - More common in the hands than in the feet

- Pitfalls of masses in the foot simulating ganglia [5]
  - Capsulosynovial prolapse may arise from the tibiotalar or talocalcaneal joints especially from subtalar inferolateral retinacular bursa ("stem or frondiform" ligament bursa)
  - Lies deep to the overlying muscle and capsular cysts are compressed by flat muscle while ganglia rempins round and push muscle away
  - Fluid can be seen in the medial compartment flexor tendon group with dependent position at the intersection where the flexor hallucis and flexor digitorum criss-cross (Henry's Master Knot). Both the flexor hallucis longus and biceps long head sheaths communicate with the foot and shoulder joints. With joint effusions these sheaths may distend and simulate high signal ganglia.
  - This dependent accumulation of fluid occurring in patients with ankle joint effusion is seen at the knot of Henry and is sometimes misconstrued as a ganglion or cyst
- Intratendinous masses
  - Amyloid
  - Xanthoma
  - CPPD
  - Gout
  - Focal tendinosis
  - Giant cell tumor of tendon sheath (GCTS)
  - Granuloma

Angiomatous Syndromes

- **Kasabach-Merritt syndrome**
  - Enlarging hemangioma
  - Thrombocytopenia
  - Microangiopathic anemia
  - Consumptive coagulopathy
  - Mortality 21%
  - Associated with large vascular liver lesions
- **Maffucci's syndrome**
  - Multiple hemangiomas and enchondromas
  - Anomalies at birth are cavernous
  - Vascular develops before cartilage
  - Malignant sarcomatous degeneration 21%

- **Klippel-Trenaunay-Weber**
  - Varicose veins
  - Cutaneous hemangioma
  - Bone and soft tissue enlargement
  - Unilateral
  - Lower extremity
- **Osler-Weber-Rendu** [2]
  - Genetic; autosomal dominant
  - MRI visibility: Cerebral and cerebellar arteriovenous malformations (AVMs); Liver
  - Clinical Triad
    - Epistaxis
    - Multiple telangiectasias
    - Positive family history
- **Proteus**
  - Local overgrowth or macrodactyly
  - SQ tumors and various bone lesions
- **Angiomatosis**
  - Local overgrowth or macrodactyly
  - SQ tumors and various bone lesions

Hemangioendothelioma

- **Epithelioid of soft tissues rare in children**
- **Solitary**
- **Favorable prognosis**

Angiosarcoma

- **1% of all sarcomas**
- **Predilection of the lower extremity and the abdominal cavity (cutaneous forms in the head and neck)**
- **Chronic lymphedema risk factor for angiosarcoma (anemia; coagulopathy)**
- **Usually epithelioid-type**

Squamous Cell Carcinoma

- **May occur with chronic osteomyelitis or Paget's disease**
- **Cytoplasm poor, therefore low or intermediate T2 relaxation**
- **Homogeneous**
- **Necrosis after radiation**

Musculoskeletal Masses on MR: Compartment Syndromes; Inflammations and Infections

- **Signals**
  - Lossless (Very Low)
    - Metal T2* blooms
    - Postoperative T2* blooms
    - Susceptibility T2* blooms
    - Hemosiderin T2* blooms
    - Air lossless
    - Flow
    - Dense calcium
- **Necrotizing fasciitis**
  - Streptococcus variant
  - Rapid progression
  - Signal void
  - Linear
  - Fournier's gangrene
  - Necrosis of superficial tissues or fascia
  - "Flesh-Eating" bacteria
  - CT best demonstrates air
  - MR-sensitive; CT-specific
  - Time-sensitive diagnosis: True emergency
- **Infectious tenosynovitis**
  - Differential diagnoses
    - Fungal - Sporothrix Schenckii; Sporotrichosis
    - Mycobacterial
      - > Marinum - Summertime from swimming pools
      - > Kansasii - More common in warm climate
      - > Avium intracellulare
    - Rheumatoid arthritis (RA) - Synovitis, erosions
    - Juvenile RA - Synovitis, erosions
    - Seronegative spondyloarthropathy (Psoriasis) - "Sausage digit"
    - Collagen vascular disease - Synovitis

- **Pretibial swelling**
  - Stress
  - Erythema nodosum - Immune inflammatory response
  - Pyoderma gangrenosum - Crohn's disease
  - Myxedema - Hypothyroidism
  - Weber-Christian - Pannicular necrosis
  - Fat necrosis
  - Granuloma annulare
    - Benign
    - Children
    - Palisading granuloma
    - Firm
    - Painless 'Pretibial'
  - Occiput
- **Cat-scratch disease**
  - Bartonella
  - Differential diagnoses for epitrochlear adenopathy:
    - Mononucleosis
    - Tuberculosis
    - Hodgkin's disease
    - Syphilis
    - Local infection
- **Key descriptors for infections**
  - Fat necrosis
  - Cellulitis - Superficial or deep
  - Myofascitis
  - Abscess
  - Sinus tract
  - Osteomyelitis, sequestration, septic arthritis
  - Other key issues
    - Compartment syndrome
    - Drainability
    - Gas
- **Myositis and Myonecrosis**
  - Infectious or noninfectious
  - Trauma or surgery
  - Inflammatory necrosis
  - Air = Poor prognosis
  - Myoglobinuria poor prognosis
  - Diabetic amyotrophy thigh and foot

- **Compartment syndrome**
  - Heterogeneous hemorrhagic signal
  - Mass effect
  - Neurogenic edema
  - Bulging / Protruding fascia
  - Hemorrhage
  - Vascular compression
- **Abscess muscular etiologies**
  - Diabetes
  - IV drug abusers
  - AIDS
  - Immunosuppression
  - Trauma

Pearls of Foot / Ankle: Soft Tissue Masses [5]

- **Common**
  - Morton's neuroma (perineural fibroma)
    - Mild hyper-intensity or intermediate T2 signal with central hypointensity due to abundant fibrosis, with female predilection, between the third and fourth metatarsal heads
  - Neuroma
    - Mild to moderate T2 hyperintensity with occasional mixed central T2 hypointensity
  - Post-amputation neuroma
    - History of trauma or amputation and low or intermediate T2 signal
  - Ganglion
    - Homogeneous hypointense T1 and hyperintense T2 signal with peritendinous or pericapsular predilection
  - Giant cell tumor of tendon sheath
    - Mixed T2 hyperintensity and hypointensity, may be infiltrative with involvement or destruction of cortical or medullary bone
- **Uncommon**
  - Implantation epidermoid
    - Hypointense T1, hyperintense T2 with a subcutaneous location
  - Implantation granuloma
    - Intermediate T1 and slightly hyperintense T2 signal , central hypointensity
  - True neoplasm
    - Signal varies with lesion histology (especially synovial sarcoma)

Soft Tissue Tumor Signal Characteristics [5]

Tumors	Signal Characteristics
Fibrohistiocytic tumors (inter. malignancy)	Heterogeneous
Glomus tumor	Heterogeneous
Synovial sarcoma	Heterogeneous
Clear cell sarcoma	Homogeneous
Epithelioid sarcoma	Heterogeneous
Liposarcoma	Homogeneous* or Heterogeneous
Angiosarcoma w/ and w/o lymphedema	Heterogeneous
Rhabdomyosarcoma	Heterogeneous
Hemangiopericytoma	Homogeneous* or Heterogeneous
Hemangioma	Homogeneous* or Heterogeneous
Alveolar sarcoma (soft part)	Heterogeneous
Fibromatoses	Homogeneous
Extraskeletal Ewing's sarcoma	Heterogeneous
Hemangioma	Heterogeneous
Giant cell tumor (tendon sheath)	Homogeneous

*Myxoid and well-differentiated histology more homogeneous

Malignancy in the Foot [5]

- **Synovial sarcoma, the only malignant soft tissue tumor with a major predilection for the foot, which is the second most common site after the knee (fibrosarcoma minor predilection?)**
- **Originates from the tissues adjacent to the joint**
- **Most often seen 20-40 years old**
- **Slow growth pattern**

Most Common Malignant Soft Tissue Tumors of the Foot and Ankle [5]

- **Synovial sarcoma**
- **Extraosseous myxoid chondrosarcoma**
- **Unspecified sarcoma**

SOFT TISSUE APPENDIX

Soft Tissue Masses By Signal [6]

- **T2 Signal Hyperintensity with Central Hypointensity**
  - Neurofibroma
  - Sarcoidosis
  - Acute hematoma

- **Moderate to Marked T1 Hyperintensity**
  - Lipoma
  - Hematoma
  - Well-differentiated liposarcoma
  - Myxoid liposarcoma or myxosarcoma

- **Homogeneous T1 Hypointensity**
  - Cyst
  - Ganglion
  - Lymphocele
  - Hygroma
  - Seroma

- **Mild T1 Hyperintensity (Relative to Muscle)**
  - Neurilemmoma or neurofibroma
  - Hemangioma
  - Abscess
  - Solid malignancies (sarcomas and carcinomas)
  - Hemorrhagic masses

Musculoskeletal Masses on MR

- **Matrix of Non-Aggressive, Soft-Tissue Mass Characterization on MR**

- **Cartilage**
  - Lobulated intermediate T1
  - High T2
  - Low speckled calcium
  - Arcs and whorls vs osseous (ivory, dark, cloudy matrix)
-
- **Vascular**
  - Linear or lobulated; flow effect; phleboliths

- **Fibrous (Mature)**
  - Low T1 and T2

- **Blood**
  - High T1, low T2 (subacute)

- **Air**
  - Very, very low T1 and T2 + shape

- **Fat**
  - High T1; very low T2 fat suppression

- **Water**
  - Low T1, high T2, smooth (matches CSF)

- **Calcium**
  - Low or high T1 and T2 (depending on marrow content)

More About Signal:

- **T1 (fat weighted) bright**
  - Fat
  - Proteinaceous fluid (myxoid)
  - Flow
  - Metal
  - Marrow
  - Contrast injected agent
  - Blood (subacute to chronic)

- **T1 (fat weighted) very low**
  - Fluid proteinaceous or not
  - Fibrous
  - Blood (very early)
  - Metal
  - Flow
  - Air
  - Hemosiderin (concentrated)
  - Contrast (dark enhancers)
  - Cortical bone

- **T2 (water weighted) dark**
  - Fast flow
  - Metal
  - Air
  - Blood / Acute
  - Susceptibility
  - Hemosiderin
  - Fibrous
  - Cortical bone, tendon, ligament
  - Iatrogenic (glass, plastic, etc.)
  - Fat (?)

American Joint Committee Staging Protocol For Sarcoma and Soft Tissue [4]

Stage	Grade	Tumor	Nodes	Metastases
IA	1	1	0	0
IB	1	2	0	0
IIA	2	1	0	0
IIB	2	2	0	0
IIIA	3-4	1	0	0
IIIB	3-4	2	0	0
IVA	1-4	1-2	1	0
IVB	1-4	1-2	0-1	1

- Characteristics
  - Histologic grade (G)
  - G1 - Well differentiated
  - G2 - Moderately well differentiated
  - G3 - Poorly differentiated, undifferentiated

- Primary Tumor (T)
  - T1 - Tumor 5 cm or less in greatest dimension
  - T2 - Tumor more than 5 cm in greatest dimension

- Regional Lymph Nodes (N)
  - N0 - No regional lymph node metastases
  - N1 - Regional lymph node metastases

- Distant Metastases (M)
  - M0 - No distant metastases
  - M1 - Distant metastases

Most Common Benign Soft Tissue Lesions of the Foot* [1]

Lesions	Percent
Interdigital neuroma	50
Neuroma	24
Ganglion cyst	9
Exostosis	7
Fibroma	3
Digital mucous cyst	1
Plantar fibromatosis	1
Lipoma	< 1
Hemangioma	< 1
Leiomyoma	< 1
Neurofibroma	< 1
Rheumatoid nodule	< 1
Gouty tophus	< 1
Giant cell tumor of the tendon sheath	< 1
Nodular subepidermal fibrosis	< 1
Osteochondroma	< 1
Thrombosed varix	< 1
Neurilemmoma	< 1

* Excised in a podiatric office setting (excluding skin lesions)

REFERENCES

1. Deutsch AL, Mink JH, Kerr R. [eds] MRI of the foot and ankle. New York, Raven Press, Ltd. 1992: 228.
2. Hacking, C. (sourced 21Aug2018) *Osler-Weber-Rendu syndrome.* Radiopaedia: https://radiopaedia.org/articles/hereditary-haemorrhagic-telangiectasia
3. Miller MD. Review of orthopaedics [2nd ed]. Philadelphia, W.B. Saunders Co., 1996: 293.
4. Moreau G, Bush CH, Scarborough MT, et al. Surgical considerations in a diagnostic imaging evaluation of musculoskeletal masses. Weatherall PT ed, MRI clinics of N America, 3:580, 1995.
5. Pomeranz SJ. Gamuts & Pearls in MRI & Orthopedics. Ohio, The Merten Company, 1997.
6. Pomeranz SJ. MRI of the Foot & Ankle: Pearls, Pitfalls & Pathology. Ohio, MRI EFI Publications, 2002.
7. Wu JS. and Hochman MG. Soft-tissue Tumors and Tumorlike Lesions: A Systematic Imaging Approach. Radiology: Volume 253: Number 2, 2009. (Original source: Fletcher CD, Unni KK, Mertens F, eds. WHO classification of tumours: pathology and genetics of tumours of soft tissue and bone. Lyon, France: IARC, 2002.)