Downloaded from www.ajronline.org by 66.69.39.220 on 11/19/23 from IP address 66.69.39.220. Copyright ARRS. For personal use only; all rights reserved

Validation of MRI Classification System for Tibial Stress Injuries

Richard Kijowski[1]
James Choi[2]
Kazuhiko Shinki[3]
Alejandro Munoz Del Rio[1]
Arthur De Smet[1]

OBJECTIVE. The purpose of our study was to compare an MRI classification system for tibial stress injuries with semiquantitative MR features of injury severity and clinical outcome.

MATERIALS AND METHODS. Two musculoskeletal radiologists retrospectively reviewed in consensus the MR findings of 142 tibial stress injuries to quantify the degree of periosteal and bone marrow edema and grade the injuries using the Fredericson classification system (grade 1 = periosteal edema only, grade 2 = bone marrow edema visible on T2-weighted images, grade 3 = bone marrow edema visible on T1-weighted and T2-weighted images, grade 4a = multiple focal areas of intracortical signal abnormality, and grade 4b = linear areas of intracortical signal abnormality). Kruskal-Wallis tests were used to determine the relationship between the grade of stress injury and the degree of periosteal and bone marrow edema and the time to return to sports activity.

RESULTS. Grade 4b injuries had significantly ($p < 0.002$) more severe and grade 1 injuries less severe periosteal and bone marrow edema than grades 2, 3, and 4a injuries. Grade 4b injuries had significantly ($p < 0.002$) longer time and grade 1 injuries shorter time to return to sports activity than grades 2, 3, and 4a injuries. There was no significant difference ($p = 0.06–0.79$) among grades 2, 3, and 4a injuries in the degree of periosteal and bone marrow edema and the time to return to sports activity.

CONCLUSION. Grades 2, 3, and 4a stress injuries had similar degrees of periosteal and bone marrow edema and similar time to return to sports activity, which suggests that these three grades can be combined into a single category in an abbreviated Fredericson classification system.

Keywords: grading system, MRI, stress fracture, stress injury, tibia

DOI:10.2214/AJR.11.6826

Received March 9, 2011; accepted after revision August 19, 2011.

[1]Department of Radiology, University of Wisconsin, Clinical Science Center–E3/311, 600 Highland Ave, Madison, WI 53792-3252. Address correspondence to R. Kijowski (rkijowski@uwhealth.org).

[2]Iowa Radiology, Des Moines, IA.

[3]Department of Mathematics, Wayne State University, Detroit, MI.

AJR 2012; 198:878–884

0361–803X/12/1984–878

© American Roentgen Ray Society

Stress injuries represent a spectrum of osseous abnormalities that occur in response to chronic repetitive stress applied to healthy bone. Stress injuries are common in athletes and represent approximately 10% of all injuries seen in sports medicine clinics. The vast majority of stress injuries involve the tibia, followed in order of decreasing frequency by the tarsal bones, metatarsals, femur, and fibula [1].

MRI has become the imaging modality of choice at most institutions for evaluating patients with suspected tibial stress injuries. MRI is more sensitive than radiography, nuclear medicine scintigraphy, and CT for detecting early stress injuries [2–4]. MRI can also identify injuries to the muscles and tendons of the lower extremity, which are common in athletes and may present with similar clinical findings as stress injuries. In addition, MRI can be used to grade the severity of the stress injury and thereby assist in the clinical management of the patient [5].

Fredericson and associates [5] developed an MRI classification system for tibial stress injuries on the basis of findings of periosteal edema, bone marrow edema, and intracortical signal abnormality. According to the classification system, a grade 1 injury is defined as periosteal edema only, a grade 2 injury is defined as bone marrow edema visible on T2-weighted images only, a grade 3 injury is defined as bone marrow edema visible on both T1-weighted and T2-weighted images, and a grade 4 injury is defined as intracortical signal abnormality. Although commonly used to evaluate stress injuries on MRI, the Fredericson classification system has never been validated in a large clinical study. Thus, this study was performed to compare the Fredericson grade of tibial stress injury with semiquantitative MR features of injury severity and clinical outcome. It is our hy-

Downloaded from www.ajronline.org by 66.69.39.220 on 11/19/23 from IP address 66.69.39.220. Copyright ARRS. For personal use only; all rights reserved

pothesis that higher Fredericson grades of stress injury will be associated with more severe periosteal and bone marrow edema and a longer time to return to sports activity.

Subjects and Methods

Study Group

The study was performed in compliance with HIPAA regulations and with approval from our institutional review board. A waiver of informed consent was obtained before performing the study. A musculoskeletal MRI database was used to identify 152 consecutive patients who were referred for MRI of the calf at our institution between January 1, 2000, and March 1, 2006, with a clinical history to rule out tibial stress injury. Fourteen of these 152 patients had normal MRI findings and were allowed to return to sports activity as tolerated. One hundred thirty-eight patients had MRI findings consistent with tibial stress injury, including periosteal edema, bone marrow edema, and intracortical signal abnormality. Our study group consisted of the 138 patients (47 males and 91 females; age range, 14–54 years; average age, 22.3 years) with a clinical and MR diagnosis of tibial stress injury.

All 138 patients in the study group were athletes involved in sports activities that included long-distance running, sprinting, pole vaulting, high jumping, basketball, soccer, and dancing. All patients were evaluated by one of three sports medicine specialists at our institution before the MRI examination, complained of focal pain within the tibia that was exacerbated by physical activity (duration of symptoms ranging between 4 and 600 days, with an average duration of 57.6 days), and had point tenderness over the tibia on physical examination. No patient had a history of acute trauma to the lower extremity or clinical manifestations to suggest the presence of infection or malignancy. Four patients had bilateral stress injuries. Thus, our study group consisted of 138 patients with 142 tibial stress injuries evaluated with MRI.

MRI

All patients in the study group underwent MRI of the tibia within 2 weeks of their initial clinic visit. All MRI examinations were performed on the same 1.5-T scanner (Signa HdX scanner, GE Healthcare) using a phased-array extremity coil (GE Healthcare). All MRI examinations included an axial T1-weighted spin-echo sequence (TR range/TE range, 400–600/15–30) and a fat-suppressed T2-weighted fast spin-echo sequence (TR range/TE range, 2000–4000/60–80; echo train length; 8). All MRI examinations also included a T1-weighted spin-echo sequence (TR range/TE range, 400–600/15–30) and either a fat-suppressed T2-weighted fast spin-echo sequence (TR range/TE range, 2000–4000/60–80; echo train length, 8) or a STIR sequence (TR/TE, 3000/44; inversion time, 160 ms; echo train length, 8) performed in the coronal or sagittal plane or both. All fat-suppressed T2-weighted fast spin-echo sequences were performed using a frequency selective chemical presaturation pulse (ChemSat, GE Healthcare) to suppress signal from adipose tissue. All MR examinations were performed with an FOV between 16 and 24 cm, a slice thickness between 3 and 7 mm with an interslice gap between 0.4 and 3 mm, a matrix of 256 × 192 or 256 × 256, and one or two excitations.

Review of MRI Examinations

All MRI examinations were retrospectively reviewed in consensus on an ALI workstation (version 5, Horizon Medical Imaging Systems) by two fellowship-trained musculoskeletal radiologists who had 4 and 7 years of clinical experience. The radiologists were blinded to the clinical findings of all patients when reviewing the MRI examinations.

The radiologists graded the severity of the tibial stress injury on each MRI examination using the Fredericson classification system, which was based on the findings of periosteal edema, bone marrow edema, and intracortical signal abnormality [5]. Periosteal edema was defined as a linear area of high T2 signal intensity (greater than the signal intensity of muscle) immediately adjacent to the outer surface of the tibial cortex. Bone marrow edema was defined as a focal or ill-defined area of low T1 signal intensity (less than the signal intensity of muscle) and high T2 signal intensity (greater than the signal intensity of muscle) within the intramedullary canal of the tibia. Intracortical signal abnormality was defined as either a linear area or multiple focal areas of intermediate T1 and T2 signal intensity (similar to the signal intensity of muscle) within the tibial cortex. In the original article by Fredericson and associates [5], intracortical signal abnormality in a grade 4 stress injury was defined by the presence of a linear fracture line through the tibial cortex. More recently, multiple focal areas of intracortical signal abnormality have been described within the tibial cortex in patients with stress injuries [2]. Because these multiple focal areas of signal abnormality are thought to represent some form of injury to the tibial cortex, their presence was considered to constitute a grade 4 stress injury in our study. Thus, the Fredericson classification system used in our study was modified to distinguish between stress injuries with multiple focal areas of intracortical signal abnormality (grade 4a injuries) and stress injuries with linear areas of intracortical signal abnormality (grade 4b injuries) (Table 1).

When periosteal edema was present on the tibial cortex, the radiologists assessed its severity using two separate methods. The periosteal edema was considered to be mild if it involved less than 25% of the circumference, moderate if it involved between 25% and 50% of the circumference, and severe if it involved more than 50% of the circumference of the tibial cortex on axial fat-suppressed T2-weighted fast spin-echo images. The maximal thickness of the periosteal edema was also measured on axial fat-suppressed T2-weighted fast spin-echo MR images perpendicular to the cortical surface of the tibia using electronic calipers on the ALI workstation. In addition, the location of the periosteal edema on the tibial cortex in both the longitudinal and axial planes was documented. When periosteal edema involved more than 25% of the circumference of the tibia in the axial plane, the location of the thickest area of periosteal edema was recorded.

When bone marrow edema was present within the intramedullary canal of the tibia, the radiologists assessed its severity using two separate methods. The bone marrow edema was considered to be mild if it involved less than 25% of the total cross-sectional area, moderate if it involved between 25% and 50% of the total cross-sectional area, and severe if it involved more than 50% of the total cross-sectional area of the intramedullary canal of the tibia on axial fat-suppressed T2-weighted fast spin-echo images. The maximal longitudinal length of

TABLE 1: Fredericson MRI Classification System for Tibial Stress Injuries

Grade of Stress Injury	MRI Findings
0	No abnormality
1	Periosteal edema with no associated bone marrow signal abnormalities
2	Periosteal edema and bone marrow edema visible only on T2-weighted images
3	Periosteal edema and bone marrow edema visible on both T1-weighted and T2-weighted images
4a	Multiple focal areas of intracortical signal abnormality and bone marrow edema visible on both T1-weighted and T2-weighted images
4b	Linear areas of intracortical signal abnormality and bone marrow edema visible on both T1-weighted and T2-weighted images

Downloaded from www.ajronline.org by 66.69.39.220 on 11/19/23 from IP address 66.69.39.220. Copyright ARRS. For personal use only; all rights reserved

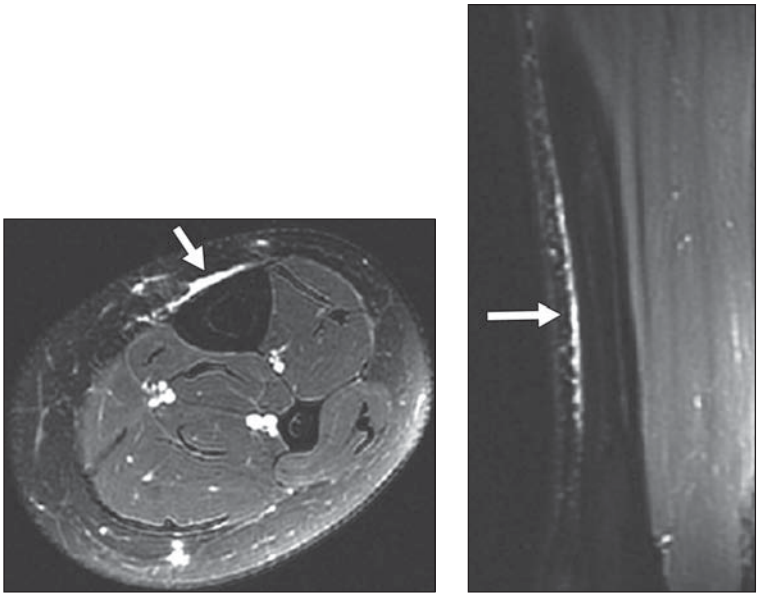

Fig. 1—24-year-old female long distance runner with grade 1 tibial stress injury who successfully returned to sports activity 14 days after her initial clinic visit.
A and **B,** Axial (**A**) and corresponding coronal (**B**) fat-suppressed T2-weighted fast spin-echo images of calf show mild periosteal edema (*arrows*) on medial cortex of mid tibial diaphysis, with no associated bone marrow signal abnormality.

the bone marrow edema was also measured on sagittal or coronal fat-suppressed T2-weighted fast spin-echo or STIR images using electronic calipers on the ALI workstation.

Clinical Chart Review

The clinical charts of all 138 patients in the study group were retrospectively reviewed by a musculoskeletal radiologist who was blinded to the MRI findings of all patients. Seventy of the 138 patients had clinic notes from their sports medicine specialist at multiple time points during treatment of their tibial stress injuries. The sports medicine specialists had access to the official interpretations of the MRI examinations of all patients. However, the MRI reports did not include the Fredericson grade of stress injury. During their rehabilitation period, the patients refrained from sports activity but were allowed to continue cardiovascular training using an elliptical machine. The patients were followed periodically in the clinic and were allowed to return to sports activity only after they were pain free and had no tenderness over the tibia on physical examination. Six patients returned to the clinic within 2 weeks of resuming sports activity, with complaints of increasing pain in the same region of the tibia as their initial symptoms. These patients successfully returned to sports activity after an additional period of rest and rehabilitation. The time between the initial clinic visit and successful return to sports activity was documented in the 70 patients with clinical follow-up. Clinical follow-up was available in eight, 12, 24, four, and 22 patients with grades 1, 2, 3, 4a, and 4b stress injury, respectively.

Statistical Analysis

All statistical analyses were performed using the R programming environment (R Foundation of Statistical Imaging). Kruskal-Wallis tests were used to compare the location of the periosteal edema in the longitudinal and axial planes; the proportions of mild, moderate, and severe periosteal edema; the thickness of periosteal edema; the proportions of mild, moderate, and severe bone marrow edema; the length of bone marrow edema; and

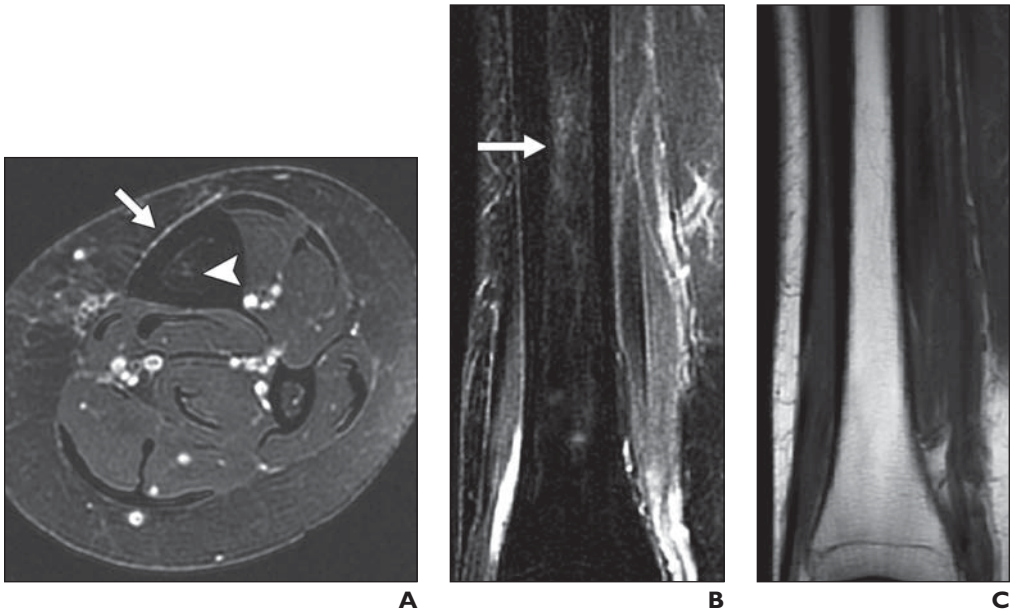

Fig. 2—21-year-old male soccer player with grade 2 tibial stress injury who successfully returned to sports activity 32 days after his initial clinic visit.
A, Axial fat-suppressed T2-weighted fast spin-echo image of calf shows mild periosteal edema (*arrow*) on medial cortex and mild bone marrow edema (*arrowhead*) within intramedullary canal of mid tibial diaphysis.
B, Corresponding sagittal fat-suppressed T2-weighted fast spin-echo image shows bone marrow edema (*arrow*) within intramedullary canal of mid tibial diaphysis.
C, Corresponding T1-weighted spin-echo image shows no bone marrow signal abnormality within intramedullary canal of mid tibial diaphysis.

Downloaded from www.ajronline.org by 66.69.39.220 on 11/19/23 from IP address 66.69.39.220. Copyright ARRS. For personal use only; all rights reserved

the mean time to return to sports activity for grades 1, 2, 3, 4a, and 4b tibial stress injuries. The Bonferroni method was used to adjust for the multiple statistical comparisons performed using the Kruskal-Wallis tests [6]. Thus, differences between grades of stress injury were considered to be statistically significant if the p value was less than 0.002. A univariate linear regression model was used to determine the ability of multiple variables to predict the time to return to sports activity including the age, sex, and sports activity of the patient, the Fredericson grade of stress injury, and the severity of periosteal and bone marrow edema on the MRI examination. The ability to predict the time to return to sports activity was assessed for both the Fredericson classification system and an abbreviated Fredericson classification system in which grades 2, 3, and 4a injuries were combined into a single category. Variables were considered to be statistically significant predictors of the time to return to sports activity if the p value was less than 0.05.

TABLE 2: Location of Periosteal Edema Associated With Tibial Stress Injuries in Axial Plane

Grade of Stress Injury	Location of Periosteal Edema			
	Anterior Cortex (%)	Posterior Cortex (%)	Medial Cortex (%)	Lateral Cortex (%)
1	6	3	91	0
2	0	48	52	0
3	6	23	71	0
4a	30	10	60	0
4b	6	75	19	0
All grades	6	35	59	0

Results

Location of Tibial Stress Injuries

There were 35 grade 1, 27 grade 2, 35 grade 3, seven grade 4a, and 38 grade 4b tibial stress injuries (Figs. 1–3). There were no statistically significant differences (p = 0.45–0.85) in the location of the periosteal edema for the different grades of stress injury in the longitudinal plane, with the mid tibial diaphysis being most commonly involved in all grades of injury. However, there was a statistically significant difference ($p < 0.003$) in the location of the periosteal edema for the different grades of stress injury in the axial plane. Periosteal edema most commonly involved the posterior tibial cortex for grade 4b stress injuries and the medial tibial cortex for the remaining grades of stress injury (Table 2). All multiple focal areas of signal abnormality in grade 4a stress injuries were located in the anterior and posterior tibial cortex (Fig. 4). Ten linear areas of signal abnormality in grade 4b stress injuries were located in the medial tibial cortex, whereas 28 linear areas of signal abnormality were located in the posterior tibial cortex (Fig. 5).

Grade of Tibial Stress Injury and Semiquantitative MRI Features of Injury Severity

Grade 1 stress injuries had a significantly higher proportion ($p < 0.002$) of mild periosteal edema and a significantly lower proportion ($p < 0.002$) of severe periosteal edema than grades 2, 3, 4a, and 4b stress injuries. Grade 4b stress injuries had a significantly lower proportion ($p < 0.002$) of mild periosteal edema and a significantly higher proportion ($p < 0.002$) of severe periosteal edema than grades 1, 2, 3, and 4a stress injuries. There was no statistically significant difference ($p = 0.06$) between grades 2, 3, and 4a stress injuries in the proportion of mild, moderate, and severe periosteal edema. Grade 4b stress injuries had significantly thicker periosteal edema ($p < 0.002$) than grades 1, 2, 3, and 4a stress injuries. There was no statistically significant difference (p = 0.11–0.79) between grades 1, 2, 3, and 4a stress injuries in thickness of periosteal edema.

Grade 4b stress injuries had a significantly lower proportion ($p < 0.002$) of mild bone marrow edema and a significantly higher proportion ($p < 0.002$) of severe bone marrow edema than grades 2, 3, and 4a stress injuries. There was no statistically significant difference ($p = 0.07$) between grades 2, 3, and 4a stress injuries in the proportion of mild, moderate, and severe bone marrow edema. Grade 4b stress injuries had a significantly longer length of bone marrow edema ($p < 0.002$) than grades 2, 3, and 4a stress

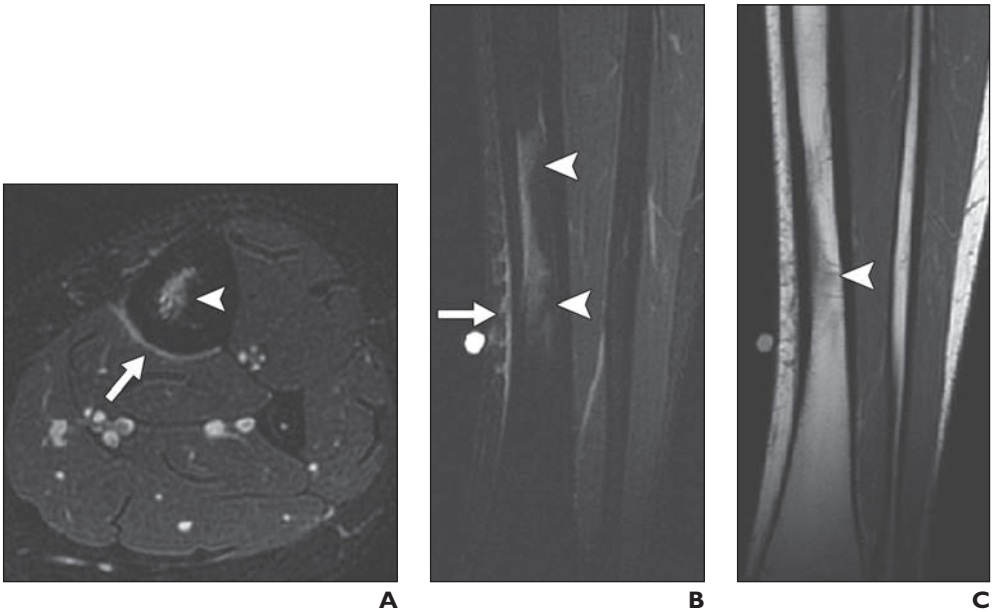

Fig. 3—23-year-old female long distance runner with grade 3 tibial stress injury who successfully returned to sports activity 45 days after her initial clinic visit.
A, Axial fat-suppressed T2-weighted fast spin-echo image of calf shows moderate periosteal edema (*arrow*) on medial and posterior cortex and moderate bone marrow edema (*arrowhead*) within intramedullary canal of mid tibial diaphysis.
B and **C,** Corresponding coronal fat-suppressed T2-weighted fast spin-echo (**B**) and T1-weighted spin-echo (**C**) images show bone marrow edema (*arrowheads*) within intramedullary canal and periosteal edema (*arrow,* **B**) on medial cortex of mid tibial diaphysis.

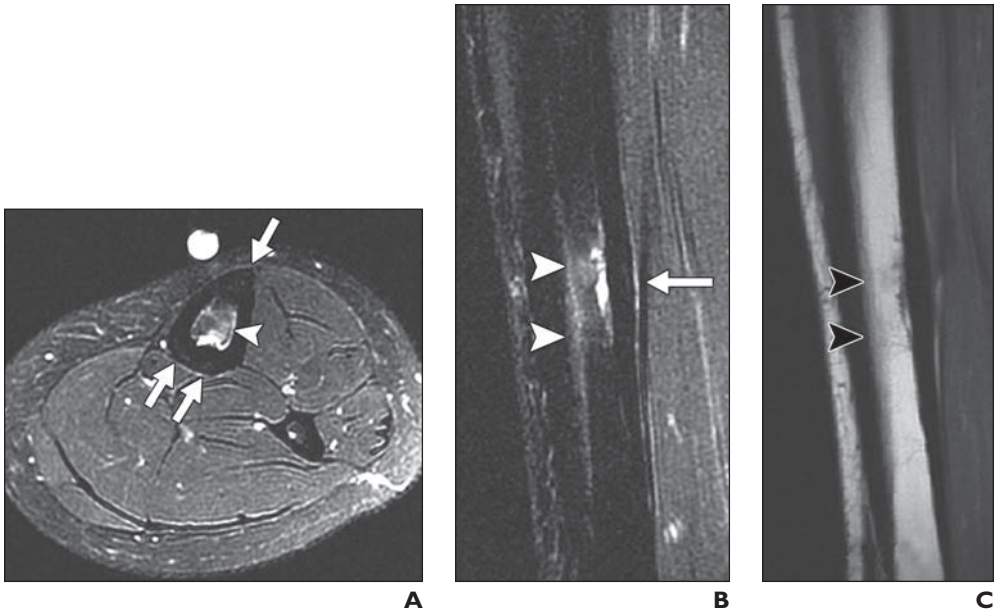

Fig. 4—14-year-old female long-distance runner with grade 4a tibial stress injury and multiple focal areas of intracortical signal abnormality who successfully returned to sports activity 51 days after her initial clinic visit.
A, Axial fat-suppressed T2-weighted fast spin-echo image of calf shows moderate bone marrow edema (*arrowhead*) within intramedullary canal and multiple focal areas of intermediate signal intensity (*arrows*) within anterior and posterior cortex of mid tibial diaphysis.
B and **C,** Corresponding sagittal fat-suppressed T2-weighted fast spin-echo (**B**) and T1-weighted spin-echo (**C**) images show bone marrow edema (*arrowheads*) within intramedullary canal and periosteal edema (*arrow*, **B**) on posterior cortex of mid tibial diaphysis.

injuries, whereas grade 3 stress injuries had a significantly longer length of bone marrow edema ($p < 0.003$) than grades 2 and 4a stress injuries. There was no statistically significant difference ($p = 0.6$) between grades 2 and 4a stress injuries in the length of bone marrow edema.

Grade of Tibial Stress Injury and Clinical Outcome

Patients with grade 1 stress injuries had a significantly shorter time to return to sports activity ($p < 0.002$) than patients with grades 2, 3, 4a, and 4b stress injuries, whereas patients with grade 4b stress injuries had a significantly longer time to return to sports activity ($p < 0.002$) than patients with grades 1, 2, 3, and 4a stress injuries. There was no statistically significant difference ($p = 0.60$) between patients with grades 2, 3, and 4a stress injuries in the time to return to sports activity (Table 3). The Fredericson grade of stress in-

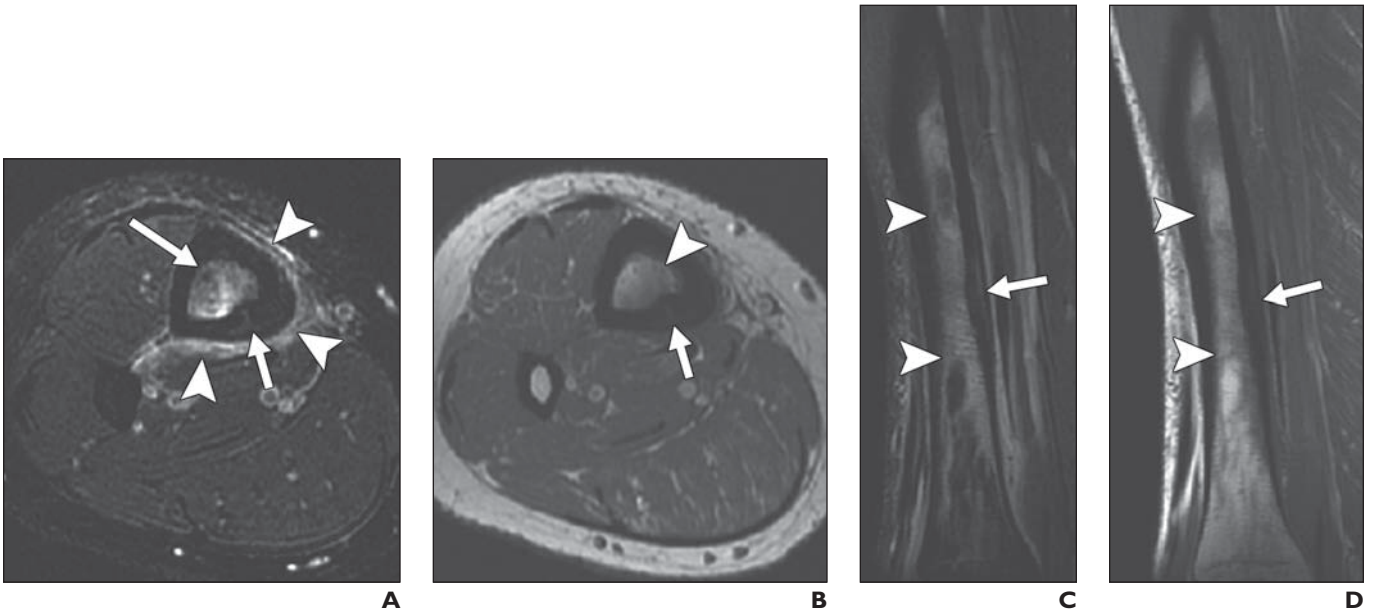

Fig. 5—17-year-old female long-distance runner with grade 4b tibial stress injury and linear areas of intracortical signal abnormality who successfully returned to sports activity 96 days after her initial clinic visit.
A, Axial fat-suppressed T2-weighted fast spin-echo image of calf shows severe bone marrow edema (*long arrow*) within intramedullary canal and linear areas of intermediate signal intensity (*short arrow*) within posterior cortex of mid tibial diaphysis. Also note severe periosteal edema (*arrowheads*) on medial, posterior, and lateral cortex of mid tibial diaphysis.
B, Corresponding axial T1-weighted spin-echo image shows bone marrow edema (*arrowhead*) within intramedullary canal and linear areas of intermediate signal intensity (*arrow*) within posterior cortex of mid tibial diaphysis.
C and **D,** Corresponding sagittal fat-suppressed T2-weighted fast spin-echo (**C**) and T1-weighted spin-echo (**D**) images show bone marrow edema (*arrowheads*) within intramedullary canal and linear areas of intermediate signal intensity (*arrows*) within posterior tibial cortex of mid tibial diaphysis.

Downloaded from www.ajronline.org by 66.69.39.220 on 11/19/23 from IP address 66.69.39.220. Copyright ARRS. For personal use only; all rights reserved

jury ($R^2 = 0.37$); the abbreviated Fredericson grade of stress injury ($R^2 = 0.42$); the proportions of mild, moderate, and severe periosteal edema ($R^2 = 0.33$); the thickness of periosteal edema ($R^2 = 0.25$); the proportions of mild, moderate, and severe bone marrow edema ($R^2 = 0.31$); and the length of bone marrow edema ($R^2 = 0.12$) were all significant predictors of the time to return to sports activity ($p < 0.05$). The age ($R^2 = 0.01$), sex ($R^2 = 0.01$), and sports activity ($R^2 = 0.08$) of the patient were not significant predictors of the time to return to sports activity ($p = 0.30–0.54$).

TABLE 3: Time to Return to Sports Activity for Patients With Each Fredericson Grade of Stress Injury

Grade of Stress Injury	Time to Return to Sports Activity			
	Time Range (d)	Median Time (d)	Mean Time (d)	SD (d)
1	3–20	20	15.6	9.2
2	14–65	43	39.4	12.8
3	18–90	46	48.4	19.7
4a	40–50	42	43.5	4.4
4b	30–157	64	70.6	33.2

Discussion

In 1995, Fredericson and associates [5] reviewed the MRI findings of 14 athletes with 18 tibial stress injuries and developed a classification system for stress injuries based on the presence of periosteal edema, bone marrow edema, and intracortical signal abnormality. The rationale behind the classification system was to create a standardized method to assess the severity of stress injuries that could assist clinicians in prescribing appropriate rehabilitation for patients with varying levels of injury [5]. Although commonly used to evaluate stress injuries on MRI, the Fredericson classification system has never been previously validated in a large patient population. Our study involving 138 patients with 142 tibial stress injuries has shown that the Fredericson grade of stress injury corresponds well with semiquantitative MR features of injury severity and the time to return to sports activity.

The results of our study raise questions regarding whether Fredericson grade 2 and 3 tibial stress injuries should be considered separately. In our study, there were no significant differences between patients with grades 2 and 3 stress injuries in the degree of periosteal and bone marrow edema and the time to return to sports activity. Fredericson and associates separated grades 2 and 3 stress injuries according to whether bone marrow edema could be visualized on T1-weighted images [5]. The rationale behind separating grades 2 and 3 stress injuries is that more severe bone marrow edema could be visualized on both T1-weighted and T2-weighted images, whereas less severe bone marrow edema could be visualized only on the more fluid-sensitive T2-weighted images. However, in our study, the T1-weighted and T2-weighted images were reviewed side-by-side on the MR workstation, which is also typically the case in clinical practice. For this reason, it may be somewhat subjective whether mild bone marrow edema visualized on T2-weighted images can also be subtly visualized on the corresponding T1-weighted images. Thus, it is quite likely that some tibial stress injuries in our study with only a mild amount of bone marrow edema were classified as grade 3 injuries because of the presence of subtle bone marrow signal abnormalities on the T1-weighted images.

The results of our study suggest that tibial stress injuries with multiple focal areas of intracortical signal abnormality should not be considered grade 4 injuries. Chronic repetitive stress to the tibia causes an imbalance between osteoclastic and osteoblastic activity, which ultimately weakens bone [7–9]. The multiple focal areas of intracortical signal abnormality seen in our patients with grade 4a stress injuries most likely represent a combination of osteopenia, cortical resorption cavities, and cortical striations that are manifestations of accelerated intracortical remodeling [2]. These intracortical abnormalities may not even be a source of pain and have been described in asymptomatic long-distance runners as well as patients with stress injuries [10]. Tibial stress injuries represent a spectrum of osseous abnormalities, with osteopenia, cortical resorption cavities, and cortical striations representing early intracortical lesions that may eventually progress to a cortical fracture. Thus, it is not surprising that patients in our study with grade 4a stress injuries and osteopenia, cortical resorption cavities, and cortical striations had significantly less severe periosteal and bone marrow edema and significantly shorter time to return to sports activity than patients with grade 4b stress injuries and fracture lines.

Multiple MRI variables in our study were found to be significant predictors of the time to return to sports activity in patients with tibial stress injuries. It is not surprising that the Fredericson grade of stress injury and various semiquantitative MRI features of injury severity were all able to predict the time to return to sports activity because these variables were strongly correlated with one another in our study. However, the abbreviated Fredericson grade of stress injury followed by the Fredericson grade of stress injury had the highest R^2, indicating the greatest ability to explain variations in the time to return to sports activity in our patient population. Thus, the Fredericson classification system may offer a convenient method to summarize multiple semiquantitative MRI features of injury severity and thereby predict the best time to return to sports in patients with tibial stress injuries.

In our study, periosteal edema most commonly involved the posterior tibial cortex for grade 4b stress injuries and the medial tibial cortex for the remaining grades of stress injury. Fredericson and associates [5] also found that periosteal edema most commonly involved the posterior medial tibial cortex at the origin of the tibialis posterior, flexor digitorum longus, and soleus muscles. However, the authors did not describe the location of the periosteal edema for each individual grade of stress injury. Most stress injuries involve the posterior medial tibial cortex, which is subjected to compressive forces during running because of posterior muscle contraction [5, 11, 12]. However, fracture lines are more common within the posterior tibial cortex than the medial tibial cortex, which accounted for the predominant posterior location of the periosteal edema for grade 4b stress injuries in our study.

To our knowledge, no previous study has compared the Fredericson grade of tibial stress injury with semiquantitative MRI features of injury severity. Yao and associates [13] did compare the Fredericson classification system with clinical outcome and found no significant correlation between the grade of injury and either the duration of symptoms or the time to return to sports activi-

Downloaded from www.ajronline.org by 66.69.39.220 on 11/19/23 from IP address 66.69.39.220. Copyright ARRS. For personal use only; all rights reserved

ty. However, their study included only 13 patients with tibial stress injuries and did show that the presence of a fracture line was a poor prognostic factor that was associated with a more than 4-month period of rehabilitation before a successful return to sports activity.

Our study has several limitations. One limitation was the retrospective design of our study. A second limitation was presence of selection bias. It is likely that some patients at out institution with clinical manifestations of tibial stress injuries who showed a periosteal reaction on radiographs or who had findings of stress injury on an outside MRI examination were treated for their injuries without being included in our study group. Another limitation of our study was that the MRI examinations were read in consensus and not independently by the two fellowship-trained musculoskeletal radiologists. However, previous studies have shown that MRI has excellent interobserver variability for evaluating tibial stress injuries [14]. The T1-weighted and T2-weighted images were also were reviewed side-by-side on the MR workstation, which may have created bias when distinguishing between grades 2 and 3 stress injuries. An additional limitation of our study was that the time to return to sports activity was documented in only a subset of patients in our study group. Furthermore, the sports medicine specialists had access to the MRI reports of all patients. Thus, the time an athlete returned to sports activity may have been influenced to some degree by the findings on the MRI examination.

In conclusion, our study has shown that the Fredericson classification system can be used to assess the severity of tibial stress injuries and thereby assist in the clinical management of the patient. In our study, the Fredericson grade of stress injury corresponded well with multiple semiquantitative MRI features of injury severity and the time to return to sports activity. However, the results of our study raise questions regarding whether grades 2 and 3 stress injuries should be considered separately and whether stress injuries with multiple focal areas of intracortical signal abnormality should be considered grade 4 injuries. That grades 2, 3, and 4a stress injuries had similar degrees of periosteal and bone marrow edema and similar time to return to sports activity suggests that these three grades could be combined into a single category. Thus, we propose an abbreviated Fredericson classification system for tibial stress injuries on the basis of the presence of periosteal edema only (grade 1), periosteal and bone marrow edema (grade 2), and a linear intracortical fracture line (grade 3). Additional prospective studies are needed to further validate the Fredericson and abbreviated Fredericson classification systems and to help determine the appropriate length of rehabilitation needed to treat athletes with each grade of stress injury.

References

1. Matheson GO, Clement DB, McKenzie DC, Taunton JE, Lloyd-Smith DR, MacIntyre JG. Stress fractures in athletes: a study of 320 cases. *Am J Sports Med* 1987; 15:46–58
2. Gaeta M, Minutoli F, Scribano E, et al. CT and MR imaging findings in athletes with early tibial stress injuries: comparison with bone scintigraphy findings and emphasis on cortical abnormalities. *Radiology* 2005; 235:553–561
3. Kiuru MJ, Pihlajamaki HK, Hietanen HJ, Ahovuo JA. MR imaging, bone scintigraphy, and radiography in bone stress injuries of the pelvis and the lower extremity. *Acta Radiol* 2002; 43:207–212
4. Kijowski R, Choi J, Mukharjee R, De Smet A. Significance of radiographic abnormalities in patients with tibial stress injuries: correlation with magnetic resonance imaging. *Skeletal Radiol* 2007; 36:633–640
5. Fredericson M, Bergman AG, Hoffman KL, Dillingham MS. Tibial stress reaction in runners: correlation of clinical symptoms and scintigraphy with a new magnetic resonance imaging grading system. *Am J Sports Med* 1995; 23:472–481
6. Bland JM, Altman DG. Multiple significance tests: the Bonferroni method. *BMJ* 1995; 310:170
7. Bhatt R, Lauder I, Finlay DB, Allen MJ, Belton IP. Correlation of bone scintigraphy and histological findings in medial tibial syndrome. *Br J Sports Med* 2000; 34:49–53
8. Burr DB, Martin RB, Schaffler MB, Radin EL. Bone remodeling in response to in vivo fatigue microdamage. *J Biomech* 1985; 18:189–200
9. Churches AE, Howlett CR. Functional adaptation of bone in response to sinusoidally varying controlled compressive loading of the ovine metacarpus. *Clin Orthop Relat Res* 1982; 168:265–280
10. Gaeta M, Minutoli F, Vinci S, et al. High-resolution CT grading of tibial stress reactions in distance runners. *AJR* 2006; 187:789–793
11. Zwas ST, Elkanovitch R, Frank G. Interpretation and classification of bone scintigraphic findings in stress fractures. *J Nucl Med* 1987; 28:452–457
12. Ammann W, Matheson GO. Radionuclide bone imaging in the detection of stress fractures. *Clin J Sport Med* 1991; 1:115–122
13. Yao L, Johnson C, Gentili A, Lee JK, Seeger LL. Stress injuries of bone: analysis of MR imaging staging criteria. *Acad Radiol* 1998; 5:34–40
14. Ahovuo JA, Kiuru MJ, Kinnunen JJ, Haapamaki V, Pihlajamaki HK. MR imaging of fatigue stress injuries to bones: intra- and interobserver agreement. *Magn Reson Imaging* 2002; 20:401–406

Downloaded from www.ajronline.org by 66.69.39.220 on 11/19/23 from IP address 66.69.39.220. Copyright ARRS. For personal use only; all rights reserved