Posterior Condylar Angle CT Measurement

Why?

this angle is helpful to the surgeons, allowing them to more accurately replicate proper mechanical alignment.

Brief Background on TKA Cuts

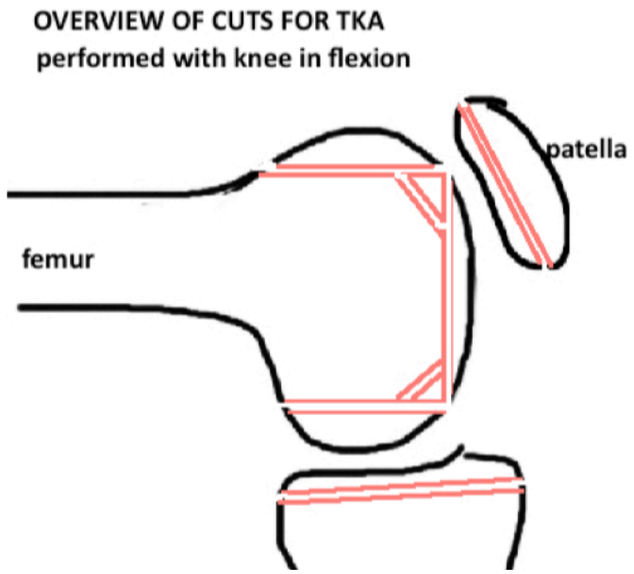

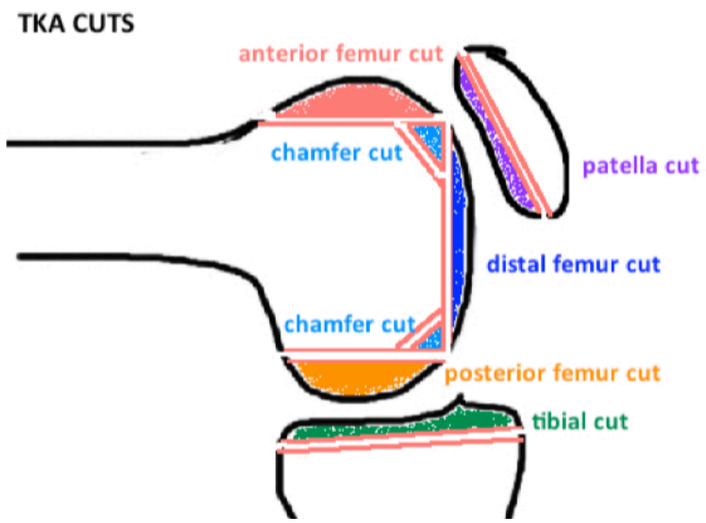

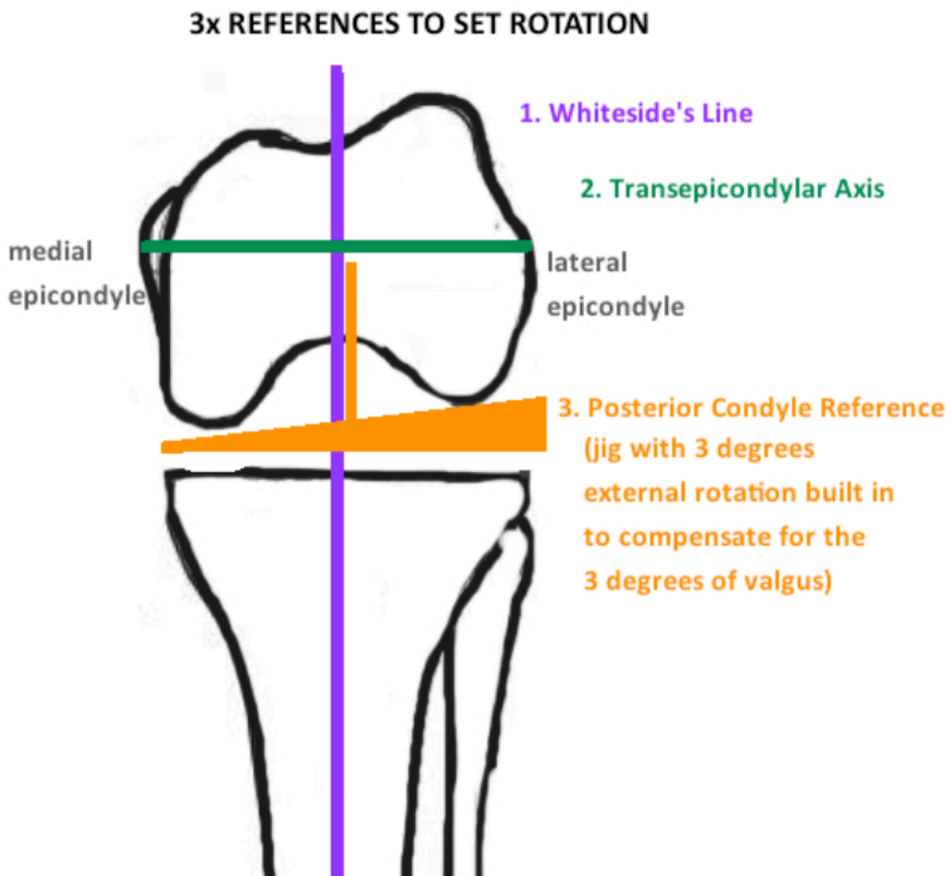

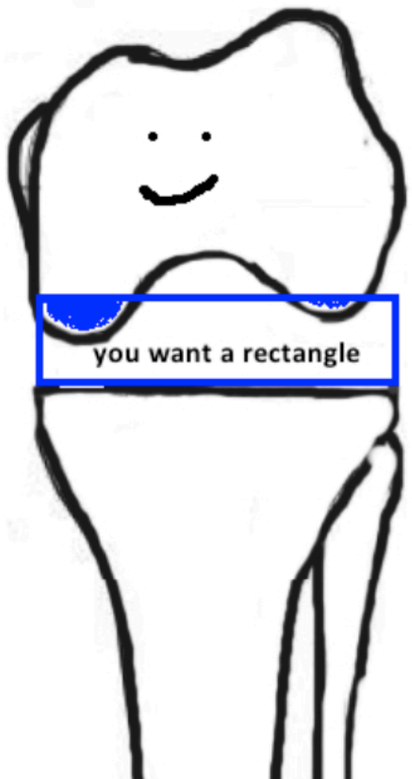

When making the posterior femoral condylar cuts, they want to try and achieve proper alignment. Normally cutting off more of the medial condyle relative to the lateral condyle using the standard 3 degree jig.

Posterior Condylar Angle CT Measurement

Show me!

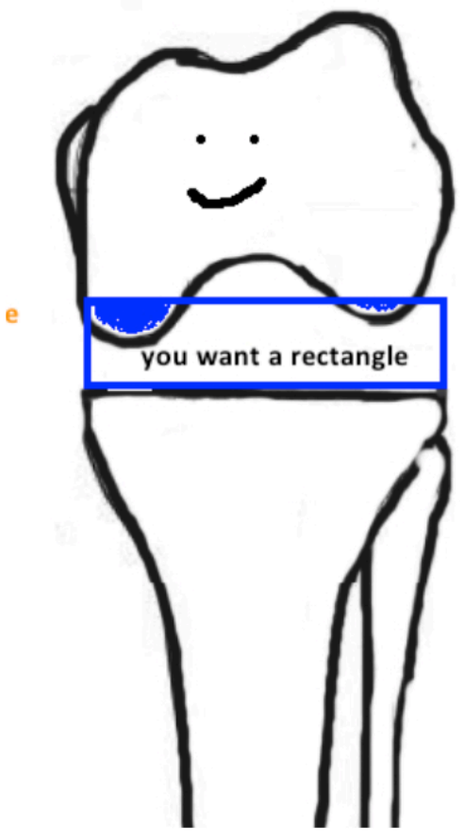

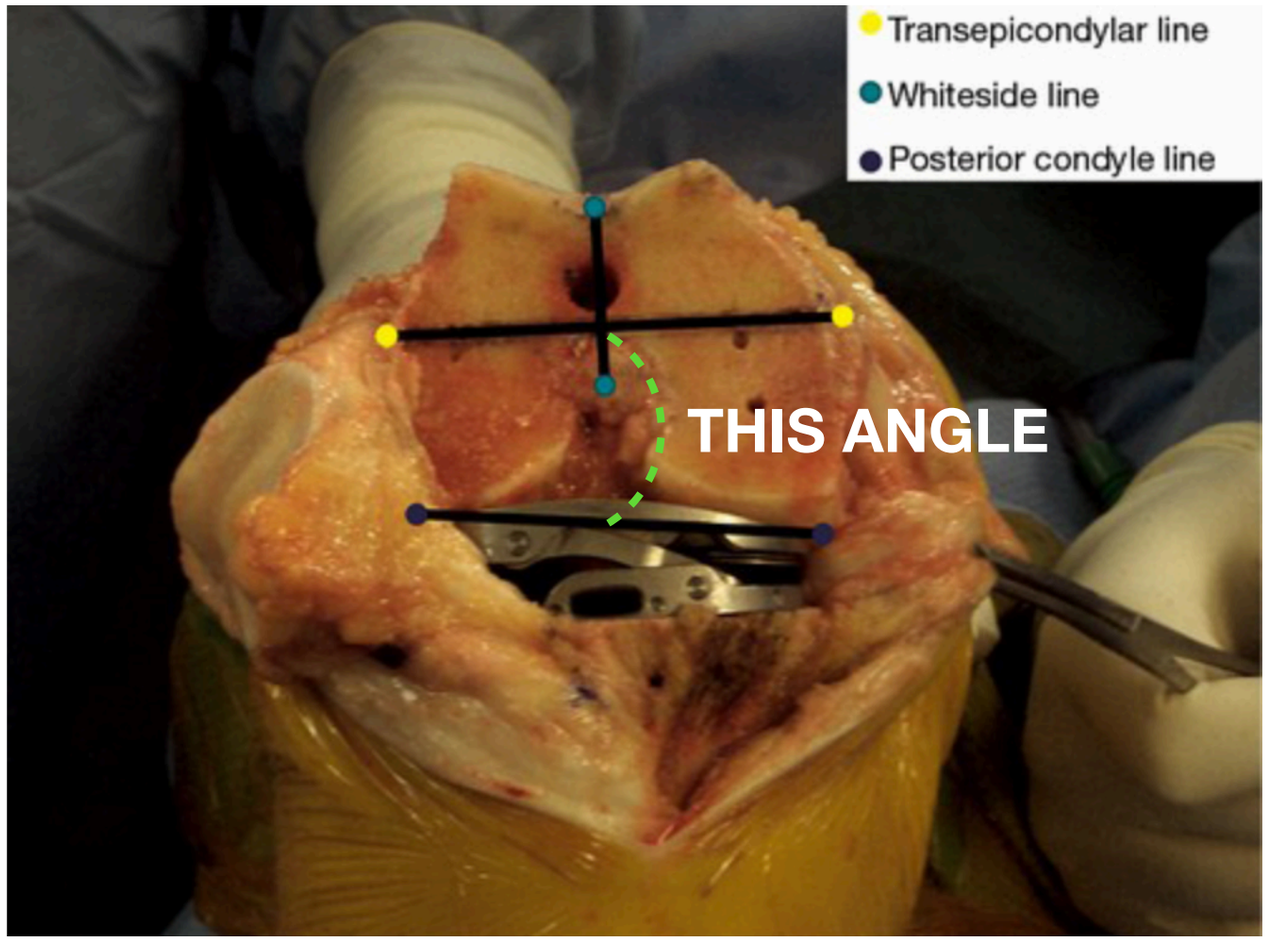

By providing them the angle between the transepicondylar axis and the posterior aspect of the femoral condyles - the theory is they can compensate for the patients natural varus/valgus alignment and more precisely mimic their natural alignment. That's why they are asking us to calculate and measure this angle.

Posterior Condylar Angle CT Measurement

What?

the “surgical” transepicondylar axis is a line drawn between to two femoral epicondyles.

Show me!

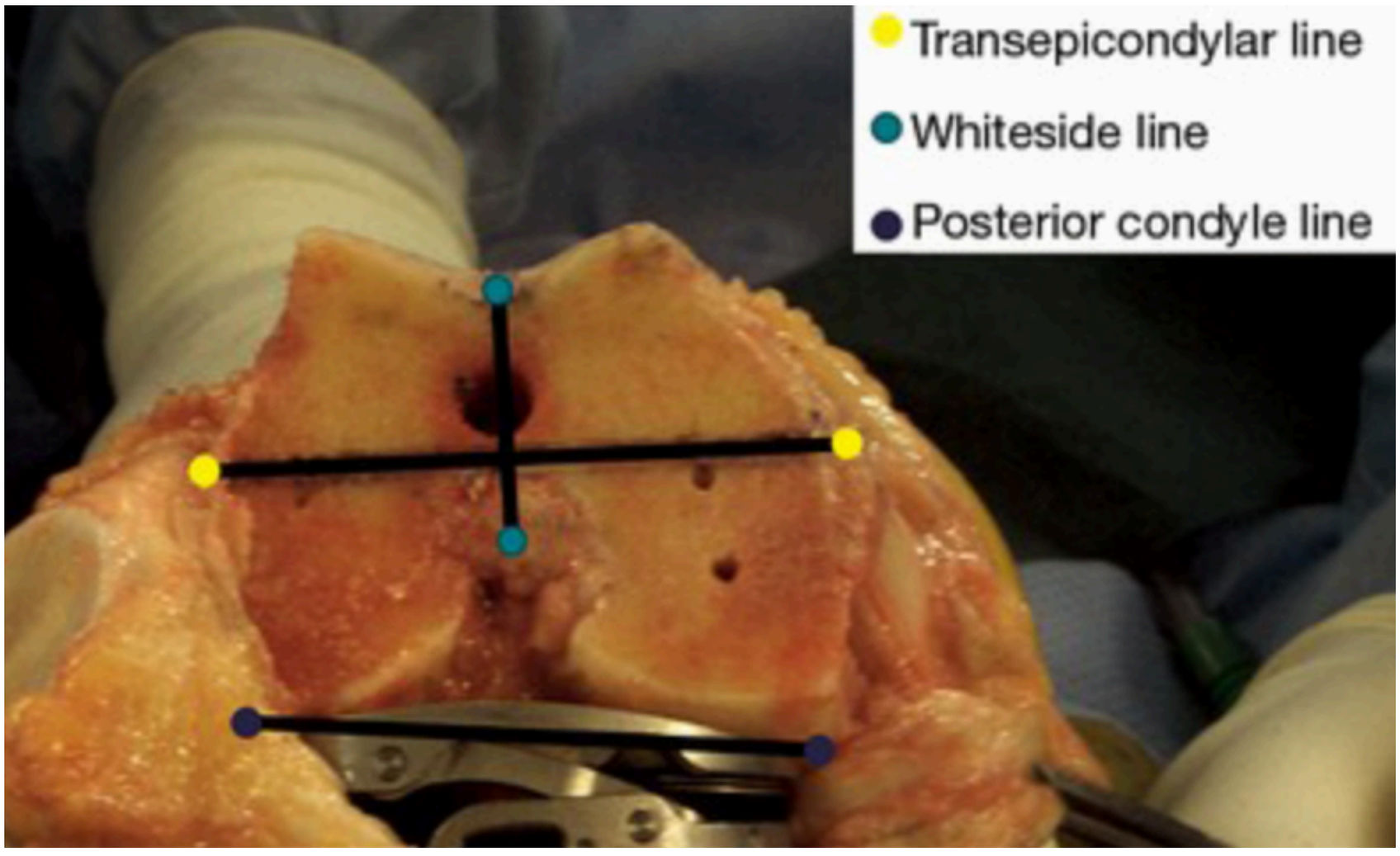

Yellow dots = surgical transepicondylar axis
Dark blue dots = posterior condyle axis

Posterior Condylar Angle CT Measurement

Show me
on CT!

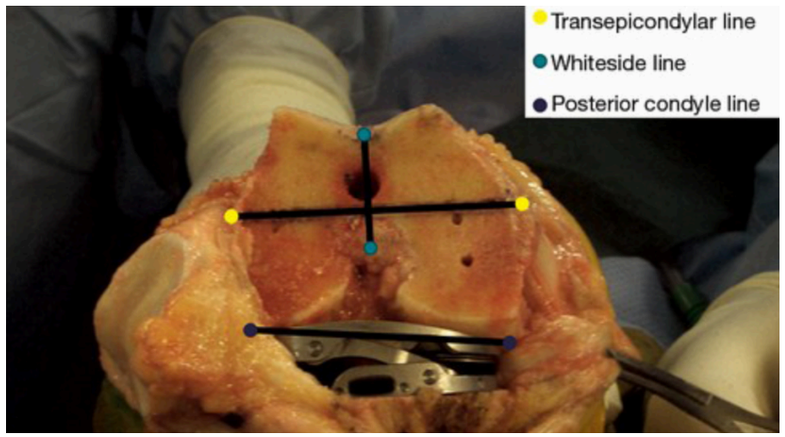

NOTICE: on the lateral side the epicondyle is the apex. BUT - on the medial side the "surgical" axis occurs at the nadir of a small dent, just posterior to the apex.

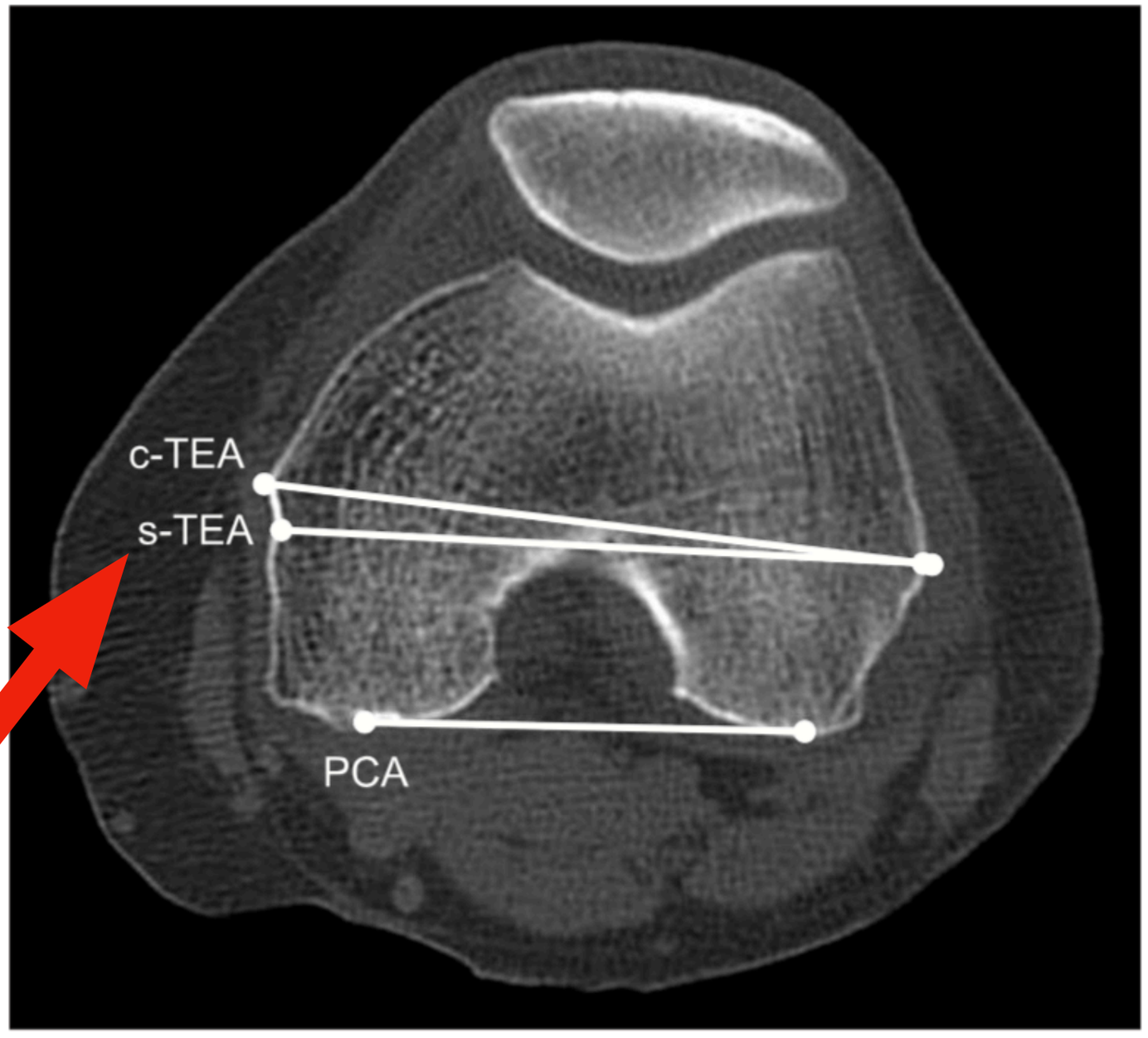

Figure 1. Computed tomography scan showing the transverse view of the distal femoral condyles. c-TEA, clinical transepicondylar axis; s-TEA, surgical transepicondylar axis; PCA, posterior condylar axis.

**** Ignore the C-TEA - it's only shown to make sure you measure the nadir behind it**

Posterior Condylar Angle CT Measurement

Summary

1. Scroll down to the axial image where you can see the apex of the lateral epicondyle.
2. Most of the time this slice is also the best slice for locating the S-TEA. If it isn't, hold you mouse in the location for the lateral apex and scroll until you find the medial epicondyle S-TEA nadir.
3. Using the Cobb angle tool, draw a line between the medial and lateral S-TEA
4. Then draw a line along the posterior condylar axis
5. The calculated angle will be the true S-TEA to PCA angle. This is the angle measurement they surgeons want to be reported.
6. Final step is to determine the rotation.
7. **If the angle opens medially that would infer that the posterior condyle's are internally rotated or "anteverted" in reference to the trans epicondylar axis.** Likewise if the angle opens laterally, that wouldn't for external rotation or "retroversion" of the posterior condyle's in relation to the trans epicondylar axis.

MOST COMMON!!

Posterior Condylar Angle CT Measurement

Example measurements:

Example A

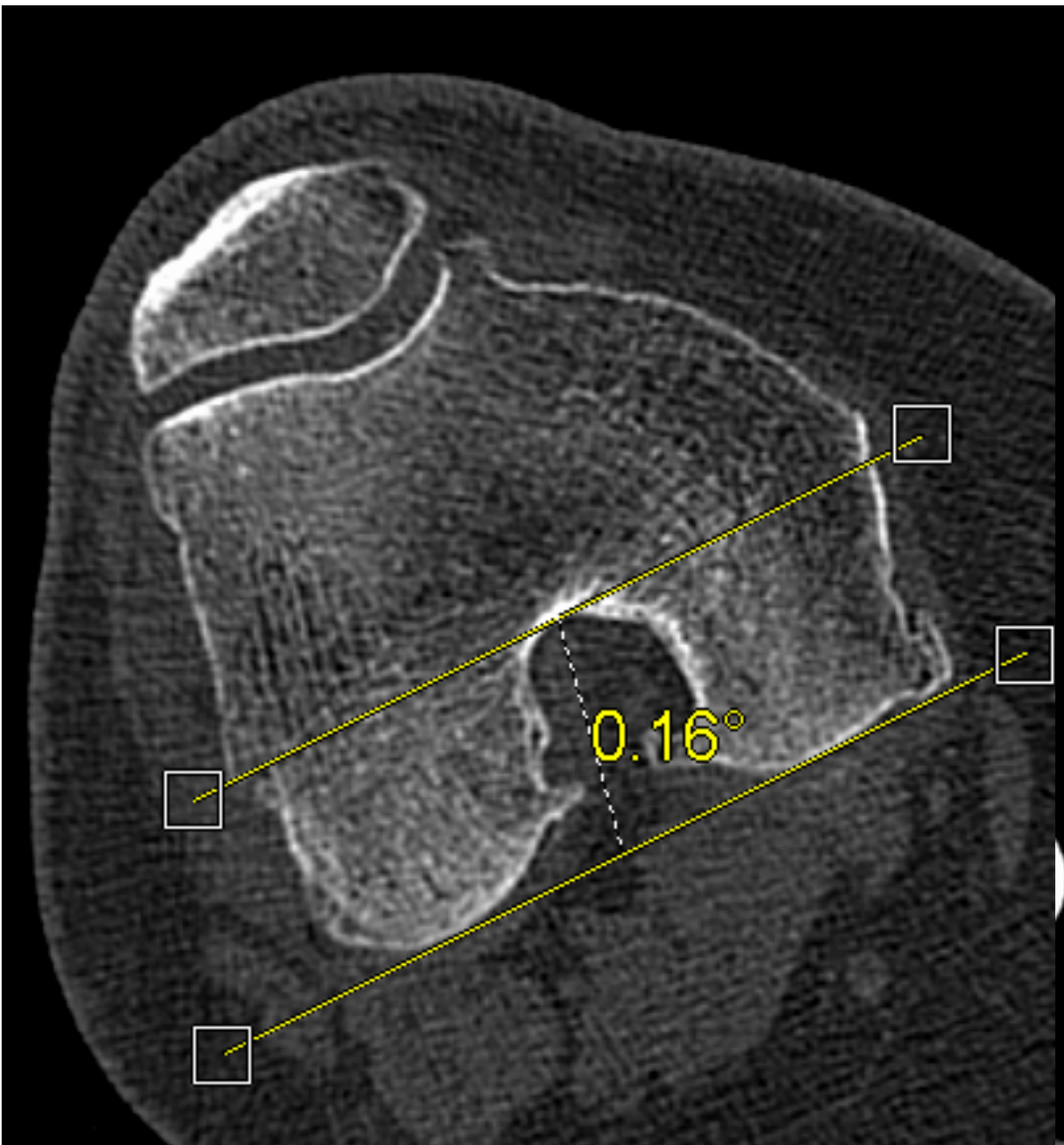

Example B

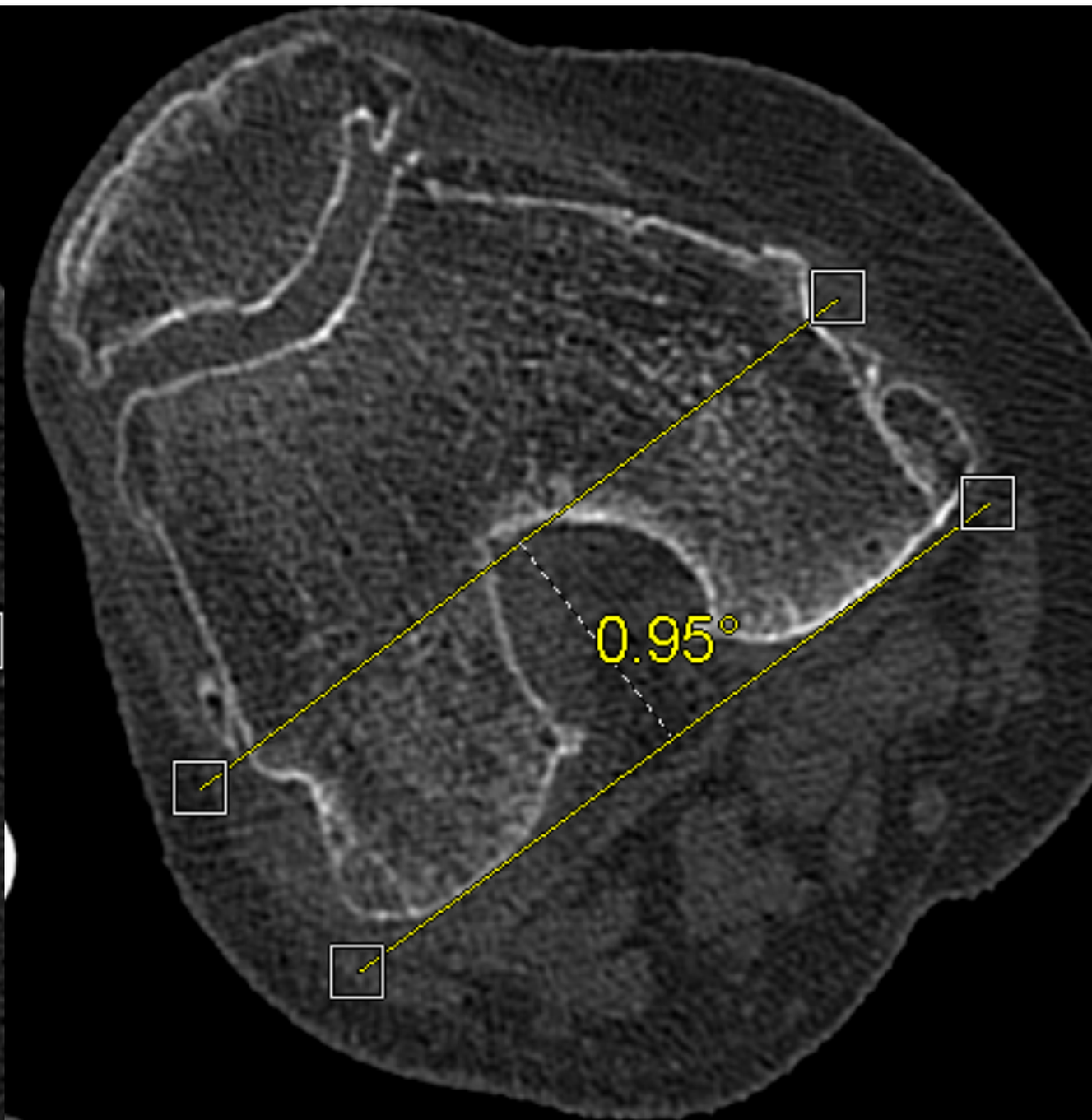

Posterior Condylar Angle CT Measurement

Example measurements:

Example C

Example C Sagittal Reference = posterior part of condyles

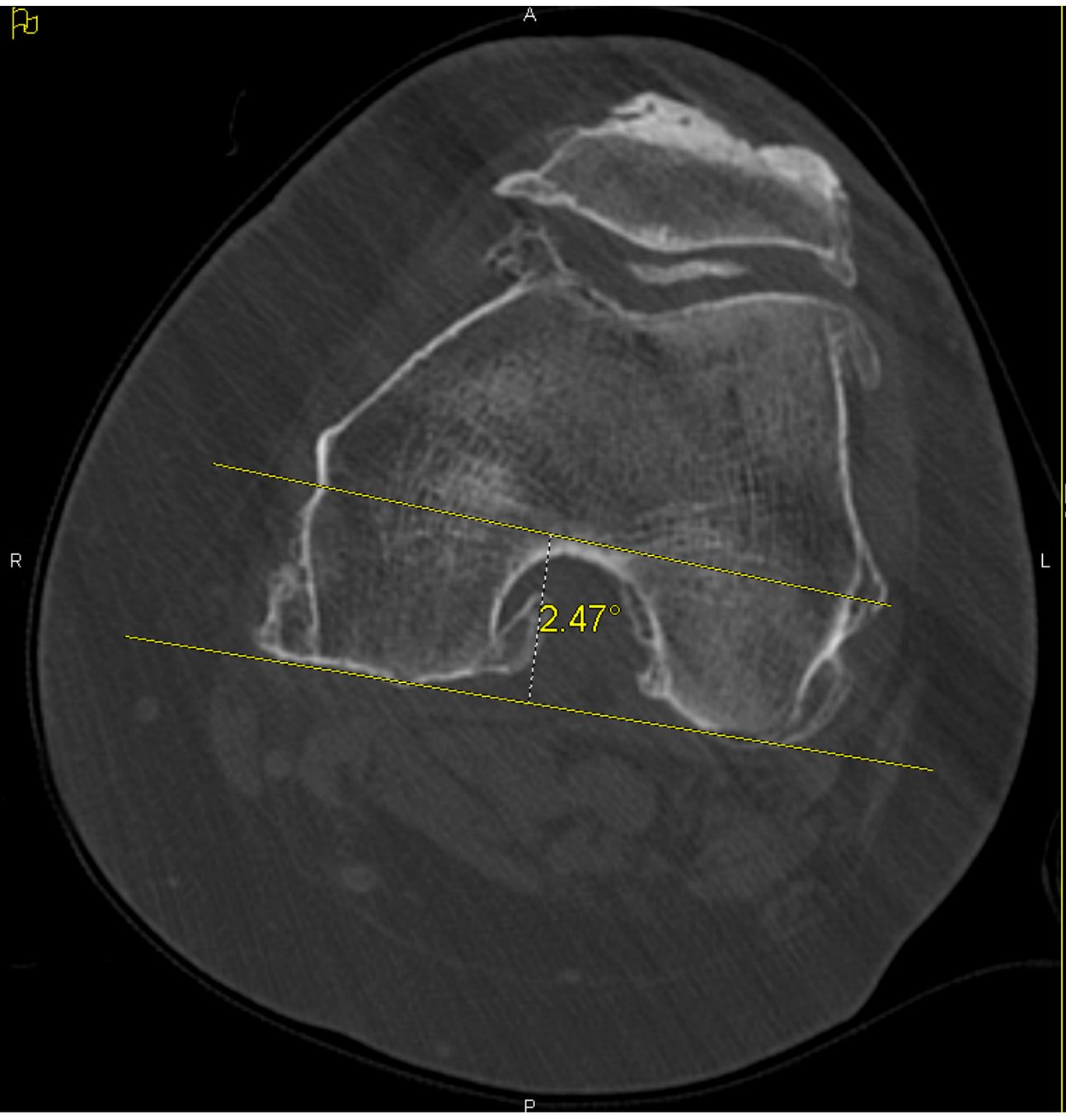



Posterior Condylar Angle CT Measurement

Example measurements:

Example C

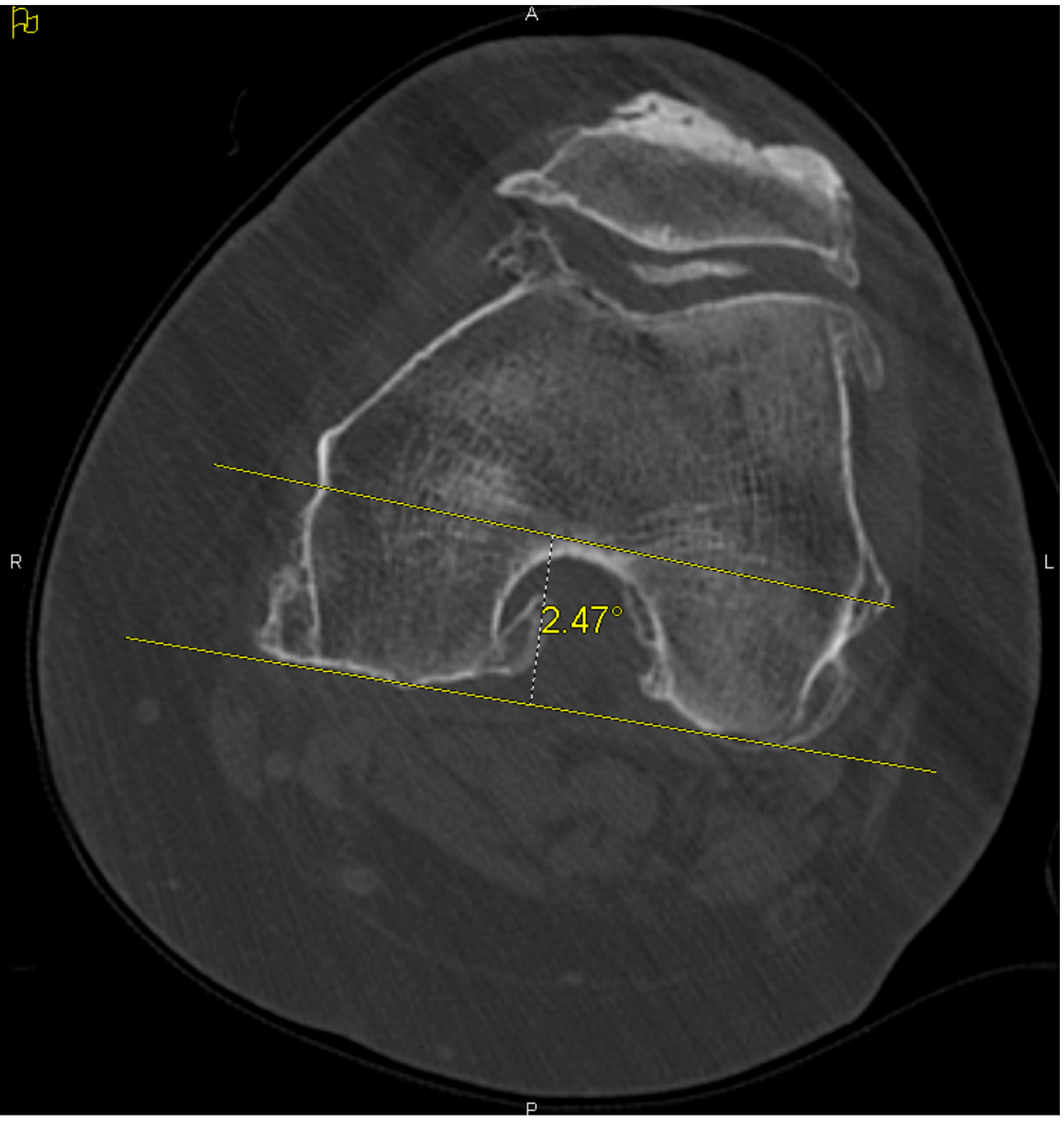

Report:

The posterior condylar angle is 2.5 degrees.

The angle opens medially, indicating the posterior femoral condyles are internally rotated (anteverted) relative to the epicondylar axis.