University of Washington Hospitals



Manual of Gastrointestinal and Genitourinary Radiology Procedures

(Revised July 2012)

Editors:

\

Neeraj Lalwani, M.D.
Charles A. Rohrmann, Jr., M.D.

Contributors:

Leila Bender, M.D.
Puneet Bhargava, M.D.
Carlos Cuevas, M.D.
Douglas Green,M.D.
Bruce Lehnert, M.D.
Mariam Moshiri, M.D.
Albert A. Moss, M.D.

DEDICATION

This manual is dedicated to the senior gastrointestinal and genitourinary radiologists who have contributed their expertise and resources toward creation of this manual:

William H. Bush, Jr., M.D.
Patrick C. Freeny, M.D.
Joel E. Lichtenstein, M.D.
James A. Nelson, M.D.
Sidney W. Nelson, M.D.
Scott J. Schulte, M.D.
Lee B. Talner, M.D.

And to the radiology residents at the University of Washington who we hope will find this manual to be of value in their training.

TABLE OF CONTENTS

Introduction 05

Guidelines for Radiology Residents 07

Don’ts in GI Radiology 11

Overview of Radiographic Contrast Agents 12

Patient Positions 15

Fluoroscopic Essentials for Radiology Residents 16

Gastrointestinal Procedures

Pharyngogram 19

Esophagram 23

Modifications of Pharyngogram and Esophagram:
- Pharyngoesophagram combined 27
- Pharyngoesophagram with marshmallow 27
- Pharyngogram or Pharyngoesophagram with Speech Specialist 27
- Esophagram for Achalasia 27
- Pharyngoesophagram for leak 28

Upper Gastrointestinal Series: 12 Essential Positions 29
Single Contrast Upper Gastrointestinal Series 32
Multiphasic Upper Gastrointestinal Series 35

Modifications of Upper Gastrointestinal Series:
- Upper Gastrointestinal Series for evaluation of gastric bypass 39
- Upper Gastrointestinal Series for evaluation of gastric band 43
- Upper Gastrointestinal Series for evaluation of fundoplication 47
- Tube check (PEG or PEJ) 49
- Upper Gastrointestinal Series with Small Bowel Follow Through 50

Small Intestine Contrast Examination 50

Barium Enema Single Contrast 52
Barium Enema Double Contrast 56

Modifications of Barium Enema:
Retrograde Ileostomy, Colostomy 60
Pouchogram 62

Tube Cholangiogram 63
Fistulagram, Sinogram 65
Essentials of feeding tube placement 66

Genitourinary Procedures

Cystogram 70
Loopogram 72
Voiding Cystourethrogram 73
Retrograde Urethrogram (RUG) 74
Pericatheter RUG 76

Appendices:

I. Preparation for Contrast Examinations:

Esophagram, Pharyngoesophagram,
Upper GI series (UGI), Small bowel series: (Outpatient) 78

Esophagram, Pharyngoesophagram,
Upper GI series (UGI), Small bowel series: (Inpatient) 79

Barium Enema: (Outpatient) 80
Barium Enema: (Inpatient) 81

II. Special considerations regarding Contrast Media:

Autonomic Dysreflexia during Cystography 82
Premedication Regimen 83
Treatment of Contrast Reactions 84
Extravasation of Contrast Medium 87
Contrast Reaction Report 88
Contrast Material (Information) 90
Indications for serum creatinine before IV contrast 91
Contrast media available at UWMC 92

INTRODUCTION

The objectives of the University of Washington Hospitals GI and GU Radiology fluoroscopy faculty and trainees include the provision of complete, safe, and accurate studies that answer specific clinical questions while minimizing patient radiation exposure, discomfort, and delay.

The Radiology Resident in Fluoroscopy

The *Guidelines* section of this manual provides suggestions for efficient and effective management of patient care duties and educational opportunities during the fluoroscopy rotation.

Pre-procedure duties:

- Review all available requests the day before and new ones in the morning.
- Find and examine all relevant prior studies and reports BEFORE starting the day's schedule. Be prepared to present the cases and planned imaging techniques to your attending before the first scheduled case of the morning.
- If needed, contact referring physicians to clarify the purpose of and/or indications for the examination.
- From the patient, obtain a focused history relative to your examination. Always ask about:
  1. Previous similar examinations and their results and prior surgery related to the region under study.
  2. Summarize your plan to your attending before starting.
  3. Patients should not leave the department before studies are checked for technical adequacy.
- Requests may be received for examinations that are unnecessary or inappropriate. In such instances the resident may modify the study after discussion with the attending radiologist. If a new, different, or an additional study is needed, the referring clinician must be contacted and an order for the new/additional examination needs to be entered.

Procedure and after procedure duties

- The referring physician should be notified at once of any critical or unexpected findings to assure appropriate and timely management.Communication with the referring provider should be documented in the examination report.
- Discuss the case with the attending radiologist and determine the important aspects of the examination to be summarized with the patient and referring clinician.
- For outpatients who will proceed to a clinic appointment the same day, please phone results to the clinician prior to their clinic visit.
- Formulate a succinct and meaningful report for rapid signature by your attending.

Ideal vs. tailored examinations

Although there are many variations of fluoroscopic approach and technique, this manual has as its primary objective to provide established and ideal methods of efficient evaluation for specific or general patient complaints.

The procedures described in this manual involve the multiple steps of ideal examinations. Trainees should become accomplished in performing all components of high quality examinations that are detailed in this manual. Although radiologists must be experts at performing the complete examinations as described, tailoring and planning an examination to address the patient's needs is of the most value. These modifications should be justifiable and should not compromise the study.

Guidelines for Radiology Residents on University of Washington GI/GU/Fluoroscopy Services

Please refer to the Department website for General Guidelines

Hours:

Your day starts at 7:30 with the morning conference. If there is no conference, prepare for the day's cases and/or work in the teaching files. Cases start at 8:30 on most days. We try to end the case schedule by 5:00. We will continue until your cases are completed.

Attire:

You will have daily patient contact. Be professional always: White coat and name tag are required. Scrubs may be worn.

Responsibility and Supervision:

Your attending will expect you to exhibit responsibility for running the service, and the attending will act in supervisory and advisory capacities. You are expected to develop skills that allow management of the service and its workflow.

Rely on your technologists and patient care coordinators to help with administrative and technical issues. Treat them as the professionals and colleagues they are.

You will be expected to do all cases for which you are qualified. Since the number of fluoroscopy cases available for training is limited, it is therefore important that each examination be used as a valuable learning experience.

In addition to performing the fluoroscopy procedures and communicating results, please assist with ER reads at UWMC, phone and in-person consultations, and support the technologists in their duties.

Use the dictation templates and voice recognition programs to your advantage. Typing reports can delay completion of your day's work.

Communication:

Phone and in-person consultations should be done concisely and accurately. Please be respectful of the clinician's time and present to them only relevant information. Practice your concise communication skills, if needed.

Please follow the department's *Critical Results Reporting Guidelines.*
Compose, sign, and convey reports to your attending expeditiously.
When using report macros, proof them carefully to be sure they accurately reflect the examination being reported.

Your Education:

The art and science of fluoroscopy are best learned by doing cases. This manual is your primary educational resource for this rotation. You are expected to be very familiar with its content and be able to safely perform the procedures included.

You will be expected to understand the radiologic physics of fluoroscopic image production and radiation safety. Please refer to the Radiology Department website and seminar instruction of Dr. Kalpana Kanal and follow the *Fluoroscopic Essentials* on page 12 of this ***Manual***.

Additional knowledge required in the understanding the radiology of gastrointestinal and genitourinary disease can be acquired using the other resources available within UW radiology. There are extensive slide sets and teaching files on the UW Radiology Web Sites and in the hospitals' PACSs.

GI and GU teaching power points can be found on the educational resources web-page. This web page can be found as follows:

Radiology Home ➔ Academic Radiology➔ Residency➔ Current Residents➔ Educational Resources ➔ Lecture Library

Or visit the following short cut:

https://www.rad.washington.edu/academics/residency/currentres/education-resources/pptlectures

Reading suggestions are contained in this ***Manual*** and on the UW Radiology Web Site. Additional GI/GU radiology reading suggestions are in the Textbook of Gastrointestinal Radiology by Gore and Levine and in the Textbook of Genitourinary Radiology by Dunnick, et al.

PACS Teaching File: The UWMC GI PACS file contains over 950 teaching cases that have been selected from more than 2000 film cases acquired over 50 years by prior and current UW residents and faculty. To access these teaching files in UWMC PACS go to: *Utilities; Academic Folders; CR TF (Abdomen, etc)*. The files can be entered into your PACS preference list for efficient access. The cases may be accessed directly using the case's accession number found in the GI PACS file case log book in each reading room.

For UWMC assigned residents, please dictate *at least* one case in the PACS GI Teaching File each week. Use the standard teaching file categories: *History, Findings, Differential Diagnosis, Diagnosis, Discussion, and References.* Please review and discuss these with your attending. They will then be signed and become a permanent part of the PACS record with your name as author. The cases can be entered in your radiology residency educational portfolio as an educational product.

For HMC assigned residents, please develop a word document case report of one of the un-dictated plain abdomen cases in the UW PACS teaching file using the format

described above. These will be scanned into the UW PACS file and can also be entered in your radiology residency educational portfolio as an educational product.

Conferences:

You are expected to attend morning, noon, and Thursday afternoon conferences. Plan your work day with your attending to allow punctual attendance.

Medical Students:

Frequently there will be medical students on elective with your service. You will be their supervisor and mentor. Engage and involve them in your work. Teach them about the cases you see together. They may be your future colleagues. It is often an experience with a radiology resident that influences a student's career choice.

If a medical student radiology elective course occurs during your month on the fluoroscopy services (August, September, October, January, February, March), you will have the opportunity to present a case conference to them. These power point case conferences are on the department web site. Ask your attending to preview the cases with you. It is wise to go through all of the case sets as a good learning opportunity. The case conferences you present can also be entered in your educational portfolio as an educational product.

Evaluations and Examinations:

You will be evaluated based on performance in each of the six ACGME core competencies. Contribution of the case reports into the PACS teaching file is required for a satisfactory performance evaluation.

Residents are evaluated based on expected performance at their level of training. A grade "3" reflects performance at the expected level. Grades "4" or "5" indicate exceptional performance for the degree of resident experience at the time of the rotation. Grades "1" or "2" reflect performance at a less than expected level.

You are required to evaluate your attending and the rotation. The evaluations are anonymous and the supervising attendings do not receive them for several months after they are entered in order to encourage candid and complete responses. Suggestions for improvement are welcomed. If you have acute concerns, discuss them with your attending, chief resident, and/or program director immediately.

The UW in-training examinations will include examples of gastrointestinal and genitourinary pathology represented in the PACS teaching files. Independent and group study of these cases is advised. These files are also useful as a resource for ABR preparation.

Absences:

On the first day of the rotation, remind your attending of the days you have planned professional leave or vacation.

If you are ill, phone the residency program coordinator. Confirm that they will contact the float resident for coverage and inform your attending of your absence and when you expect to return.

“Do nots” in GI Radiology

- Do not perform a study in any female patient of child-bearing age unless pregnancy is ruled out.

- Do not perform a barium contrast study on a patient with suspected perforation or leak. Low-osmolar iodinated contrast (e.g., Omnipaque) should be used in these situations. Medium density barium contrast can be used if no leak is evident with water soluble contrast. This will further enhance the confidence of the diagnosis.

- Do not use barium contrast by mouth or per rectum in a patient who has or may have a colonic obstruction. This may inspissate and aggravate the obstruction. Water soluble contrast should be used instead of barium in such cases. Barium contrast is appropriate in evaluation of gastric or small intestine obstruction, however.

- Do not allow a moribund patient to leave the fluoroscopy room with contrast material in their stomach. Aspiration of gastric contrast material is the most common cause of death caused by fluoroscopic GI examinations.

- Do not perform a barium enema in a patient:

    1. With fulminant colitis or toxic colon
    2. Who had a polypectomy in last 7 days
    3. Who had rectal or colonic biopsy through a fiberoptic endoscope in last 48hrs or through a rigid proctoscope or sigmoidoscope in last 7 days Exception: Pathology report confirms that the biopsy did not penetrate the muscularis propria.

- Do not inflate the balloon of the catheter inside the stoma when performing retrograde ileostomy, colostomy, or loopogram.

- Do not use the standard balloon tip rectal tube when performing a pouchogram. Use the small flexible tip tube or Foley-type balloon catheter.

OVERVIEW OF RADIOGRAPHIC CONTRAST MEDIA

A wide variety of products is available and usage differs among institutions. Unfortunately, labeling is not well standardized or consistent.

GI contrast agents are broadly classified in two categories: Barium sulfate-based and iodine-based.

Barium Sulfate Contrast Media:

Barium sulfate media are particulate suspensions. The concentration may be specified as the ratio of weight of barium to volume of suspension (W/V) or, less commonly, as the ratio of weight of barium to weight of final suspension (W/W).

For historical reasons these are expressed as percentages. The percentages are similar for dilute suspensions but diverge at high concentrations.

Four ranges of Barium sulfate concentrations are in common use with variations for special purposes:

- Dilute (20-25% wt/vol), (or “thin”) is used for single contrast enemas and retrograde small bowel studies.
- Dense (85-100% W/V), (or “thick”) is for double contrast enemas.
- Regular or medium density (60-65% W/V) is used for single contrast esophagrams, UGI’s and small intestine examinations.
- High density (225-250% W/V) is also often called “thick” but only minimally more viscous than “dense” barium is used for double contrast esophagrams and UGI’s.

Pros of barium sulfate contrast media:

1. Excellent coating, demonstrating normal and abnormal mucosal patterns.
2. Cost

Cons of barium sulfate contrast media:

1. High morbidity associated with barium leak in peritoneal cavity or mediastinum.
2. Subsequent CT examinations are rendered difficult to interpret if barium remains. Ideally, patient should wait till barium has cleared.

What if barium contrast escapes in peritoneal cavity or mediastinum?

This is extremely serious condition. Escape in peritoneal cavity will incite an inflammatory response, severe hypovolemia, and pain. Treatment consists of IV fluid, steroids and antibiotics. Surgical cleansing of the peritoneum may be required. Despite timely treatment still there will be a high (up to 50%) mortality rate. Survivors will develop peritoneal adhesions and granulomas. Escape into the mediastinum also has a high mortality rate. Therefore, always use water soluble contrast where there is a suspected leak or perforation.

What if barium contrast is aspirated?

Barium contrast aspiration is usually harmless, but outcome may be complicated by inflammation, pneumonitis and/or granuloma formation in a patient with underlying lung disease. Aspiration of water soluble contrast, however, may lead to pulmonary edema. This complication is much less common with low osmolar contrast media.

Use of barium tablets and marshmallows in pharyngoesophagography

Barium tablets measure approximately 13mm, and are used to delineate area of focal narrowing and Schatzki rings. We generally prefer to use a small marshmallow of similar size as the marshmallow will dissolve rapidly if impacted at a site of narrowing.

Iodinated, water soluble contrast media:

Iodinated, water soluble contrast media are divided in two categories: High osmolality contrast media (HOCM) and low osmolality contrast media (LOCM). HOCM are always ionic, while LOCM include both ionic and nonionic compounds.

These media are specified by the concentration of organically bound iodine, but are often labeled with the concentration of the complex molecule which is commonly about twice the percentage of the iodine content.

Remember, that 1-2% of oral contrast is absorbed through intestine and can lead to allergic reactions. Therefore, ask about the allergic history before giving iodine contrast. Most adverse reactions to enteric iodine contrast agents are mild and transitory and usually confined to nausea and vomiting. Patients with a history of prior moderate (Brady/tachycardia or hypotension, diffuse erythema, dyspnea, bronchospasm, wheezing, laryngeal edema) to severe (progressive laryngeal edema, unresponsiveness, cardiopulmonary arrest, convulsions, profound hypotension, and arrhythmias) reaction to IV iodine contrast should receive premedication.

On emergent basis, iodine contrast could be administered if the benefits outweigh the risks of the procedure, even without premedication. However, this should be discussed with the referring physician and the patient and should be documented in the patient's chart. Anaphylaxis with oral contrast is rare but some cases have been reported in the literature. Patients with the history of anaphylactic reaction to contrast material should not receive IV or water soluble oral contrast unless premedicated.

Gastrografin is a trade name of a flavored HOCM prepared for oral/enteric use and is not suitable for parenteral injection. This medium is not used at our institutions.
We prefer to use LOCM (Omnipaque) in all studies, where intestinal leak is suspected. This does not have the risk of pulmonary edema or hypovolemia of the high osmolar media.

REFERENCE:

1. Skucas J, ***Imaging Contrast Agents*** **and** ***Pharmacoradiology*** in, Textbook of Gastrointestinal Radiology; Gore RM and Levine MC ; 3rd edition, 2007, Saunders, Chapters 1and 2.

PATIENT POSITION:

NOTE! In the following discussions, patient positioning is indicated relative to the TOP of the fluoroscopy table.

Supine: AP = on back
Prone: PA = on belly
Supine obliquities: LPO = left posterior oblique
RPO = right posterior oblique
Prone obliquities: LAO = left anterior oblique
RAO = right anterior oblique
Lateral: LL = left side down lateral
RL = right side down lateral

FLUOROSCOPIC ESSENTIALS FOR RADIOLOGY RESIDENTS

Protection:

- For yourself: Apron or a collar that fits-no gaps. Badge on collar and lead glove for hand in the primary beam
- For patients: Wrap around skirt for patients less than 50 years
- For technologists, nurses and others: Be sure everyone in the room is protected before you activate the fluoroscope
- Lead drapes on the image intensifier tower
- Tower close to patient; visual sighting for distance and centering
- Collimation/Cone in
- Pulsed fluoroscopy
- Minimize time of fluoroscopy:
- ***NEVER*** have the fluoroscope on when you are not using it
- Use grid sparingly
- Shield yourself with the tower and lead drapes

Gloves:

- Nitrile gloves for all examinations
- Remove gloves before leaving room

Fluoroscopist's body position:

- Left foot on the pedal
- Right foot on the floor for standing and balance
- Left hand on the tower
- Right hand for the patient
- Eyes on the monitor

Contrast Media:
Always confirm

Directions to Patient:

- Clear, calm instructions: "Turn away from (towards) me", "swallow the barium (contrast)", etc
- The 1-2-3 of spot filming: 1:"stop breathing"-2:*Spot film-3:*"breathe"

Reporting Efficiencies:

- Use Macros
- When telephoning, always call or answer with your name and location, for example: "This is Dr._____, GI Radiology. . ."

REFERENCES:

1. Ott DJ, ***Barium Studies: Single Contrast*** in, Textbook of Gastrointestinal Radiology; Gore RM and Levine MS ; 3rd edition, 2007, Saunders, Chapter 3.

2. Laufer I and Levine MS, ***Barium Studies: Principles of Double-Contrast Diagnosis*** in, Textbook of Gastrointestinal Radiology; Gore RM and Levine MS ; 3rd edition, 2007, Saunders, Chapter 4.

GI Procedures

PHARYNGOGRAM

INDICATIONS:

For anatomic and physiologic evaluation of the pharynx

CONTRAINDICATIONS:

Use water soluble contrast if there is concern of leak or recent oro-pharyngeal or laryngeal surgery. See pharyngoesophagram for leak, page-28.

PREPARATION:

NPO after midnight (no smoking or chewing gum)

MATERIALS:

300 cc 60% w/v barium suspension

PREPROCEDURE POINTS:

There is no preliminary image for a pharyngogram.

TECHNIQUE FOR RADIOLOGISTS:

Full column evaluation of the pharynx:

Standing or sitting right lateral:

1. Have the patient hold one mouthful of barium, center at the pharynx and video record one swallow.
2. Have the patient hold one mouthful of barium, center at the pharynx and take spot images at **4 per second** during swallowing. Be sure to activate the camera before telling the patient to swallow by using the “1-2-3-swallow” count and activate camera on “2”.

Observe the patient's ability to maintain the bolus in the oral cavity, dribbling, or hesitancy in initiating a swallow, and passage of the bolus into the oropharynx. This process is oropharyngeal transfer and proceeds as follows:

- The tongue actively compresses the bolus against the hard palate forcing it posteriorly.

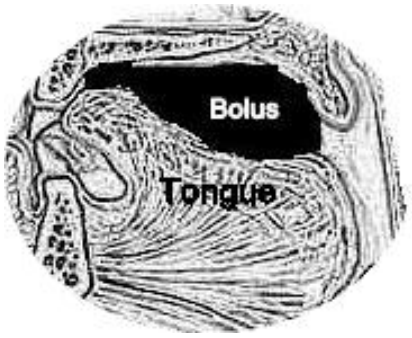

- The soft palate is elevated superiorly and posteriorly to appose Passavant's cushion to prevent nasopharyngeal regurgitation.

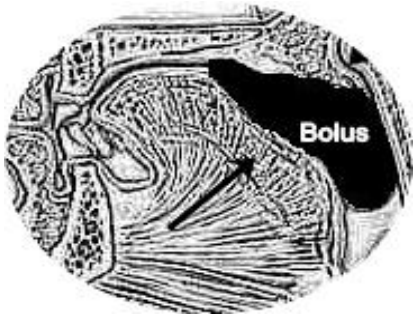

- The larynx is elevated and the hypopharynx is narrowed by the action of the pharyngeal constrictors.

- The epiglottis tilts dorsally and then downward to prevent aspiration.

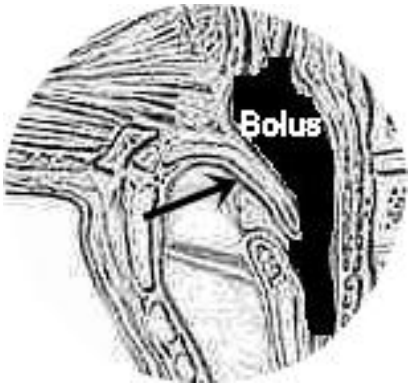

- As the barium bolus touches the posterior pharyngeal wall, the cricopharyngeus muscle relaxes.
- Following bolus passage, the cricopharyngeus muscle constricts initiating the primary esophageal peristaltic wave.

Standing right lateral:

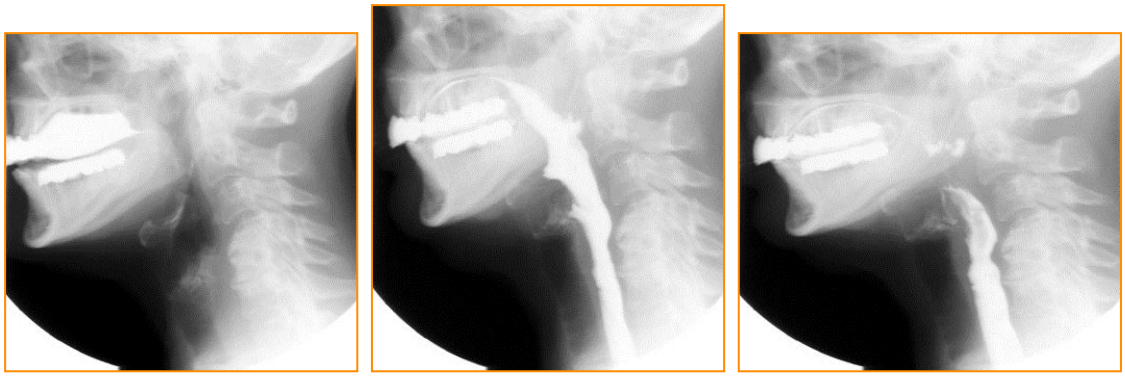

Standing AP:

Repeat the above described steps in right lateral

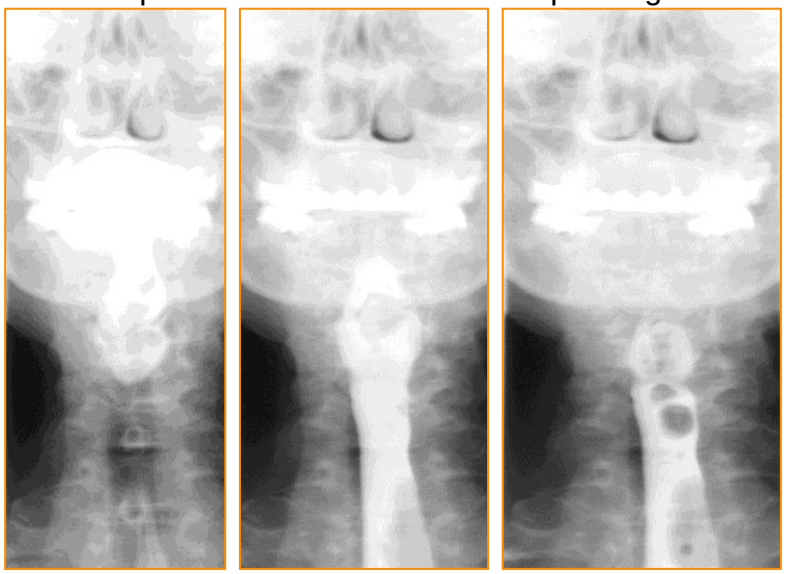

TECHNIQUE FOR TECHNOLOGISTS:
No preliminary image

Air contrast evaluation of the pharynx:

Standing right lateral:

1. Have the patient hold a moderate sized mouthful of high density barium and center the fluoroscope at the pharynx. The palate and shoulder area should be at the superior and inferior aspects of the field, respectively.

2. Have the patient gargle and swallow the barium. During prolonged "eee" phonation and inspiration, take spot images. “Trumpeter’s” maneuver may also be used.

AP projection: (mandible superimposed over the occiput)

Repeat 1 and 2 above.

Examination Summary: Pharyngogram

1. Full column	Upright: Lat., AP	Spot 4/sec Fluoro loop
2. Air contrast	Upright: Lat., AP	Spot

RPO positioning may be necessary to view the cricopharyngeal segment in patients with high shoulders.

Post fluoroscopic imaging at direction of radiologist.

REFERENCE:

1. Rubesin SE, ***Pharynx: Normal Anatomy and Examination*** in, Textbook of Gastrointestinal Radiology; Gore RM and Levine MS ; 3rd edition, 2007, Saunders, Chapter 18.

MULTIPHASIC ESOPHAGRAM: BARIUM CONTRAST

INDICATIONS:

- Dysphagia and Odynophagia
- For anatomic and physiologic evaluation of the esophagus.
- Evaluation of trachea-esophageal fistula
- If assessment for perforation or leak, use water soluble contrast examination

CONTRAINDICATION:

- Use water soluble contrast if there is concern of leak or recent oro-pharyngeal or laryngeal surgery. See pharyngoesophagram for leak, page-27.

PREPARATION:
NPO for four hours is sufficient (no smoking or chewing gum)
In emergent conditions, no preparation needed

MATERIALS:

- 50 cc 250% w/v barium suspension
- One packet effervescent agent
- 5 cc water with 2 drops of mylicon
- 300 cc (1 bottle) 60% w/v barium suspension
- Small marshmallows
- Cup of water with straw
- Emesis basin
- Washcloth

PREPROCEDURE POINTS:

- There is no preliminary image for the esophagram
- Question the patient regarding relevant chief complaint, prior GI surgery, or swallowing difficulty and plan the study accordingly
- Check that the fluoroscopy unit is fully operational before beginning the examination.

TECHNIQUE FOR RADIOLOGISTS:

Standing LPO

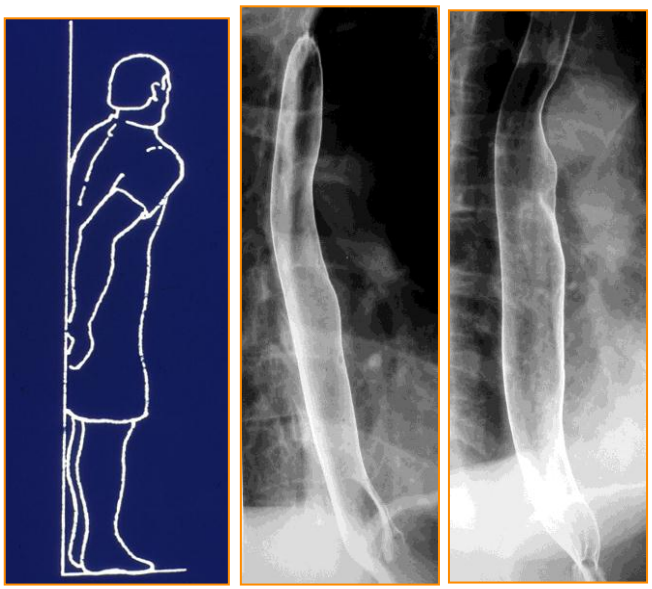

This step is performed patients with suspected mucosal disease such as GERD, esophagitis, ulcer, or neoplasm.

- Have patient throw the effervescent granules to the back of the mouth and wash down quickly with water and mylicon. Stress to patient not to belch.
- Standing LPO: Position the fluoroscope to frame the esophagus from the thoracic inlet to include the EG junction and hold in this position during filming.
- Have patient gulp rapidly 50cc of the high-density (250%) barium, followed by repeated large swallows of air. This will inhibit primary wave activity and enhance distension of the esophagus.
- Fluoroscope and, when the esophagus is distended, film full length views.
- **If significant aspiration is seen: Discontinue study!** Don't forget to take a lateral and AP spot view of the pharynx to document extent of aspiration.
- **If achalasia is detected:** Convert to achalasia protocol (Given below).

Motility evaluation, full column, and mucosal relief evaluation of the esophagus:

Prone RAO:



- Have the patient take a single comfortable swallow of medium-density (65%) barium. Caution the patient not to take a second swallow which will generate an inhibitory wave.
- Evaluate esophageal motility by following the tail of the barium column from the pharynx to the stomach. Repeat if necessary.
- Use fluoro loop/video recording.
- Have the patient take several swallows of medium-density (65%) barium in rapid succession and perform a Valsalva maneuver as the barium bolus fills the distal esophagus.
- Observe for rings, stenoses, and hiatal hernia.
- Take spot images of the esophagus including the GEJ, during Valsalva, and in mucosal relief (collapsed).
- A 10-13 mm marshmallow may be used to determine caliber of stenosis or ring.

Evaluation for G-E reflux:

Supine RPO:



- Have the patient roll from the RAO position through left side down to the supine position and intermittently fluoroscope to observe for reflux. Note that this method of rotation accentuates barium filling of the gastric fundus and is the reverse of the rotation for coating the stomach.
- With patient 10° head down, in AP and 10° RPO position and with the fundus filled, have the patient Valsalva, cough, and dry swallow.
- Observe and report: 1) Maneuver eliciting reflux, 2) Height of the refluxed barium column, 3) Time taken to clear the refluxate column.

TECHNIQUE FOR TECHNOLOGISTS:

- No preliminary image**.**
- Consult radiologist about planning the study.
- Make sure the DVR is on.
- Record track # from DVR.
- Table should be upright.

Examination Summary: Multiphasic Esophagram

	Objective	Patient Position	Imaging
1.	Air contrast esophagus	Upright:LPO	Spot
2.	Tubular esophagus: single swallow for motility	Prone:RAO	Spot Fluoro loop
3.	Tubular and distal esophagus: full column Valsalva and mucosal relief	Prone:RAO	Spot
4.	Gastroesophageal reflux	Turn:RAO: L.lat.: AP: RPO	PRN

REFERENCE:

Laufer I and Levine MS, ***Barium Studies of the Upper Gastrointestinal Tract*** in, Textbook of Gastrointestinal Radiology; Gore RM and Levine MS ; 3rd edition, 2007, Saunders, Chapter 21.

MODIFICATIONS OF PHARYNGOGRAM AND ESOPHAGRAM:

COMBINING THE PHARYNGOGRAM AND ESOPHAGRAM

The pharyngogram and esophagram may be combined, when evaluating the anatomy and physiology of both is indicated. The examination should be tailored to address specific patient problems, rarely will the entire study be performed.

Technique:
To combine both, a specific sequence should be followed:
Air contrast evaluation of esophageal mucosa in LPO position ➔ Full column evaluation of the pharynx➔ Motility, full column, and mucosal relief evaluation of the esophagus in RAO position➔ Evaluation for G-E reflux in RPO position.

PHARYNGOGRAM and ESOPHAGRAM WITH MARSHMALLOW:

A “salad size” marshmallow (10-13 mm) is given when dysphagia is NOT explained by the findings on the routine study or when a narrowing, such as a stricture or ring, warrants measurement to assess clinical significance (not needed with tight strictures).

PHARYNGOGRAM OR PHARYNGOESOPHAGRAM WITH SPEECH/SWALLOWING SPECIALIST

This is performed in conjunction with a speech and swallowing specialist. The patients are provided with varying viscosity and volume of barium contrast to evaluate pharyngeal swallowing function and anatomy. The examination is observed with video-fluoroscopy and imaged with 4/sec spot images or “fluoro loops” in the lateral projection. Examination in the AP projection is indicated if a unilateral abnormality is suspected. Pharyngeal function, penetration, and aspiration are noted. This may be combined with an esophagram if the symptoms are not precisely localized to the pharynx.

ESOPHAGRAM IN ACHALASIA:

In the LPO position, observe the barium column under video fluoroscopy until the lower esophageal sphincter opens for the first time. Take digital images of the esophagus at 1, 2, and 5 minutes at the same level of the GEJ and include part of the distal esophagus. Don’t forget to mention the time in the images. Use 12” or greater magnification settings. RAO motility and morphology evaluations are important using full column view and video recording.

REFERENCE:

Laufer I and Levine MS, ***Barium Studies of the Upper Gastrointestinal Tract*** in, Textbook of Gastrointestinal Radiology; Gore RM and Levine MS ; 3rd edition, 2007, Saunders, Chapter 21.

PHARYNGOGRAM AND ESOPHAGRAM FOR LEAK: Iodinated (Water Soluble) Contrast, then Barium

INDICATIONS AND CONTRAINDICATIONS:
For use when pharyngeal or esophageal disruption by penetrating injury or postsurgical anastomotic leakage is suspected. The major contraindication to iodinated water soluble contrast material is aspiration. In these patients, non ionic media should be used as the initial contrast agent.

PREPARATION:
NPO after midnight (no smoking or chewing gum)

MATERIALS:
100 cc Omnipaque 240
300 cc (1 bottle) 65% w/v barium suspension
Straw
Emesis Basin
Washcloth

TECHNIQUE FOR RADIOLOGISTS:
- This examination is tailored to the clinical indication.
- Identify the site of anastomosis or suspected perforation and focus filming at this point
- 20° upright LPO should be the initial position with **4/sec spot imaging.**
- Repeat in RPO position.
- If there is no leak or obstruction, repeat in both positions with barium contrast.
- For post esophagectomy gastric pull-up patients, with the patient upright obtain spot images of the stomach and duodenum to document emptying.

TECHNIQUE FOR TECHNOLOGISTS:
No scout or pre-procedure image is necessary.
Consult radiologist about planning the study.
Make sure the DVR is on.
Record track # from DVR
Table should be 20 degrees upright
4/sec spot imaging and as dictated by the patient's condition and needs of the examination.
Post procedure films: None

REACTIONS, SIDE EFFECTS, AND THEIR TREATMENT:
Aspiration of water-soluble contrast media is the most serious potential side effect. The patient should be carefully monitored for development of pulmonary edema.

REFERENCE:

Laufer I and Levine MS, ***Barium Studies of the Upper Gastrointestinal Tract*** in, Textbook of Gastrointestinal Radiology; Gore RM and Levine MS ; 3rd edition, 2007, Saunders, Chapter 21.

MULTIPHASIC UPPER GASTROINTESTINAL SERIES

12 ESSENTIAL POSITIONS

LPO Upright: Air Contrast Esophagus



LPO Supine, Left Lateral Roll: Keep Barium in the Stomach

Left Side Down and 360 Degree Coat the Stomach with Barium

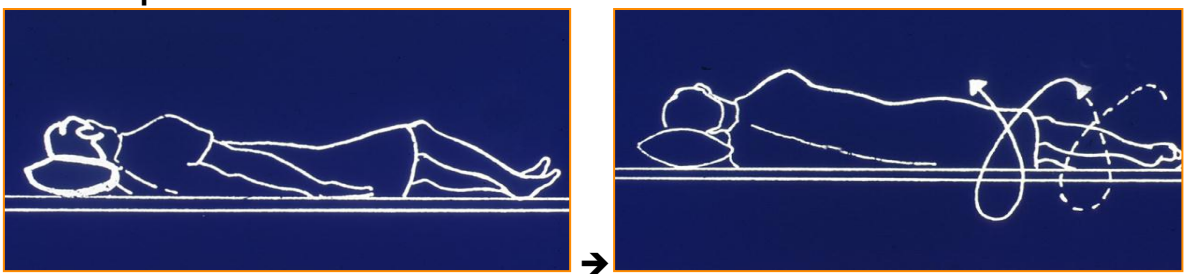

LPO Supine

Gastric Antrum Air Contrast



AP Supine

Gastric Body Air Contrast

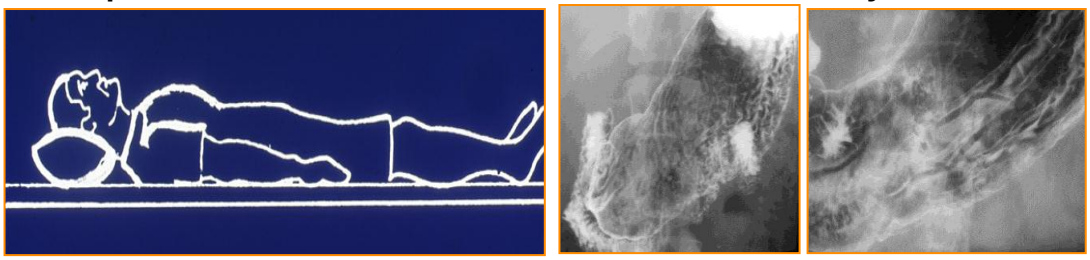

RAO Prone **Gastric Fundus Air Contrast**

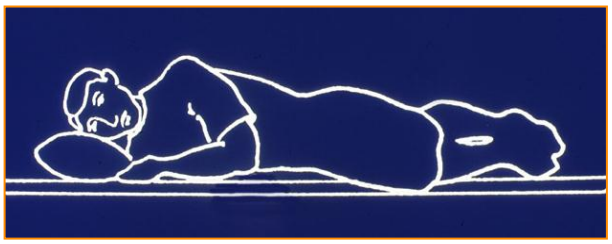
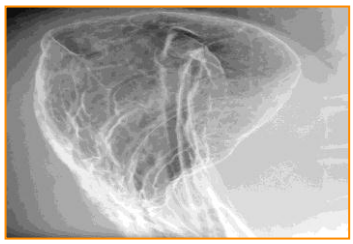

LPO Supine **Antrum and Duodenum Air Contrast**


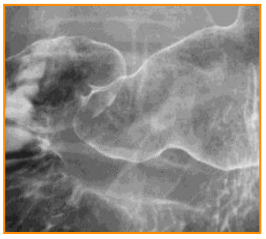
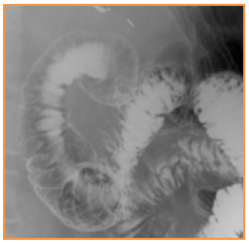

RAO, PA Prone Compression
Duodenum to Fundus



RAO Prone
Esophageal Motility

Roll from RAO through Prone and left side down to Supine and then RPO



RPO: Best Positon to Invoke GERD **RPO with Head-Down is Even Better**



REFERENCE:

Laufer I and Levine MS, ***Barium Studies of the Upper Gastrointestinal Tract*** in, Textbook of Gastrointestinal Radiology; Gore RM and Levine MS ; 3rd edition, 2007, Saunders, Chapter 21

SINGLE CONTRAST UPPER GASTROINTESTINAL SERIES

INDICATIONS:

For anatomic and physiologic evaluation of the esophagus, stomach and duodenum. It is especially useful in elderly or disabled patients who are unable to turn on the fluoroscopic table or stand. It should also be used when gastric outlet obstruction is suspected.

CONTRAINDICATIONS:

Aspiration risk. If there is a question of perforation of the gastrointestinal tract, undiluted iodinated contrast material should be used. Colonic obstruction is a contraindication to the use of barium.

PATIENT PREPARATION:
NPO after midnight (no smoking or chewing gum).

MATERIALS:
1 bottle barium 60 % w/v barium suspension
Small marshmallows
Cup of water and straw
Emesis basin
Wash cloth
Paddle compression device
Lead gloves

PREPROCEDURE POINTS:

1. Examine preliminary image for free intra-abdominal air, gastric distension, colon obstruction, or retained barium.
2. Question the patient regarding relevant chief complaint, GI surgery, or difficulty swallowing, and plan the study accordingly.
3. Check that the fluoroscopy unit is fully operational before beginning the examination.

TECHNIQUE FOR RADIOLOGISTS:

- If patient is able to stand, start upright: With patient LPO to project the esophagus off the spine, follow 2-3 swallows from mouth to stomach observing morphology and function. Similar information may be obtained in the supine LPO position.
- Palpate and compress stomach to coat entire mucosa and to assess pliability. Spot images if abnormality is suspected.
- With the table horizontal, patient supine or slight LPO, spot gastric mucosal fold pattern.
- Turn patient to RAO prone oblique. Spot mucosal fold pattern of fundus & body.
- Observe esophageal motility during single swallow. Then obtain filled spot images of esophagus. Spot the EG junction during Valsalva maneuver.

- Continuing in the RAO and the PA positions, observe peristalsis in the stomach and duodenum. Spot the stomach, including antrum, and duodenum to the ligament of Treitz.
- Turn the patient to AP and spot image the stomach and duodenum with air contrast, if possible.
- Compression spots may be obtained if possible.
- Modify as needed especially for patient unable to stand or roll. Begin with drinking views as near RAO as possible then go for supine or LPO, and then continue as above. Spot the distended fundus with patient prone or prone oblique and table tilted, or spot supine distended with barium.

TECHNIQUE FOR TECHNOLOGISTS:

Preliminary PA abdomen film to show diaphragms, 80 kVp
Fluoroscopy spot films 120kVp
Consult radiologist about planning the study
Table should be upright

Post fluoroscopy imaging: None

REFERENCE:

Laufer I and Levine MS, ***Barium Studies of the Upper Gastrointestinal Tract*** in, Textbook of Gastrointestinal Radiology; Gore RM and Levine MS ; 3rd edition, 2007, Saunders, Chapter 21.

Examination Summary: Single Contrast UGI

	Objective	Patient Position	Imaging
1.	Full column Survey esophagus and EG junction	Upright or Supine: LPO	Spot
2.	Survey and palpate stomach	Upright: LPO - RPO	Spot
3.	Gastric mucosal relief	Supine: AP/LPO	Spot
4.	Full column esophagus and motility	Prone: RAO	Spot Fluoro loop
5.	EG junction with Valsalva	Prone: RAO	Spot
6.	Gastric mucosal relief	RAO, Supine	Spot
7.	Compression stomach (distended)	Upright: LPO - RPO	Spot
8.	Duodenal bulb (compression, full column)	Upright: LPO, Left Lateral, RPO	Spot
9.	Air contrast stomach and duodenal bulb	Supine: LPO, AP	Spot
10.	GE reflux	Turn: AP: RPO	As needed

MULTIPHASIC UPPER GASTROINTESTINAL EXAMINATION

INDICATIONS:

For anatomic and physiologic evaluation of esophagus, stomach and duodenum, especially when mucosal evaluation is indicated

CONTRAINDICATIONS:

Aspiration risk. If there is question of perforation of the GI tract, undiluted iodinated contrast material should be used by the single contrast protocol. Food or fluid in stomach and esophageal or gastric outlet obstruction limit mucosal coating. Colonic obstruction is a contraindication to the use of barium.

PREPARATION:

NPO after midnight (no smoking, or chewing gum).

MATERIALS:

50 cc 250% w/v barium suspension
One packet effervescent agent
5 cc water with 2 drops of mylicon
1 bottle 60% w/v barium suspension
Small marshmallows
Cup of water with straw
Emesis basin
Wash Cloth
Paddle compression device
Lead gloves

PREPROCEDURE POINTS:

1. Examine scout film for free intra-abdominal air, gastric distension, colon obstruction or retained barium.
2. Question the patient regarding relevant chief complaint, GI surgery, or difficulty swallowing and plan the study accordingly.
3. Check that the fluoroscopy unit is fully operational before beginning the examination.

TECHNIQUE FOR RADIOLOGISTS:

Air Contrast Examination of the Esophageal Muscosa:
This step is performed patients with suspected mucosal disease such as GERD, esophagitis, ulcer, or neoplasm.

- Have patient throw the effervescent granules to the back of the mouth and wash down quickly with water and mylicon. Stress to patient not to belch.
- Standing LPO: Position the fluoroscope to frame the esophagus from the thoracic inlet to include the EG junction and hold in this position during filming.

- Have patient gulp rapidly 50cc of the high-density (250%) barium, followed by repeated large swallows of air. This will inhibit primary wave activity and enhance distension of the esophagus.
- Fluoroscope and, when the esophagus is distended, film full length views.
- **If significant aspiration is seen: Discontinue study!** Don't forget to take a lateral and AP spot view of the pharynx to document extent of aspiration.
- **If achalasia is detected:** Convert to achalasia protocol.

Air Contrast Evaluation of the Stomach:

- With the patient maintained in the steep LPO position, immediately tilt the table to the horizontal position. Then have the patient roll to the left 360° returning to the LPO position.
- Make a quick fluoroscopic check of the stomach - if the stomach is well coated, begin spot imaging. If coating is inadequate, have the patient roll to the right or to a fluoroscopically determined position to optimize coating, then return to the LPO position.
- Take air contrast spot images of the stomach and duodenum:
  a. LPO stomach (antrum)
  b. AP stomach (body)
  c. Right lateral stomach (fundus)
  d. LPO, left lateral (duodenum)

Prone Compression Evaluation of the Duodenum and Stomach (possible with conventional, not remote fluoroscope):

1. With the patient RAO prone use the compression paddle to obtain spot images of the duodenal bulb and pylorus.
2. With the patient PA prone compression spot the antrum, body and fundus of the stomach. Deep inspiration may allow for better fundal compression.
3. When using remote fluoroscopes, the stomach may also be compressed AP supine and upright.

Full column and mucosal relief evaluation of the esophagus:

- Have the patient take a single comfortable swallow of medium-density (65%) barium. Caution the patient not to take a second swallow which will generate an inhibitory wave.
- Evaluate esophageal motility by following the tail of the barium column from the pharynx to the stomach. Repeat if necessary.
- Use fluoro loop/video recording
- Have the patient take several swallows of medium-density (65%) barium in rapid succession and perform a Valsalva maneuver as the barium bolus fills the distal esophagus.
- Observe for rings, stenoses, and hiatal hernia.
- Take spot images of the esophagus including the GEJ, during Valsalva, and in mucosal relief (collapsed).
- A 1 cm marshmallow may be used to determine caliber of stenosis or ring.

Full Column and Motility Evaluation of the Stomach and Duodenum:

- Evaluate gastric motility in the prone RAO by observing the normal peristaltic waves as they progress from body through the pylorus.
- Observe the duodenal bulb and sweep through the ligament of Treitz. Examine for abnormalities of peristalsis, evidence of fixation, or mucosal disease. Obtain filled images.

Evaluation for G-E reflux:

- Have the patient roll from the RAO position through left side down to the supine position and intermittently fluoroscope to observe for reflux. Note that this method of rotation accentuates barium filling of the gastric fundus and is the reverse of the rotation for coating the stomach.
- With patient 10° head down, in AP and 10° RPO position and with the fundus filled, have the patient Valsalva, cough and dry swallow.
- Observe and report: 1) Maneuver eliciting reflux, 2) Height of the refluxed barium column, 3) Time taken to clear the refluxate column

Air Contrast Evaluation of the Duodenum:

If air contrast images of the duodenum were not optimal previously, return the patient to the LPO position or L Lat. and film the distended duodenum.

TECHNIQUE FOR TECHNOLOGISTS:

Preliminary AP abdomen to show diaphragms, 70-80 kVp
Consult Radiologist about planning the study
Table should be upright
Fluoroscopy spots at 90kVp for air contrast, 120 kVp for single contrast.

Post fluoroscopy imaging: None

REFERENCE:

Laufer I and Levine MS, ***Barium Studies of the Upper Gastrointestinal Tract*** in, Textbook of Gastrointestinal Radiology; Gore RM and Levine MS ; 3rd edition, 2007, Saunders, Chapter 21.

Examination Summary: Multiphasic Upper Gastrointestinal Examination

Objective	Patient Position	Imaging
1. Air contrast Esophagus	Upright: LPO	Spot
2. Air contrast Stomach	Supine: LPO, AP, right lateral	Spot
3. Air contrast duodenum	Supine: LPO, left lateral	Spot
4. Compression stomach, duodenum	Prone: RAO, PA	Spot
5. Tubular esophagus: Full column, for caliber and motility	Prone: RAO	Fluoro loop Spot
6. Distal esophagus: full column and mucosal relief	Prone: RAO	Spot
7. Stomach and duodenal sweep: filled, motility	Prone: RAO	Spot
8. GE reflux roll:	RAO, left decubitus, AP, RPO	As needed
9. Air contrast duodenum (if not obtained 3. above)	Supine: LPO	Spot

MODIFICATIONS OF UPPER GASTROINTESTINAL SERIES: POST GASTRIC BYPASS EVALUATION

Gastric bypass is one of the most common bariatric surgeries performed at our institution.

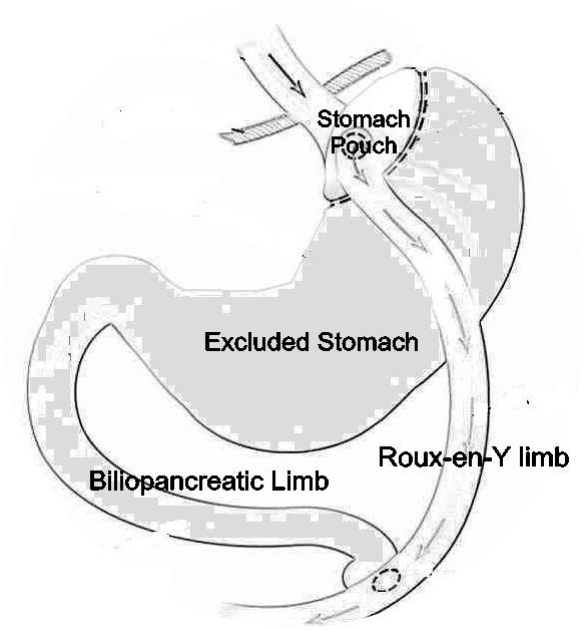

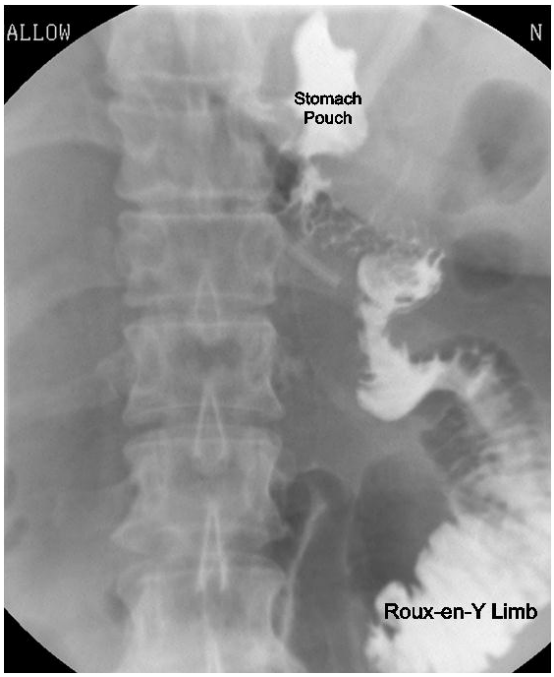

Surgery: A small (15cc) gastric pouch (GP) is formed from the cardia of the stomach with surgical staples. A majority of gastric lumen is excluded (excluded stomach). A jejunal (Roux-en-Y) limb is carried through the transverse mesocolon to form the gastrojejunal anastomosis (side to side or end to side).

Indications:

1. Post-operative: Rule out leak.
2. Weight gain or not losing weight: Suspected staple line dehiscence.
3. Abdominal pain.

Preparation:
NPO after midnight (no smoking or chewing gum)

Contrast:
Omnipaque (Post operative: In first 2 weeks)
Barium (after 2 weeks): 300cc of 65% w/v barium suspension

PREPROCEDURE POINTS:
Scout of left upper quadrant

TECHNIQUE FOR RADIOLOGISTS:

Post-operative (24 hrs)

After taking preliminary overhead film in supine position, start with **supine AP view**. Table can be tilted up to 25-45 degree (This will allow free flow of contrast column with gravity).

Supine AP view

Instruct patient to drink consecutive swallows of contrast and center over LUQ. Watch for emptying of GEJ, GJ anastomosis and leak. Take spot images over pouch and anastomosis. Magnification will need more exposure time, resulting in motion artifacts.

LAO view

Repeat the above in left anterior oblique view. Use cushions if patient is not able to move.

Lateral view

True left lateral view is essential to explore the area posterior to the anastomosis. Subtle leaks can often be picked up here.

Post fluoroscopy imaging

Take 10-minute delayed images if staple line dehiscence is considered. If necessary, also take oblique images.
Look for normal emptying in the distal jejunum.

Technique for technologists

Preliminary overhead scout film to include LUQ
Post fluoroscopy imaging: 10 minute delay if needed

After 2 weeks (with Barium)

Full column evaluation of the esophagus:

Erect LPO:

- If patient is able to stand, start upright: With patient LPO to project the esophagus off the spine: Position the fluoroscope to frame the esophagus from the thoracic inlet to include the EG junction and hold in this position during filming.
- Follow 3 swallows from mouth to stomach observing morphology and function. Similar information may be obtained in the supine LPO position.
- Fluoroscope and when the esophagus is distended, film full length views.

Erect AP:

Instruct patient to drink consecutive swallows of contrast and center over LUQ. Watch for emptying of GEJ, GJ anastomosis and leak. Take spot images over pouch and anastomosis. Magnification will need more exposure time, resulting in motion artifacts.

Prone RAO:

- Have the patient take a single comfortable swallow of medium-density (65%) barium. Caution the patient not to take a second swallow which will generate an inhibitory wave.
- Evaluate esophageal motility by following the tail of the barium column from the pharynx to the stomach. Repeat if necessary.
- Use fluoro loop/video recording
- Have the patient take several swallows of medium-density (65%) barium in rapid succession and perform a Valsalva maneuver as the barium bolus fills the distal esophagus.
- Observe for rings, stenoses, and hiatal hernia.
- Take spot images of the esophagus including the GEJ, during Valsalva, and in mucosal relief (collapsed).
- A small marshmallow may be used to determine caliber of stenosis or ring.

LAO/RAO and Lateral views:

Anastomotic area can be evaluated in bilateral oblique views.
Retrogastric region is best seen in lateral view.

Evaluation for G-E reflux:

- Have the patient roll from the RAO position through left side down to the supine position and intermittently fluoroscope to observe for reflux. Note that this method of rotation accentuates barium filling of the gastric fundus and is the reverse of the rotation for coating the stomach.
- With patient 10° head down, in AP and 10° RPO position and with the fundus filled, have the patient Valsalva, cough and dry swallow.
- Observe and report: 1) Maneuver eliciting reflux, 2) Height of the refluxed barium column, 3) Time taken to clear the refluxate column.

Post fluoroscopy imaging:

Special attention should be given to 10-minute film, as most of the patients are presenting with suspected staple line dehiscence. If necessary take more oblique images.

REFERENCES:

1. Imaging in bariatric surgery: a guide to postsurgical anatomy and common complications;Chandler RC, Srinivas G, Chintapalli KN, Schwesinger WH, Prasad SR; AJR Am J Roentgenol. 2008 Jan;190(1):122-35.

2. Radiology of the laparoscopic Roux-en-Y gastric bypass procedure: conceptualization and precise interpretation of results; Scheirey CD, Scholz FJ, Shah PC, Brams DM, Wong BB, Pedrosa M; Radiographics. 2006 Sep-Oct;26(5):1355-71.

3. Gore RM and Smith CH, ***Postoperative Stomach and Duodenum*** in, Textbook of Gastrointestinal Radiology; Gore RM and Levine MS ; 3rd edition, 2007, Saunders, Chapter 39.

EVALUATION OF GASTRIC BAND

Laparoscopic gastric banding is one of the most common surgical procedures performed in order to achieve a sustained weight loss.

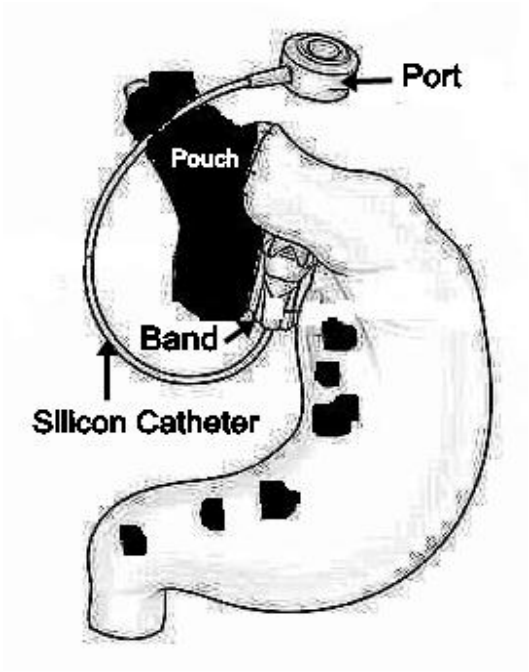

Surgery:
A proximal gastric pouch (15–20 ml) is formed by placing a gastric band, which is connected to the remainder of the stomach via a thin orifice. The diameter of the gastric band can be adjusted by injecting saline into a subcutaneously implanted port.

Indications:

1. Weight gain or not losing weight: Patulous orifice
2. Rule out complications or mal-positioning of band

Preparation:

NPO after midnight (no smoking or chewing gum)

Contrast:

Barium (300cc of 60% w/v barium suspension)
Immediate post-operative evaluation is not common but Omnipaque should be used in that situation. Early complications include band mal-position and perforation.

PREPROCEDURE POINTS:

Question the patient about any problems they are having, such as regurgitation or solid food intolerance, weight loss since band placement, and if the band has been recently tightened or deflated.

Scout of upper abdomen (AP)

- Preliminary AP projection: To assess the position of the band and continuity of connecting catheter.
- Measuring Phi angle: The Phi angle (angle between the spinal column and the gastric band) ranges between 5-58°. Anything beyond the normal rage suggest displacement of the band.
- The normal band should not lie >5 cm below the diaphragm.
- The connecting silicone catheter is radio-opaque and should not demonstrate any discontinuity.
- Also look for evidence of obstruction such as esophageal dilation or an air-fluid level within the esophagus.
- Determine the number of “BBs” or clips in the port. This will allow measuring the cuff.

TECHNIQUE FOR RADIOLOGISTS:

- Start upright with the patient in the LPO and **AP** positions. Follow multiple swallows from mouth to beyond the Lap-Band, observing esophageal caliber and postsurgical anatomy. Note whether contrast material is transiently held above the band, and whether the gastric pouch is dilated. Spot image the full esophagus as the contrast traverses the band.
- With the patient in the RAO position, move the table to the horizontal. In this position, observe a single swallow with *fluoro loop* recording, following from the upper sphincter through the Lap-Band.
- Have the patient take sequential swallows. Spot image the full esophagus as contrast passes through the Lap-Band. With valsalva maneuver, determine the presence of a hiatal hernia and assess for pouch dilation with spot images.
- Spot image the stomach in the RAO and **PA** positions with contrast traversing the band. As the patient rotates from RAO to prone to left lateral to LPO to supine, look for evidence of reflux and band slippage.
- With the patient in the RPO position and the table in 10 degrees Trendelenberg, look for spontaneous and provoked reflux.

Evaluation of Band:

1. Erect AP view with contrast: To assess the gastric pouch and stoma.
2. The ideal diameter of the stoma should be 3-4 mm for sufficient weight loss.
3. A wider stoma allows too quick passage of the food resulting in insufficient weight loss.
4. The pouch normally shows a grossly regular contour and is concentric in shape.
5. After adequate filling with contrast, the gastric pouch diameter should be <4 cm (corresponds to a volume of 15-20 mL).

How to measure diameter of stoma and pouch:

1.) On the IITV (Fluoroscopy) machine's monitor: Easy measurements, if option is available.
2.) On PACS monitor: Calibration is needed before the any measurement is made on PACS images. The first step is to measure the outer diameter of the band, which allows accurate calibration because each make of gastric band has a pre-fixed diameter.



Measure the lumen of the stomach inside the band using the correction factors of the *external* band diameter:

2BBs	APLarge	47 mm cuff diameter
1BB	APStandard	43 mm cuff diameter
4 metal clips	Realize C	39 mm cuff diameter
No clips/BBs	Vanguard	50 mm cuff diameter

TECHNIQUE FOR TECHNOLOGISTS:

1. Preliminary AP abdomen film from mid thorax through mid abdomen to show the injection port and the lap band.
2. Single contrast barium.

REFERENCES:

1. Adjustable laparoscopic gastric banding in patients with morbid obesity: radiographic management, results, and postoperative complications; Wiesner W, Schöb O, Hauser RS, Hauser M; Radiology. 2000 Aug;216(2):389-94.

2. Pictorial Essay: Laparoscopic Adjustable Gastric Banding Surgery for Morbid Obesity: Imaging of Normal Anatomic Features and Postoperative Gastrointestinal Complications; Arye Blachar, Blachar A, Blank A, Gavert N, Metzer U, Fluser G, Abu-Abeid S. AJR February 2007 188:472-479; doi:10.2214/AJR.05.0293.

3. Gore RM and Smith CH, ***Postoperative Stomach and Duodenum*** in, Textbook of Gastrointestinal Radiology; Gore RM and Levine MS ; 3rd edition, 2007, Saunders, Chapter 39.

POST-FUNDOPLICATION EVALUATION

Surgery and indications:

A Nissen **(and other)** fundoplication is usually performed to treat symptomatic GERD which failed to respond medical treatment, para-esophageal hernia repair, and accompanying myotomy treatment for achalasia. In this procedure the gastric fundus is wrapped (plicated) around the lower end of the esophagus 360 degrees.

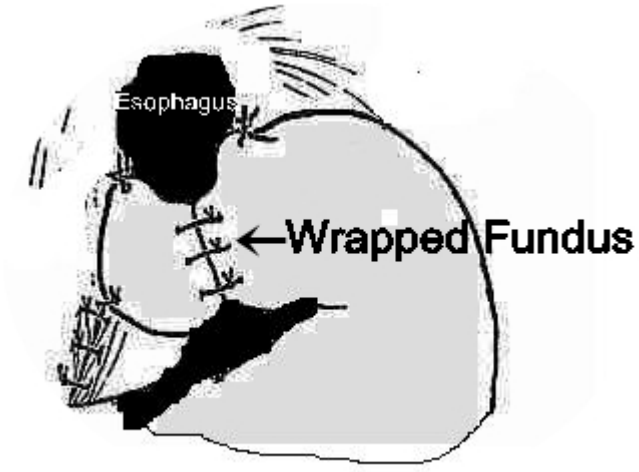

Preparation:

NPO after midnight (no smoking or chewing gum)

Contrast:

Barium (300cc of 65% w/v barium suspension)

PREPROCEDURE POINTS:

1. Thoroughly evaluate the patient for symptoms and course after surgery. There could be some pre-surgical symptoms not related to GERD, which failed to respond after surgery.
2. Know the type of fundoplication performed. Any plication other than Nissen would be a partial (<300°) wrap. This may give rise to the appearance of a disrupted fundoplication.

TECHNIQUE FOR RADIOLOGISTS:

Follow the protocol of routine esophagram.

- A tight fundoplication can result in symptoms that mimic achalasia. Approximately 250 mL of low-density barium should be emptied within 1 minute. A 1.3 cm marshmallow can be used to assess the tightness of the fundoplication.

- Make every effort to not only distend but also to coat the fundoplication to determine its integrity. Air contrast allows better distension and coating of fundoplication.
- In supine phase, efforts to distend and coat the fundoplication should be performed. High-density barium can be given in supine position and refluxed into the fundoplication by rolling the patient toward the left, then prone, then left, and then supine, several times.
- Place the patient in the right lateral decubitus and elevate the table at 45° and take a spot radiograph of the GEJ in the AP and RPO and LPO.
- Gastric motility and emptying should be subjectively assessed.
- Gastric and duodenal images can be taken as needed.

Evaluation of Fundoplication

The normal Nissen fundoplication should be:

- Subdiaphragmatic with no recurrent hernia above it.
- <3 cm in length (measured on digital radiographs).
- Surround the distal esophagus with only a small amount of stomach wrapped.
- Open enough to allow free passage of 13-mm marshmallow
- Not permit reflux.

REFERENCES:

1. Gastroesophageal reflux disease: integrating the barium esophagram before and after antireflux surgery; Baker ME, Einstein DM, Herts BR, Remer EM, Motta-Ramirez GA, Ehrenwald E, Rice TW, Richter JE; Radiology. 2007 May;_ 243(2):329-39.

2. Gastroesophageal reflux disease: integrating the barium esophagram before and after antireflux surgery; Baker ME, Einstein DM, Herts BR, Remer EM, Motta-Ramirez GA, Ehrenwald E, Rice TW, Richter JE; Radiology. 2007 May; 243(2):329-39.

3. Gore RM and Smith CH, ***Postoperative Stomach and Duodenum*** in, Textbook of Gastrointestinal Radiology; Gore RM and Levine MS ; 3rd edition, 2007, Saunders, Chapter 39.

TUBE CHECK (PEG or PEJ)

INDICATIONS:

1. To confirm correct tube placement and evaluate for leaks.

PREPARATION:
None

CONTRAST:
Low osmolar iodine contrast (Omniopaque)
20" Extension tubing
Leur lock syringe
Small hemostat
Exam Gloves
Saline flush
Towel
Labels

PREPROCEDURE POINTS:

Digital scout image of abdomen: to demonstrate the position of the tube

TECHNIQUE FOR RADIOLOGISTS:

1. Place the patient in **true lateral position**
2. Using a catheter-tip syringe, approximately 30-60 ml of contrast is injected through the tube.
3. During the injection obtain a **true lateral view to exclude an anterior leak.**
4. Take a supine view to document intra-luminal contrast within the stomach or jejunum.
5. Take spot images demonstrating gastric emptying across the pylorus (or contrast in the distal jejunum).
6. Don't forget to remove excess contrast (by withdrawing into the syringe) when possible. This will reduce the risk of reflux and subsequent aspiration.

Important: If a lateral view is not included (in a severely ill or ICU patient) always mention that an anterior leak cannot be excluded.

TECHNIQUE FOR TECHNOLOGISTS:
AP KUB centered over the LUQ or point of interest.
Use sterile technique to draw up contrast. Label syringe.
Post fluoroscopic Films: As indicated by radiologist.

UPPER GASTROINTESTINAL SERIES
WITH SMALL BOWEL FOLLOW THROUGH

For anatomic and physiologic evaluation of esophagus, stomach and duodenum, combined with small bowel examination as described below.

SMALL BOWEL FOLLOW THROUGH (SMALL BOWEL EXAMINATION)

INDICATIONS:
For anatomic and physiologic examination of the small intestine

CONTRAINDICATIONS:
Intestinal perforation, colonic obstruction

PATIENT PREPARATION:
NPO after midnight (no smoking, or chewing gum)

MATERIALS:
2 bottles 60 % w/v barium suspension
Straw
Emesis Basin
Wash Cloth
Paddle and “F-spoon” compression devices
Lead gloves

PREPROCEDURE POINTS:

1. Examine the preliminary image for free intra-abdominal air, gastric distension, or retained barium.
2. Question the patient regarding relevant chief complaint, GI surgery, or difficulty swallowing, and plan the study accordingly.
3. Check that the fluoroscopy unit is fully operational before beginning the examination.

TECHNIQUE FOR RADIOLOGISTS:

- If this examination is done as a primary examination, i.e., an UGI study did not precede it, give the patient 720 cc of 65% w/v barium. If this study is to follow an UGI examination, the technologist should give the patient 360 cc of 65% w/v barium in addition to that given with the upper GI series. A PA image should be obtained as an “immediate” or time “0 minutes”.
- At this time, with the patient supine, manually separate, compress and inspect all barium filled loops of small bowel using a quadrant approach: Left upper quadrant, then left lower quadrant, then right upper quadrant, then right lower quadrant.
- Oblique or lateral positions may be needed to optimally visualize the segments in profile. Spot all quadrants.
- PA images should be obtained 30 minutes thereafter and at subsequent intervals as determined by rate of progress of the contrast. Compression spot images should be obtained as above with each large format image.

- If the bowel loops are inadequately opacified, more barium may be needed. The examination is completed when the terminal ileum is visualized, examined, and filmed.

What is the normal transit time?

Variable, between 15 minutes to 3 hrs.

TECHNIQUE FOR TECHNOLOGISTS:

Preliminary: PA abdomen image to show symphysis pubis (if not taken before upper GI), 70-80 kVp
Consult radiologist about planning the study

Post fluoroscopy imaging:
Timed films as indicated by radiologist, 120 kVp
If patient immobile: AP supine

REFERENCE:

Rubesin SE, ***Barium Examination of the Small Intestine*** in, Textbook of Gastrointestinal Radiology; Gore RM and Levine MS ; 3rd edition, 2007, Saunders, Chapter 41.

.

SINGLE CONTRAST BARIUM ENEMA (SCBE)

INDICATIONS:

For anatomic and physiologic evaluation of the colon.
Especially for colonic obstruction, intussusception, subacute diverticulitis, fistula, and in some patients with intestinal dysmotility and complications of inflammatory bowel disease.

CONTRAINDICATIONS:

If there is a question of free perforation of the colon, iodinated contrast material should be used. Contraindications include toxic colon, any polypectomy within the past 14 days or biopsy through a rigid sigmoidoscope in the same interval. Incomplete preparation is a relative contraindication.

Patients suspected of having inflammatory or other mucosal disease or who are referred for colon cancer screening are best studied by double contrast technique.

PREPARATION:
See barium enema preparation sheets (Appendices 1-B,C).

MATERIALS:

Baro-bag Enema Kit (20% w/v barium suspension barium infusion bag and tip with air cuff)
Junior Enema Tip
Paddle compression device
Lead gloves
Examination gloves and lubricant
IV pole
Hemostat
Foam tape
Towels
Glucagon

PREPROCEDURE POINTS:

- Examine the preliminary image for free intraperitoneal air, distended fluid filled bowel loops, retained barium or residual fecal material, and for abnormalities which might be obscured by barium.
- Check that the fluoroscopy unit is fully operational before inserting the enema tip.
- Do not administer glucagon if there is a history of hypersensitivity to a prior injection, or in patients with pheochromocytoma or insulinoma.
- If glucagon is administered to a diabetic, the patient and their physician should be notified as it might alter blood glucose.

TECHNIQUE FOR RADIOLOGISTS:

The following are for SCBE and DCBE:

- Prior to the start of the examination, introduce yourself and briefly explain the sequence of the examination to the patient. Question patient regarding adequacy of preparation. Explain that the colon will feel very full, but is not painful to the majority of patients. (ex: "Your doctor has asked me to examine your large intestine. This is a very important examination as it can determine the presence of serious disease which may not cause symptoms nor be detectable by a physical examination. Thus, it is important to continue the exam even if you feel discomfort or pressure. We will do the examination as rapidly as possible. Let us know of any problems you may have during the exam.") Patients who understand exactly what will be happening will better be able to tolerate the examination, thus allowing a more accurate diagnostic study.

- Rectal examination: With the patient in the left lateral decubitus position and right knee flexed maximally, perform a careful rectal examination checking for mass, stricture, stool and the direction of the anal canal. Never insert an enema tip without first performing a digital rectal examination. Encourage the patient to “bear down” to relax the sphincter and facilitate the entry of the finger and enema tip.

- With gentle pressure, insert the enema tip so that the collapsed balloon lies totally within the rectal ampulla. Turn the patient to the *supine LPO* position for single contrast examinations and the *prone* position for double contrast examinations.

- Prior to inflating the rectal balloon, infuse a small amount of contrast and confirm location of the enema tip in the rectal ampulla with fluoroscopy. Inflate the balloon with fluoroscopic monitoring so that it touches the rectal margin but does not deform it. Gentle traction to snug the balloon against the internal sphincter will help prevent leakage. Do not inflate a rectal balloon in patients with proctitis, rectal carcinoma or recent rectal surgery.

- The height of the contrast bag should not exceed 1 meter unless necessitated by slow barium flow.

The sequence is for SCBE and may be modified and/or attenuated depending on the objectives of the examination and ability of the patient.

- Supine AP, LPO, L. Lat. RPO: Center at the recto-sigmoid. With control of barium flow, fill to the sigmoid colon and make spots in RPO or LPO and lateral positions as necessary. Spot the rectum AP and left lateral. With your lead gloved right hand, help the patient into optimum positions.
- Supine RPO: Center at the distal descending colon. Adjust the patient's position such that the descending colon is adjacent to the spine. Compress and spot film each segment in profile distal to proximal.
- Supine: Center at the left transverse colon. Compress and spot each segment in profile left to right, obliquing the patient as needed.
- Supine LPO: Center at the hepatic flexure. Adjust the patient's position such that the ascending colon is adjacent to the spine. Spot the hepatic flexure in profile.
- Supine LPO: Center at the cecum. Examine the distended cecum in two positions (90° to each other, i.e., RPO/LPO) en face and in profile. Spot the cecum with compression.

TECHNIQUE FOR TECHNOLOGISTS:

Preliminary AP abdomen to show symphysis pubis, 80 kVp.
Consult radiologist about planning the study.

Post fluoroscopy imaging as determined by radiologist:

PA and AP abdomen, to show the entire colon.
RAO, LAO obliques for flexures.
Remove enema tip.
15° RAO rectosigmoid with 35° caudad angulation,
(If patient is unable to be prone, use LPO and 35° cranial angulation.)
Left lateral rectum, 120Kvp with slight head-down positioning.

Post-evacuation:
AP abdomen to show the entire colon 120 Kvp.

REFERENCE:

Laufer I and Levine MS, ***Barium Studies of the Colon*** in, Textbook of Gastrointestinal Radiology; Gore RM and Levine MS ; 3rd edition, 2007, Saunders, Chapter 55.

Examination Summary: Single Contrast Barium Enema

	Objective	Patient Position	Imaging
1.	Rectosigmoid	Supine: RPO, LPO, Left lateral	Spot
2.	Descending colon and splenic flexure	Supine: AP, RPO	Spot
3.	Transverse colon	Supine: AP	Spot
4.	Hepatic flexure and ascending colon	Supine:LPO	Spot
5.	Cecum	AP, RPO, LPO	Spot with & w/o compression

DOUBLE CONTRAST BARIUM ENEMA (DCBE)

INDICATIONS:

The DCBE permits visualization of mucosal detail. For this reason it is considered the radiographic examination of choice in the evaluation of inflammatory bowel disease and for detection of small neoplasms.

CONTRAINDICATIONS:

If there is a question of perforation of the colon, a single contrast examination with iodinated contrast material should be used. Contraindications include toxic colon, any polypectomy within the past 14 days or biopsy through a rigid sigmoidoscope in the same interval.

PREPARATION:
See barium enema preparation sheets (Appendices 1-B,C).

MATERIALS:

1 Bottle 105% w/v high density barium or Polybar bag with 300cc warm water added
Double contrast barium bag and tip with air cuff
Air insufflator (blue bulb)
Paddle and “F spoon” compression devices
Lead gloves
Examination gloves and lubricant
IV pole
Small-hemostat
Lucite wedge for decubitus films

PREPROCEDURE POINTS:

1. Examine the preliminary image for free intraperitoneal air, distended fluid filled bowel loops, retained barium or residual fecal material, and for abnormalities which might be obscured by barium.
2. Check that the fluoroscopy unit is fully operational before inserting the enema tip.
3. Do not administer glucagon if there is a history of hypersensitivity to a prior injection, or in patients with pheochromocytoma or insulinoma.
4. If glucagon is administered to a diabetic, the patient and their physician should be notified as it might alter blood glucose.

TECHNIQUE FOR RADIOLOGISTS:

In addition to the technical points noted above as the same for the SCBE and DCBE, the following are specific considerations for the DCBE:

Prone position

- Administer barium with gravity flow to the level of the splenic flexure. 10 degrees head-down positioning will assist barium flow.

- As the barium passes into the mid transverse colon, turn off the barium and insufflate with air to advance the barium across the transverse colon to the hepatic flexure.

- Confirm barium has reached the hepatic flexure of the colon, then tilt the patient upright. Place the enema bag on the foot board and drain the barium from the distal colon. Repeat with air insufflation as needed. Limit barium flow into the cecum.

- Return the table to the horizontal position and spot the recto-sigmoid (LPO, left lateral & RAO). Add air as needed to maintain distension.

- Place patient erect and spot first the splenic flexure (RPO) then the hepatic flexure (LPO).

- Turn patient to the right decubitus position and then supine to facilitate flow through the flexure and into the cecum.

- Maneuver the patient to assure good barium coating of the right colon and adequate distention: If cecum is full of barium and/or medially positioned, place patient right side down and lower table head down to drain cecum. With head still down return to LPO and spot cecum as above.

- Quickly recheck entire colon, cecum to sigmoid, respotting any previously suboptimally visualized or questionable segments. Before leaving the room, check to make sure that the colon is well coated with barium and distended with air.

TECHNIQUE FOR TECHNOLOGISTS:
Preliminary AP abdomen image to show symphysis pubis, 70-80 kVp.

Post-Fluoroscopy imaging:

- Right and left lateral decubitus 90kVp images obtained with 8: 1 grid.
- PA and AP abdomen to show the entire colon, 90kVp.
- Check films and remove enema tip.
- 15° RAO rectosigmoid with 35° caudad angulation (if a large right sided sigmoid loop exists, substitute PA with 35° caudad angulation).
- Prone, cross-table lateral rectum, with slight head-down positioning.

No post evacuation image is needed.

POTENTIAL PROBLEMS:

Inability to retain barium and air

Poor rectal tone and/or colonic spasm may render some patients unable to retain the barium and air necessary for the examination. Initially, encourage the patient to relax by taking slow breaths and apply downward traction to the rectal balloon. If there is persistent colon spasm or hyper-motility and difficulty in retaining the barium, 0.5-1.0 mg of glucagon may be administered intravenously slowly over 1 minute to aid bowel relaxation. Contraindications to glucagon use include pheochromocytoma and insulinoma.

Failure to fill the right colon with barium

Patients with tortuous redundant loops of colon may require larger amounts of barium to make it easier to ensure filling the right colon. Rolling the patient allows gravity to be of help in directing barium flow. Fluoroscopic observation is crucial in moving the barium into the intended loops. For example, with a tortuous hepatic flexure, one occasionally may have to first place the patient in the LPO or left lateral position and then into supine, head-down, right lateral, and upright positions in order to allow the barium to travel through redundant loops and reach the cecum. When difficulty is encountered, do not continue to forcefully administer air to excessive amounts which may prevent completion of the examination. Take the time to evaluate where the difficulty is and which maneuvers may be helpful.

Identification of a constricting lesion

Correct identification of constricting neoplasms in the colon requires exclusion of spasm simulating a real lesion. Annular lesions should be reexamined following the administration of 1.0 mg glucagon intravenously if the appearance is atypical. Barium should not be forced proximal to a stenosis.

REFERENCE:

Laufer I and Levine MS, ***Barium Studies of the Colon*** in, Textbook of Gastrointestinal Radiology; Gore RM and Levine MS ; 3rd edition, 2007, Saunders, Chapter 55.

Examination Summary: Double Contrast Barium Enema

	Objective	Patient Position	Imaging
1.	Inflate balloon	Prone: Small amount of barium in rectum	--
2.	Barium into descending colon	Prone, head-down, turn off barium at mid-transverse colon	--
3.	Barium into transverse & right colon	Prone, right lateral, supine	--
4.	Drain barium	Erect/AP	--
5.	Recto-sigmoid filming with air insufflation	Head-down, supine to LPO left lateral to prone to RAO to supine	Spots
6.	Flexure filming	Upright: Splenic flexure - RPO Hepatic flexure - LPO	 Spot Spot
7.	Cecum filming	Supine: LPO, AP	Spots
8.	Colon survey	Supine: Obliques	prn --

MODIFICATIONS OF BARIUM ENEMA: RETROGRADE ILEOSTOMY, COLOSTOMY

INDICATIONS/CONTRAINDICATIONS:
Retrograde ileostomy or colostomy is indicated for evaluation of recurrent or new disease in the postoperative intestine, bowel obstruction, or stomal dysfunction. Contraindications include suspected bowel perforation.

PATIENT PREPARATION:
Ileostomy: NPO after midnight.
Colostomy: See barium enema preparation sheet.

MATERIALS:
1 Polibar Enema Kit (Mix 20% w/v barium suspension)
Lead gloves
Paddle compression device
Examination gloves and lubricant
IV pole
Hemostat
18-24 French Foley catheter with 30 cc balloon or EZEM cone catheter.

TECHNIQUE FOR RADIOLOGISTS:

- Use a colostomy irrigation bag or work through a hole in a regular colostomy bag to contain spillage and collect evacuated material.
- With the patient supine, do a gentle digital examination of the stoma to determine the course of the lumen through the abdominal wall.
- Using a large Foley catheter, fully inflate the balloon externally, coat the catheter tip and stoma with lubricant, and carefully cannulate the stoma with the tip of the catheter. The **balloon should not be inflated inside the stoma**. The inflated balloon will allow an external seal if compressed firmly by the patient. Have the patient wear a glove on the hand closest to the stoma and instruct them to place the Foley catheter between two fingers and compress the balloon firmly against the stoma. Alternatively, specially designed ‘ostomy cone’ injection devices may be used.
- Instill the barium by gravity flow with the bag not exceeding **one meter** above the table top. After instilling the first 25-50 cc's, turn the patient laterally as steeply as possible and spot film the stoma in profile. With the patient then in the supine position, fill the proximal bowel either to the ileocecal valve (colostomy) or to the duodenum (ileostomy).
- Carefully fluoroscope with compression and spot film any abnormalities. When studying a colostomy that is double-barreled or is vented by a distal ostomy or by the rectum, use of inflated balloons or other devices may be required in order to allow bowel distention without excessive contrast spill. In these situations (e.g., studying both the proximal and distal limbs of a diverting colostomy prior to reanastomosis), plan the most rational approach to the problem. Generally, if colonic segments both proximal and distal to a colostomy (e.g. “Loop” or Double Barrel Colostomy or Oversewn Distal Loop (Hartmann Pouch)) are to be studied, the distal portion is studied first.

TECHNIQUE FOR TECHNOLOGISTS:

Preliminary AP abdomen to show symphysis pubis, 80 kVp.

Post fluoroscopy imaging at discretion of the radiologist: All images at 120 kVp.

Ileostomy:
AP, LPO and RPO abdomen.

Colostomy:
AP, LPO, RPO and left lateral decubitus

AP abdomen following evacuation

REFERENCE:

Scholz FJ and Scheirey CD, ***Postoperative Colon*** in, Textbook of Gastrointestinal Radiology; Gore RM and Levine MS ; 3rd edition, 2007, Saunders, Chapter 67.

POUCHOGRAM

Surgery:
Total proctocolectomy with ileal pouch and ileo-anal anastomolsis (J-pouch) after total proctocolectomy for ulcerative colitis or familial polyposis.

Indications:

1. Radiologic evaluation of the J-pouch, before the diverting ileostomy is closed. (Usually performed approximately 8 weeks after the initial surgery)

Preparation:
None

MATERIALS:

2 bottles (500 cc) of Cysto Conray warmed and put into empty enema bag
Barium infusion bag
Lead gloves
Paddle compression device
Examination gloves and lubricant
IV pole
Hemostat
Blue pediatric rectal tubing or 14 Fr. red rubber catheter

PREPROCEDURE POINTS:

1. Careful digital rectal examination: To evaluate for a tight stenosis.
2. **Never use the standard rectal tube**!

TECHNIQUE FOR RADIOLOGISTS:

After inserting blue pediatric rectal tip into the pouch (via the anus) take a digital scout film to confirm the positioning of the tip. Fill the pouch and obtain digital images centered over the pouch in supine, both obliques and lateral views (9-12'"). Look carefully for any leaks.

TECHNIQUE FOR TECHNOLOGISTS:

Low supine AP abdomen as preliminary image.
Post fluoroscopic images as determined by the radiologist.

REFERENCE:

Scholz FJ and Scheirey CD, ***Postoperative Colon*** in, Textbook of Gastrointestinal Radiology; Gore RM and Levine MS ; 3rd edition, 2007, Saunders, Chapter 67.

TUBE CHOLANGIOGRAM

INDICATIONS AND CONTRAINDICATIONS:
The tube cholangiogram is used postoperatively to evaluate the biliary duct system for stones, strictures, tumors, or anatomic variants.
The tube may be a t-tube into the extrahepatic bile ducts or a straight tube into the gallbladder or bile ducts.

PATIENT PREPARATION:
No solid foods should be taken after midnight. Clear fluids may be taken as desired.

MATERIALS:
50 cc sterile iodinated contrast media Omnipaque (Iohexol 300 mg Iodine/ml) or similar.
Luer Lock or catheter tip syringe. (Examine biliary tube to determine which will fit.)
K51 extension tubing

TECHNIQUE FOR RADIOLOGISTS:

- After obtaining the preliminary image, the biliary tube should be attached with a connecting tube to the syringe of contrast material. Air should be aspirated from the system. Be careful not to put traction on the tube or the infusion apparatus with the image intensifier or shielding devices.
- With the patient supine or slight RPO, use extremely gentle hand pressure and slowly inject contrast material to fill the bile ducts. The RPO position is used to project the bile duct off the spine. Obtain early and then filled spot images.
- To fill the left hepatic ducts, LPO or left lateral positioning may be needed. The junction of the right and left hepatic ducts is usually best demonstrated in LPO position.
- Tilt the patient's feet down if needed to obtain drainage of the common bile duct into the duodenum. Spot filled and emptying.
- Do not over distend the ductal system, since this can cause pain, vagal reaction, or biliary-venous reflux of potentially infected bile. It is especially important in liver transplant patients to avoid distension of the system. For such examinations, contrast opacification of the extrahepatic duct systems and only the central portion of the intrahepatic duct systems is required.
- Fluoroscopically monitor for pancreatic duct reflux. Try to minimize such reflux by decreasing injection pressure and positioning the patient in an RPO position.
- When the entire system has been examined, the procedure can be terminated. Additional images may be indicated based on your fluoroscopic observations.

TECHNIQUE FOR TECHNOLOGISTS:

- Obtain a preliminary image (70-80 kVp) of the patient's right upper quadrant centered at the site that the t-tube enters the patient's abdomen.
- When fluoroscopy is complete the procedure may be terminated unless overhead filming is deemed necessary by the radiologist.

REFERENCE:

Turner M, Fulcher A. Gallbladder & Biliary Tract: Normal Anatomy and Examination Techniques, Chapter 75, pp. 1333-1355 in Textbook of Gastrointestinal Radiology, Saunders, 2007.

FISTULOGRAM/SINOGRAM

INDICATIONS:
To delineate the extent of a fistula or sinus and to determine its communication with underlying viscera.

PREPARATION:
None

MATERIALS:

Omnipaque (Iohexol 300 mg Iodine/ml) or similar.
60cc Catheter tip syringe.
8 Fr balloon catheter or radiologist will look at sinus and determine the size of the catheter.
3cc syringe for balloon
Exam gloves
Glove for patient
Towels

PREPROCEDURE POINTS:

Digital scout image of the area of interest

TECHNIQUE FOR RADIOLOGISTS:

1. Before starting the procedure, but after taking the scout, the orifice of draining sinus should be marked with a metal marker.
2. An 8 Fr balloon catheter or IV cannula is inserted into the orifice as far as possible.
3. If flow is back to the skin, the balloon may be carefully inflated to occlude the tract and facilitate complete filling.
4. Have the patient compress the orifice with a gauze pad or wash cloth folded.
5. Inject contrast under fluoroscopic guidance.
6. Spot films in various projections are taken to demonstrate the entire tract and intestinal or bladder communication.

TECHNIQUE FOR TECHNOLOGISTS:
Draw up contrast using sterile technique.
Digital scout image centered on area of interest.
Post fluoroscopic images: As determined by radiologist.

REFERENCE:

Chapman S, Nakielny R, A Guide to Radiological Procedures, Saunders Ltd.; 4 edition (May 7, 2001), ISBN-10: 0702025658, Chapter-3, Page 80.

ESSENTIALS OF NG/OG or FEEDING TUBE PLACEMENT
(Nasoenteric Tube Insertion under Fluoroscopic Guidance)

Nasoenteric tube insertion provides access to the gastric, duodenal or jejunal lumen for diagnostic and therapeutic purposes.

Indications:

1. To administer radiographic contrast before gastrostomy tube placement.
2. Gastric decompression and bowel rest in the setting of small-bowel obstruction.
3. Feeding or administration of medication.

Contraindication

Absolute:
Severe midface trauma (cribriform plate disruption) or recent nasal surgery

Relative:
- Esophageal varices or stricture.
- Recent banding or cautery of esophageal varices.
- Recent alkali ingestion.

Preparation:
NPO for 6 hours.

Anesthesia

- 2% Viscous lidocaine

Equipment

- Frederick-Miller tube: Soft, flexible, fine-bore (8 or 12-French, 120cm length) closed end tube with a non-weighted tip.
- Lunderquist-Ring Torque Guide wire
- Viscous lidocaine 2%
- Catheter tip or Toomey syringe, 60 mL
- Tape
- Emesis basin or plastic bag

Technique

- 10 mL of viscous lidocaine 2% is instilled through the wider nostril with the head tilted backwards. Wait for a couple of minutes and simultaneous “sniffing and swallowing” allows a better coating of the nasal and oropharyngeal mucosa and ensures appropriate anesthetic effect.

- The guide wire is passed into the tube to terminate 2cm from the tube tip.

- Lubricate the tip with lidocaine and then advance the tube through the nare into the oropharynx.

- Encourage the patient to swallow and advance the tube into the esophagus. In an unconscious patient or patient unable to swallow, fluoroscopic guidance can be used to advance the tube into esophagus.

- **Coiled up tube in the nasopharynx or oropharynx?** Partially withdraw the tube to uncoil it and rotate it at 180 degrees, this will direct the curved end pointing posteriorly toward the esophagus. In unconscious and paralyzed patients place 2-3 fingers through the patient’s mouth into the oropharynx to guide the tube into the hypopharynx.

- In the absence of swallowing, tube entry in the tracheo-bronchial tree is common and can be recognized on fluoroscopy. Usually, a coughing reflex will be initiated with such entry. Withdraw the tube in the oropharynx and retry the procedure.

- **“Is the tube passed through the vocal cords?”** If the patient is able to speak, then it has not passed through the vocal cords.

- Once in the distal esophagus, advance the guide-wire to the tip, this will provide more rigidity to the tube, and quickly advance the tube in gastric antrum.

- If the tube curls back into the stomach; remove the guide wire and inject air or contrast to delineate the outline of the stomach. Usually, this will also initiate peristaltic movements and assist in farther advancement. Crossing the pylorus needs replacement of the guide wire to the tube tip.

- In difficult cases, turning patient to the one or the other side will change the shape of stomach and facilitate advancement of the tube. Left posterior oblique position (Supported by a cushion/bolster if needed) usually helps.

- The position of the tip can be confirmed with the injection of air or contrast..

- Tape the tube to the nose to secure it in place.

Complications:

- Epistaxis
- Respiratory tree intubation
- Esophageal perforation

REFERENCES:

1. Frederick RP, Miller HM, Morrison MJ; Feeding tube for fluoroscopic placement, Radiology 145:847 Dec 1982.

2. Ott DJ et al**;** Enteral Feeding Tubes: Placement by Using Fluoroscopy and Endoscopy; *AJR* 157:769-771, October 1991.

3. Shlamovitz GZ; Nasogastric Tube; http://emedicine.medscape.com/article/80925-overview.

GU Procedures

CYSTOGRAM

INDICATIONS:

To define bladder contour and diverticula.
To investigate suspected bladder rupture.
To evaluate for fistulae involving the bladder.
To evaluate for ureteral reflux (see section on VCU).

CONTRAINDICATIONS:

Current infection of the urinary tract (relative contraindication).

PREPARATION:

If patient is a quadriplegic or high paraplegic (T1-T6),
blood pressure monitoring will be necessary (see Appendix 3 - Autonomic Dysreflexia).

MATERIALS:

250 cc of dilute contrast material (Cysto-Conray) warmed
I.V. pole and I.V. tubing
2 Clamp
Wash cloth
Large Christmas tree adapter

PREPROCEDURE POINTS:

1. Inpatients should arrive in the radiology department with a Foley catheter in place. Outpatients will have the catheter placed by the radiology department nursing staff or radiologist.
2. Drain the bladder completely prior to procedure.

TECHNIQUE FOR RADIOLOGISTS:

1. Supine position: Observe bladder filling under gravity pressure (the contrast bottle should be 1 meter above the table top). Obtain early AP spot image. Intermittently fluoroscope for ureteral reflux or extravasation of contrast material.

2. Fill the bladder to maximal capacity (determined by patient discomfort or until contrast bottle is empty or stops filling by gravity). An estimate of contrast volumes required is:

   Newborn infant 35-50 cc
   Child 200 cc
   Adult 300+ cc

Obtain spot images (1 on 1) of distended bladder in the AP, LPO, and RPO position. If rupture is of concern and none seen, obtain a lateral projection film, if possible.

TECHNIQUE FOR TECHNOLOGISTS:

Imaging: 70 KVP.

Preliminary Image: KUB abdomen (to include kidneys and symphysis pubis).

Post fluoroscopy: At discretion of radiologist.
KUB abdomen (to i**n**clude kidneys and symphysis pubis).
At this stage, drain bladder empty and obtain post-drain image if requested by radiologist: Pelvis AP; add obliques in trauma patients or if question on frontal image.

LOOPOGRAM

Surgery: Total cystectomy with ileal loop diversion for urinary drainage.

Indications:
Radiologic evaluation of the ileal loop and ureters, to determine obstruction, leakage, fistula.

Preparation: None

MATERIALS:

250 cc low osmolar iodine contrast (Cysto-Conray) warmed
Examination gloves and lubricant
Vented IV tubing
Hemostat
14-20 Fr balloon catheter attached to bottle tubing (Radiologist will choose the proper size of the catheter)
Glove for patient
Wash cloth

PREPROCEDURE POINTS:

Careful digital stomal examination: To evaluate for a tight stenosis.
Size of catheter and balloon will be determined by digital examination.

TECHNIQUE FOR RADIOLOGISTS:

- Work through a hole in a regular ostomy appliance bag to contain spillage and collect evacuated material.
- Using the Foley catheter, fully inflate the balloon externally, coat the catheter tip and stoma with lubricant, and carefully cannulate the stoma with the tip of the catheter. The **balloon should not be inflated inside the stoma**. The inflated balloon will allow an external seal if compressed firmly by the patient. Have the patient wear a glove on the hand closest to the stoma and instruct them to place the Foley catheter between two fingers and compress the balloon firmly against the stoma. Only as a last resort should the catheter be inserted into the stoma and the balloon carefully inflated.
- Instill the contrast by gravity flow with the bottle not exceeding **one meter** above the table top.
- Carefully fluoroscope and spot image as the contrast flows into the loop and ureters. Stop infusion when the renal collecting systems are visualized.

TECHNIQUE FOR TECHNOLOGISTS:

Low supine AP abdomen as preliminary image.

Post fluoroscopic images as determined by the radiologist.

VOIDING CYSTOURETHROGRAPHY

INDICATIONS:
To evaluate for vesicoureteral reflux and to investigate abnormalities of the bladder neck and urethra. Following urethral surgery to determine integrity of repair.

FOLLOW CYSTOGRAM INSTRUCTIONS THROUGH TECHNIQUE FOR RADIOLOGISTS. THEN CONTINUE AS FOLLOWS:

- Deflate the Foley balloon and remove the catheter.
- Stand patient erect (unless physically unable, or small child); RPO oblique for males, AP for females; single spots of urethra during voiding into urinal, (male or female style); observe kidneys and ureters fluoroscopically for reflux. After completion of voiding obtain 14 x 17 AP of abdomen to include the urethral area. This is obtained in females to evaluate for diverticula.

TECHNIQUE FOR TECHNOLOGISTS:
Images: 70 KVP

MALES
Preliminary: AP pelvis to include urethral area/ symphysis pubis
Post void: At discretion of radiologist

FEMALES
Scout: AP pelvis to include kidneys and bladder or urethral area.
Post void: At discretion of radiologist
.

RETROGRADE URETHROGRAPHY (RUG)

INDICATIONS:

1. Pelvic trauma with blood at meatus.
2. Pelvic trauma without blood when likelihood of urethral injury is high (e.g., pelvic diastasis, displaced pubic fractures).
3. "Trouble" passing Foley
4. Stricture or disruption assessment

CONTRAINDICATIONS:

1. Signs of urethral infection; e.g., urethral discharge
2. Recent instrumentation with bloody urethral discharge. Performing RUG may cause extravasation with venous filling.

Materials:

50cc Omnipaque 300 warmed
6-8 Fr. Foley catheter with 3 cc balloon
60 cc catheter tip syringe (for primary RUG)
3cc syringe for balloon
Sterile towel pack and Washcloth
Betadine in 4X4 tub
Right hand glove for patient
Bolster under patient's left hip to turn into RPO position.
Urinal

TECHNIQUE FOR RADIOLOGISTS:

1. Test 3 cc balloon by injecting approximately 2 cc of air. Deflate balloon and leave syringe attached to balloon port.
2. Fill Foley catheter with contrast and leave syringe attached.
3. Cleans glans with Betadine.
4. Insert Foley catheter approximately 2 cm into urethra and inflate balloon in the fossa navicularis. Inflate balloon until patient feels a "stretching" sensation. Test security of the catheter by gentle traction. Do not lubricate Foley catheter before inserting into urethra, since this increases the chances that it will slide out during the procedures. [If the patient is extremely sensitive, you may inject Lidocaine jelly first.]
5. Patient in 45° RPO with right knee flexed, left leg nearly straight. Under fluoroscopy, a good test for the proper obliquity is to see the right obturator foramen completely "closed."
6. Right hand glove for the patient. Have patient pinch penile tip and straighten the urethra. Slowly inject contrast using a 60 cc catheter tip syringe.
7. Take spots with horizontal collimation to show the anterior urethra up to and including the region of the membranous urethra. Expose the spot image when you observe contrast passing through the external sphincter. The posterior urethra will not distend on the retrograde injection.

8. If the urethra appears normal or the clinical question is answered, the examination is completed. If the question involves the posterior urethra, or need for a voiding cystourethrogram (VCUG), bladder filling should continue. During bladder filling, use fluoroscopy intermittently to be sure that extravasation is not occurring and to observe for ureteral reflux.
9. After the bladder is appropriately filled, a voiding cystourethrogram (VCUG) is done: [see discussion of that Technique under the Sections on VOIDING CYSTOURETHROGRAPHY and CYSTOGRAM.

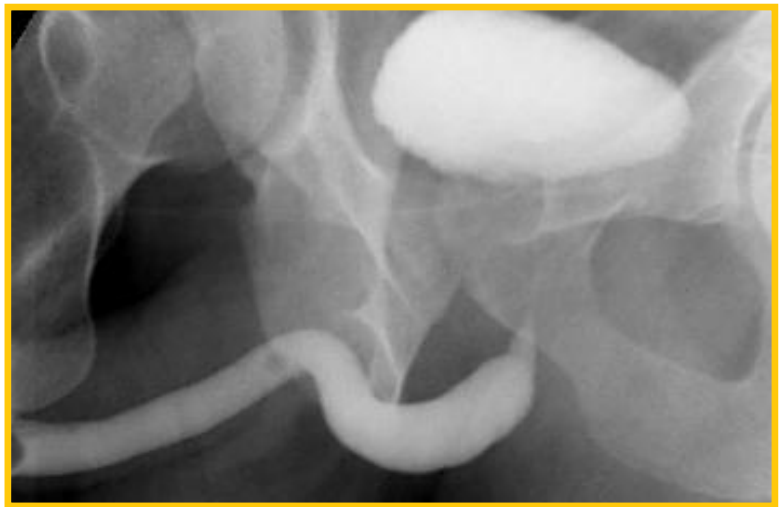

Normal RUG; note RPO position

Caveats:

1. If, during the procedure, you note filling of the penile veins, terminate the procedure. The contrast is taking the path of least resistance. Filling of penile veins may be seen in patients with chronic inflammation, stricture, or trauma.
2. In patients with complete urethral obstruction secondary to stricture associated with pelvic fracture, the patient will usually have a suprapubic tube in place. It is desirable to demonstrate the length of the stricture by performing simultaneous antegrade and retrograde urethrography. First perform the retrograde study and leave the catheter clamped when the urethra is distended up to the stricture in a retrograde direction. Then distend the bladder through the suprapubic tube [using 30% Cysto Conray] and ask the patient to attempt to void and expose the film with contrast outlining both ends of the stricture.

PERICATHETER RUG (Foley already in urethra and bladder)

Indication: To diagnose or follow urethral injury when catheter is to remain in place.

Materials:

Right hand glove for patient
Bolster under patient's left hip to turn into RPO position.
Sterile towel pack
Betadine in 4X4 tub
50cc Omnipaque 300 warmed in Luer Lock syringe
6-8 pediatric feeding tube
Elastic band
Small hemostat
Urinal

Technique:

a. Place 6 Fr. straight pediatric feeding (not a balloon catheter) tube alongside Foley about 2 inches in.
b. Use an elastic band applied in "tourniquet" fashion just proximal to glans, create tension on the band, and crossclamp the limbs of the band to maintain occlusion of the urethra.
c. Tape feeding tube to Foley to prevent it slipping out.
d. Right hand glove for the patient. Have patient pinch penile tip and straighten the urethra.
e. Slowly inject contrast using a 60 cc catheter tip syringe and proceed as with RUG.

REFERENCE:

1. Textbook of Uroradiology; N. Reed Dunnick, Carl M. Sandler, Jeffrey H. Newhouse, E. Stephen Amis; 4th Edition, 2007, ISBN-13: 978-0781767507.

APPENDICES

APPENDIX 1-A

University of Washington Hospitals
Department of Radiology
OUTPATIENT
Information and Instructions for:

ESOPHAGRAM, PHARYNGOESOPHAGRAM, UPPER GI SERIES (UGI)

SMALL BOWEL SERIES

The esophagus, stomach, and small intestine are not well seen on plain x-ray films. In order to examine these organs well it is necessary to swallow a barium fluid that can be seen on a fluoroscope screen and on the x-ray films. A good examination requires an empty stomach and therefore you will not be able to have any food or fluids by mouth l0-l2 hours before your exam. Chewing gum or other material or smoking will also create saliva to swallow which will make extra fluid in your stomach and must be avoided.

During the procedure you will be asked to swallow one or more cups of a barium containing fluid. If it is necessary to examine your entire small bowel it may take several hours. Several films may be made during this time.

l. Your examination is scheduled for _____ at _____ a.m.

2. You may have your regular diet on the evening before the exam.

3. Take nothing by mouth (except prescribed medication) and no gum chewing or smoking after midnight the evening prior to the examination.

4. Please phone the X-ray Department at 548-6200 if you have questions or are unable to keep your appointment.

Appendix 1-B

University of Washington Hospitals
Department of Radiology
INPATIENT
Information and Instructions

ESOPHAGRAM, PHARYNGOESOPHAGRAM, UPPER GI SERIES (UGI),

SMALL BOWEL SERIES

The esophagus, stomach, and small intestine are not well seen on plain x-ray films. In order to examine these organs well it is necessary to swallow a barium fluid that can be seen on a fluoroscope screen and on the x-ray films. This examination requires an empty stomach and therefore fasting is required for at least 8 hours before the examinations. Chewing gum or other material or smoking will also create extra fluid in the stomach and should be avoided.

During the procedure the patient will be asked to swallow one or more cups of a barium containing fluid. If it is necessary to examine the entire small bowel it may take several hours. Several films may be made during this time.

1. Regular diet on the evening before the exam.

2. Nothing by mouth and no gum chewing or smoking after midnight the evening prior to the examination.

3. Please phone the X-ray Department at 548-6200 if there are questions.

Appendix 1-C

University of Washington Hospitals
Department of Radiology

OUTPATIENT

Information and Instructions

BARIUM ENEMA

Your physician has requested a barium enema examination of the colon (large intestine). A satisfactory examination depends on your colon being carefully cleansed and empty. It is therefore important that these instructions be carefully followed utilizing the 'Barium Enema Prep' kit available from the pharmacy.

If you have severe kidney disease, cramping abdominal pain, considerable diarrhea, intestinal bleeding or inflammatory bowel disease, consult your primary physician before proceeding with these instructions. If you are unable to consult your physician, call the X-ray department (548-6200) for instructions.

l. Your x-ray examination is at _____ a.m.
date _____

2. For Two Days Before your examination:

   a) Take only clear liquids. Meals may include clear broth, strained fruit juices, tea, coffee, carbonated beverages, or jello.

3. On The Day Before your examination:

   a) At l, 3, 7, l0 p.m., and at bedtime, drink 8 oz. clear liquid, in addition to the clear liquid diet.
   b) At 2 p.m. drink 8 oz. bottle of Magnesium Citrate (cold).
   c) At 6 p.m. take 4 Dulcolax tablets with 8 oz. of liquid.

4. On The Day Of your examination:

   a) Drink at least 8 oz of coffee, tea or strained fruit juices, but no other breakfast.
   b) At least one hour before leaving for your examination, insert Dulcolax suppository into your rectum. Wait at least l5 minutes before evacuating.
   c) Report to the X-ray department at your appointed time.

5. The above time and date are being reserved specifically for you. Every attempt will be made to accommodate you. However, failure to observe the above time promptly may cause a delay. Be certain to allow enough transportation and/or parking time.

6. Please notify the X-ray department (598-6200) if you are unable to keep your appointment.

7. If you have a tendency to be constipated, it is advisable to drink a large amount of fluid and to take a mild laxative following this procedure.

Appendix 1-D

University of Washington Hospitals
Department of Radiology
INPATIENT
Information and Instructions
BARIUM ENEMA

A satisfactory barium enema examination depends on the colon being carefully cleansed and empty. It is therefore important that these instructions be followed carefully utilizing the 'Barium Enema Prep' kit available from the pharmacy.

If the patient has severe kidney disease, cramping abdominal pain, considerable diarrhea, severe intestinal bleeding, or inflammatory bowel disease, consult the patient's primary physician before proceeding with these instructions.

l. For Two Days Before the examination, a clear liquid diet is required.

2. On the Day Before the examination:

   a) At l, 3, 7, l0 p.m., and at bedtime, give 8 oz. clear liquids, in addition to the clear liquid diet.

   b) At 2 p.m., 8 oz. bottle of Magnesium Citrate (cold).

   c) At 6 p.m., 4 Dulcolax tablets with 8 oz. of liquid.

3. On the Day Of the examination:

   a) At least two hours before the examination insert l Dulcolax suppository. Retain for at least l5 minutes before evacuation.

   b) At least 8 oz. of coffee, tea or strained fruit juices, but no other breakfast is permitted. (Omit this if excretory urogram is to be performed on the same day.)

4. Please phone the X-ray Department (598-6200) if there are any questions regarding the appointment or preparation for the study.

Appendix 2

MONITORING AND TREATMENT FOR AUTONOMIC DYSREFLEXIA DURING CYSTOGRAPHY IN SPINAL CORD INJURY PATIENTS

Autonomic dysreflexia (AD) is a condition that can occur in patients with spinal cord injury above the 6th thoracic level, and results in rapid increases in blood pressure. Most cases subside by eliminating the noxious stimulus, however, the hypertension can be malignant and if left untreated, can result in seizures and subarachnoid or intracerebral hemorrhage.

AD occurs when stimuli from below the level of the injury (such as bladder distension) precipitates a sympathetic discharge including constriction of the splanchnic arterial system, resulting in a sharp rise in blood pressure. While vagal response to this generally slows the heart rate, it is usually insufficient to eliminate the hypertension.

ACUTE TREATMENT:

1. Remove noxious stimulus (drain bladder, remove catheter).

2. Sit patient upright; obtain BP.

3. If, after above maneuvers, the diastolic blood pressure remains >100, apply topical nitroglycerine 2% ointment, one to two-inch strip and rub in with gloved hand. Alternatively, give 10 mg nifedipine orally. Chew capsule and swallow liquid.

4. If blood pressure remains elevated, page the urology resident. If no response, page the rehabilitation medicine resident. If no response, page anesthesiology resident.

5. If blood pressure remains elevated, consider phentolamine (Regitine), 5 mg, i.v., slowly (1 mg for children).

Appendix 3-A

PREMEDICATION REGIMENS

Decision to use steroid premedication must be made jointly by the radiologist and primary care physician. If there is a patient history of active TB or active systemic fungal infection, consider not using the pretreatment of steroids and not using iodinated contrast; i.e. consider alternative imaging. Nonionic contrast medium must be used. Anesthesia standby should be requested in all patients with a history of severe pulmonary or cardiac complications from prior contrast injections.

Premedication regimen should include one of the following corticosteroid regimens:

A. Methylprednisolone (Medrol) 32 mg p.o. 12 and 2 hours prior to the study; nonionic contrast agent.
B. Prednisone, 50 mg, p.o., 13, 7, and 1 hour before the exam; nonionic contrast agent.
C. For patients in whom prolonged pretreatment is impossible, use a single pretreatment at least 6 hours prior to the study (IV or oral corticosteroid); nonionic contrast agent.
D. Finally, Benadryl 50 mg p.o. or I.M. 1 hour prior to the study ("on-call") may be added to regimes a, b, or c at the radiologists' discretion.

A premedication strategy should not be a substitute for the preadministration preparedness for treating a reaction, should one occur, as discussed in the *ACR Manual on Contrast Media*. Contrast reactions do occur despite any and all premedication prophylaxis. The radiologist must be prepared and able to treat these reactions. To reiterate: A lower osmolality, nonionic contrast agent **plus** a corticosteroid premedication regimen is recommended for patients who are “at risk” for a second reaction. For these patients, there is a slight chance that the recurrence may be more severe than the prior reaction; however, it is more likely that the reaction will be the same or less, or that there will be no recurrence. (Greenberger PA 1991)

References:

Cohan RH, Ellis JH, Dunnick NR. Use of low-osmolar agents and premedication to reduce the frequency of adverse reactions to radiographic contrast media: A survey of Society of Uroradiology. Radiology 1995; 1 94:357-364.

Greenberger PA, Patterson R. The prevention of immediate generalized reactions to radiocontrast media in high-risk patients. J Allergy Clin Immunol 1991; 87:867-872.

Greenberger PA, Patterson R, Tapio CM. Phophylaxis against repeated radiocontrast media reactions in 857 cases: Adverse experience with cimetidine and safety of beta-adrenergic antagonists. Arch Int Med 1985; 145:2197-2201.

Lasser EC, Berry CC, Mishkin M, et al. Pretreatment with corticosteroids to prevent adverse reactions to noionic contrast media. AJR 1994; 162:523-526.

Appendix 3-B

TREATMENT OF CONTRAST REACTIONS

In any contrast reaction, regardless of how minor, the radiologist must immediately be notified by the technologist or nurse. Do not remove the intravenous catheter until a physician has evaluated the patient. The patient should not be left alone and should not leave the department until checked again by the radiologist.

The HOSPITAL CODE TEAM should be called when any patient develops signs of airway compromise, cardiopulmonary failure, neurologic impairment, seizures, or hypotension that is not responding to treatment initiated by the radiology team.

Specific treatment:

Because of the need for IV access in treatment of many of the potential contrast reactions, the preferred method of administering contrast is via angiocatheter rather than butterfly needle.

A. Angina

1/150 grain (.4 mg) Nitroglycerin sublingual; may repeat every 3-4 minutes X 3; or topical nitroglycerine ointment.

Oxygen therapy (10 L/min. via mask)

B. Seizure

5 mg Valium IV slowly
Oxygen therapy (10 L/min. via mask)

C. Mild vasomotor symptoms - nausea, vomiting, warmth

Reassure patient (observe for progression to more serious reaction)

D. Mild cutaneous reaction - hives, local erythema

No treatment needed in most cases.
25-50 mg Benadryl p.o. or IV slowly, if symptoms bothersome to patient (note: Benadryl causes drowsiness)

E. Severe cutaneous reaction (erythema, urticaria): H-1 histamine blocker (diphenhydramine).

If there is persistence after the antihistamine, or if there is associated severe edema, add epinephrine: 1:1000 subcutaneously, 0.1-0.2 ml (0.1-0.2 mg). If patient is hypotensive, use low-dose epinephrine i.v., 1:10,000 dilution, 1 ml (0.1 mg) i.v. slowly over 2-5 min. Repeat as needed.

F. Bronchospasm - wheezing and shortness of breath

1. Mild

a. Oxygen (10L/min. via mask)
b. 2-3 slow, deep breaths with a beta-agonist metered dose inhaler (e.g., Alupent).

2. Moderate to Severe

a. Oxygen therapy (10 L/min via mask)

Drugs (use only if unsatisfactory response to beta-agonist inhaler)

b. Low dose epinephrine i.v.: over 2-5 minutes give 1 ml of the 1:10,000 solution i.v. (0.1 mg/ml). Repeat as needed. Titrate the IV epinephrine to effect. Not to exceed 1 mg total dose.

If patient does not respond to beta-agonist inhaler and epinephrine, call for assistance (CODE team); and consider adding:

c. Aminophylline 250 mg IV in 100 cc D5/W over 10-20 minutes (must be given very slowly to avoid hypotension)

G. Facial/laryngeal edema - stridor, hoarseness

Evaluate airway, oxygen by mask, 10 L/min.

Drugs

a. Low dose epinephrine i.v.: over 2-5 minutes give 1 ml of the 1:10,000 solution i.v. (0.1 mg/ml), which equals 20-50 mcg/minute. Titrate to effect. Not to exceed 1 mg total dose.
b. Epi-Pen intramuscularly (0.3 mg epinephrine is given with the automated injection)

Note: If not responding to initial treatment of airway compromise, call a CODE.

H. Severe hypotension, tachycardia or NSR

a. Check V.S., esp. pulse rate
b. Elevate legs (moves 700 ml fluid centrally)
c. IV fluids (N.S.): rapidly (key part of therapy)
d. Oxygen (10 L/min via mask)

If patient does not respond, call CODE; consider drugs:

e. Consider epinephrine: IV, 1:10,000 dilution, 1 ml (0.1 mg) slowly over 2-5 minutes; repeat as necessary; titrate to effect.

I. Vagal reaction - hypotension, bradycardia

a. Check V.S.
b. Elevate legs (returns 700 ml centrally)
c. IV fluids (N.S.): essential to treat hypotension
d. Oxygen therapy (10 L via mask)

If symptomatic bradycardia persists, add atropine:
e. Atropine: essential to correct bradycardia; large dose (1.0 mg) IV slowly (a small dose, e.g., 0.2-0.4 mg, may worsen bradycardia); wait 3-5 minutes and repeat if necessary up to a total of 2 mg in adults. Pulse rate response determines atropine dose.
f. In heart transplant patients, do not use atropine initially; go directly to epinephrine.

J. Hypertensive Reaction (see autonomic dysreflexia if appropriate etiology)

a. Oxygen (10 L/min via mask)
b. Nitroglycerin 2% ointment topically (rub in 1-2” strip of ointment; use gloved hand)

K. Cardiac Arrest

Call Code Team
ABC's - Airway, breath, compress
Establish adequate airway and ventilation
Initiate closed chest cardiac compression: 100 beats per minute. Current ACLS guidelines use only rapid chest compressions until intubation can be achieved.

IV route and fluids
EKG monitor: check need for defibrillation

Appendix 3-C

EXTRAVASATION OF CONTRAST MEDIUM

CONTRAST EXTRAVASATION FACTORS:

1. Conventional higher osmolar agents cause more problems than nonionic, LOCM.
2. Extent of extravasation is usually underestimated.
3. Some patients are at increased risk for damage:
   Those with peripheral vascular insufficiency, Raynaud's phenomenon; fragile skin.
4. Maximum reaction may not peak for 24-48 hrs.

TREATMENT:

1. **Involve** a departmental **nurse** in patient care and follow-up of the patient. (**Record** evaluation on Progress Notes for chart)
2. **Elevation** of extremity
   a. Above level of heart
   b. Until swelling resolves
3. **Cool or cold compresses** for first 6-12 hours
   a. Studies show cold to be more effective than heat.
   b. Follow with warm compresses for mild residual symptoms.
4. Hyaluronidase (Wydase)
   - Current UWMC Departmental policy on extravasation does not advocate its routine use.
5. **Observe patient** over 1-2 hour period. (If after hours, radiology resident on duty assumes care & monitoring of patient)
   - **Record** findings and follow-up care in Progress Notes of patient's chart)
6. Involve Plastic Surgery service for consultation if skin seems threatened, if vascular compromise, or if neurological symptoms; If skin injury considered likely, arrange for admission to Plastic Surgery Service.

FOLLOW-UP:

1. **Follow-up call** to patient next day by departmental nurse or the radiologist who was involved with the case. (**Record** evaluation and follow-up plans in Progress Notes of patient's chart)
2. **Follow-up visit** next day with either departmental nurse or radiologist, unless situation has resolved. (**Record** in Progress Notes of patient's chart)

Appendix 3-D

CONTRAST REACTION REPORT

[INCLUDE all adverse contrast effects that require treatment or observation of the patient, including extravasation and contrast-induced renal failure]

Date: _____

Time of Day: _____

Area in Department:
- ☐ Head CT
- ☐ Body CT
- ☐ Urography
- ☐ Angio
- ☐ MRI
- ☐ Other

Radiologist/Resident Involved: _____

Technologist: _____

Patient Name: _____

Patient #: _____

TYPE OF REACTION:
- ☐ Cutaneous
- ☐ Bronchospastic
- ☐ Anaphylaxis-like (generalized)
- ☐ Hypotension (only)
- ☐ Vasovagal
- ☐ Respiratory arrest
- ☐ Cardiac arrest
- ☐ Seizure
- ☐ Extravasation
- ☐ Renal failure (contrast induced)

Time interval between injection of
contrast agent and the onset of reaction (mins., hrs.)

TREATMENT: (Be specific) e.g. oxygen, suction, IV fluids, epinephrine (type and amount) atropine (type and amount) antihistamines, steroids (amount)

_____

_____

MANAGEMENT OF CONTRAST EXTRAVASATION:

- ☐ Elevation of extremity
- ☐ Cold compress
- ☐ Warm compress
- ☐ Hyaluronidase
  - Amount _____
  - Strength _____
  - How administered _____
- ☐ Consultation with Plastic Surgery service

CONTRAST-INDUCED RENAL FAILURE:

Pre-contrast creatinine level _____

☐Consultation with Nephrology service

FOLLOW-UP CARE:

Observation Period _____

Where:_____

How long: _____

Hospitalized: _____ Service _____

Attending Dr. _____

Post-contrast creatinine levels and dates: (if developed ATN)

_____

Follow-up telephone call to patient:

When: _____

By Whom: _____

Follow-up appointment:

When: _____

With whom: _____

PATIENT DEMOGRAPHICS:

Age:_____

Sex:_____

Previous History of any risk factors:

☐ previous reaction to contrast
☐ severe allergies
☐ asthma
☐ drug allergies
☐ food allergies
☐ Diabetes mellitus
    ☐ insulin
☐ severe cardiovascular disease
☐ sickle cell disease
☐ myeloma

Previous radiographic studies using intravascular contrast:

Type: _____

When: _____

Type of contrast medium:_____

Prior medication: _____

TYPE OF CONTRAST MEDIUM:

☐ ionic
☐ nonionic

Brand name: _____

Concentration:_____

AMOUNT of contrast medium injected: _____

APPENDIX 3E

UNIVERSITY OF WASHINGTON
CONTRAST MATERIAL INJECTION FOR YOUR EXAMINATION

Your doctor has requested that you have a special x-ray examination. As a rule, this test also requires injection of a contrast agent into your bloodstream. This contrast agent (also termed contrast medium, contrast material, or x-ray dye) shows up white on x-ray or CT scan images, and helps our radiologists look deeply within your body. While we could perform your examination without contrast medium, it would be less accurate.

The contrast agent is given through a needle or small plastic tube placed into a vein on the inside of your elbow or the back of your hand. Normally, contrast agents are considered quite safe and, for your examination, we will be using a type of contrast agent (nonionic) that causes even fewer reactions. However, injections of any substance carry a small risk of harm, including injury to a nerve, vessel or skin, or the possibility of infection. Contrast can occasionally cause kidney damage or may produce more generalized reactions. An example of a mild reaction to contrast would be sneezing or hives. Uncommonly (about one case in 2500), a severe reaction to the contrast agent occurs. The physicians and staff of this department are trained to treat these reactions. Very rarely (one case in 170,000), death has been caused by the use of a contrast agent. The risk of such a severe reaction is less than that from an injection of penicillin.

Certain patients are at higher risk for experiencing a reaction or adverse effect from the contrast agent, and we may need to change our procedures to help offset these higher risks. If any of the following describe you, please notify the technologist or radiologist so that they can plan your examination correctly:

1. Previously had an “allergic-type” reaction to contrast material
2. Active asthma
3. Many or severe allergies
4. Severe heart disease
5. Certain diseases (myeloma)
6. Kidney damage, especially when caused by diabetes mellitus (“sugar diabetes”)
7. Certain medications for your heart (beta-blockers, calcium-channel blockers)
8. Certain medications for diabetes (metformin[Glucophage])

If you have any questions, please ask the x-ray technologist or the radiologist.

APPENDIX 3F

INDICATIONS FOR SERUM CREATININE BEFORE IV CONTRAST:

☐ **Diabetes mellitus**

- ☐ insulin-dependent diabetes of more than two years duration
- ☐ non-insulin-dependent diabetes (NIDDM) of over five years duration (if on diabetic medication for that period)

☐ **Renal disease**

- History of "kidney disease," including recurrent urinary infections as an adult
- Multiple (more than two) episodes of kidney stone disease
- Family history of kidney failure
- Kidney tumor
- Kidney transplant

☐ **History of vascular surgery for atherosclerosis**

☐ **Medical Diseases:**

- Collagen vascular disease (e.g. periarteritis)
- Myeloma or other paraproteinemia syndrome
- Sickle cell disease
- Gout
- Liver transplant (pre- or post-)

☐ **Medications**

- ☐ metformin (Glucophage) for diabetes
- ☐ multiple antibiotics, especially nephrotoxic antibiotics such as aminoglycosides
- ☐ chronic use of NSAID (nonsteroidal anti-inflammatory drugs, e.g. ibuprofen)

☐ **AGE 75 or older**

Appendix 3G

CONTRAST MEDIA AVAILABLE AT UWMC

Contrast Agent	**Ionic/ Nonionic**	**Organically Bound Iodine in mg/ml (%)**	**Osmolality (mOsm/kg H_20)** (NI=285-305)	**Viscosity 37˚C (CPS)**
Conray 60 (iothalamate meglumine)	Ionic	282 28%	~ 1400	~ 4
Conray 43 (iothalamate meglumine)	Ionic	202 20%	~ 1000	~ 2
Renografin 60 (diatrizoate meglumine/ diatrizoate sodium)	Ionic	292 29%	1450	4.0
Renografin 76 (diatrizoate meglumine/ diatrizoate sodium)	Ionic	370 37%	1940	8.4
Reno-M-60 (diatrizoate meglumine)	Ionic	282 28%	1404	4.0
Reno-M-DIP (diatrizoate meglumine)	Ionic	141 14%	644	1.4
Hypaque 60 (diatrizoate meglumine)	Ionic	282 28%	~1400	4.0
Isovue-370 (injectable iopamidol)	Nonionic	370 37%	796	9.4
Isovue-300 (injectable iopamidol)	Nonionic	300 30%	616	4.7

Contrast Agent	**Ionic/ Nonionic**	**Organically Bound Iodine in mg/ml (%)**	**Osmolality (mOsm/kg H_20)** (Nl=285-305)	**Viscosity 37˚C (CPS)**
Omnipaque-350 (iohexol)	Nonionic	350 35%	862	11.1
Omnipaque-300 (iohexol)	Nonionic	300 30%	709	6.8
Optiray-350 (ioversol)	Nonionic	350 35%	792	9.0
Optiray-320 (ioversol)	Nonionic	320 32%	702	5.8
Visipaque-320 (injectable iodixanol)	Nonionic Isosmolar	320	290	11.8
Visipaque-270 (injectable iodixanol)	Nonionic Isosmolar	270	290	6.3
Gastrografin (oral diatrizoate meglumine/ diatrizoate sodium)	Ionic	367 37%		
Ethiodol (HSG or lymphography; ethiodized oil)		37% by weight		

Reference: Spataro RF. Radiol Clin N. Am 1984; 22:365-379.
Fischer HW. Radiology 1986; 159:561-563.