MSK

PROSCAN MRI ONLINE

MRI Bursae

The Zen of MRI

MRI

MSK

PROSCAN MRI ONLINE

Bursae (Capsule) –"The Zen of MRI"

Contents	Location	DDX
Synovium Metaplasia Blood Injection Pigment Degloving Tophus Body Amyloid	ITB Olecranon Iliopsoas Fundiform Pisotriquetral Subacromial, Subdeltoid Gastrocnemius, Semimembranosus Popliteus	Degloving Ganglion Capsular cyst Myxoid Adventitial

MSK

Reference Material Bursae



MSK

Important Medial Bursae of Knee

- Pes Anserine Bursa – Adjacent to Sartorius, Gracilis, & Semi-tendinosus Attachments, 1-2 cm Below Joint Line
- Medial (Tibial) Collateral Ligament Bursa – Between Deep & Superficial Layers MCL
- Iliotibial Band – Surrounds ITB

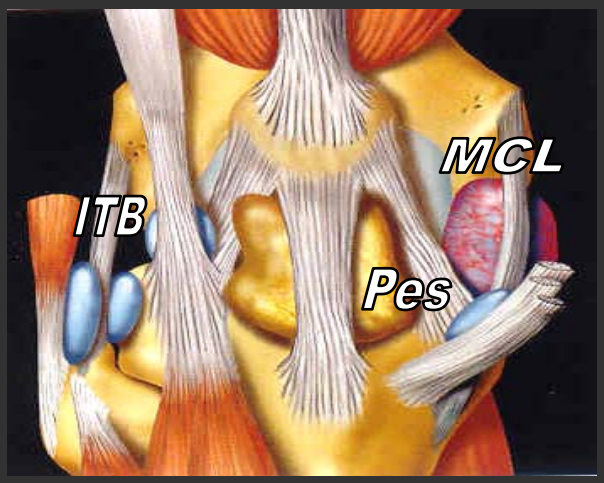

MSK

Important Medial Bursae of Knee

(From Stoller et al. Diagnostic Imaging: Orthopaedics. Salt Lake City: Amirsys, 2004.)

PROSCAN MRI ONLINE

- Tibiofibular Bursa –
- Popliteus Bursa – Behind Popliteus Tendon

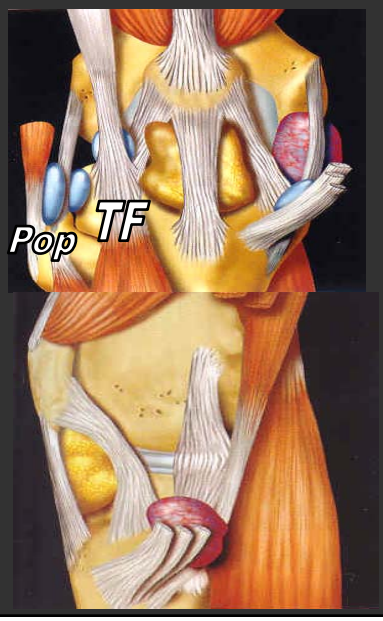

MSK

Gastrocnemius Semimembranosus Bursa

PROSCAN MRI ONLINE

- Size
- Dehiscence
- Metaplasia/ Bodies
- Pannus
- Four Fascicles
  - 1. Anteromedial: Simulates Meniscal Cyst
  - 2. Anterolateral: Simulates Popliteal Cyst
  - 3. Posterolateral: Most Common
  - 4. Posteromedial: Simulates Superficial Ganglion

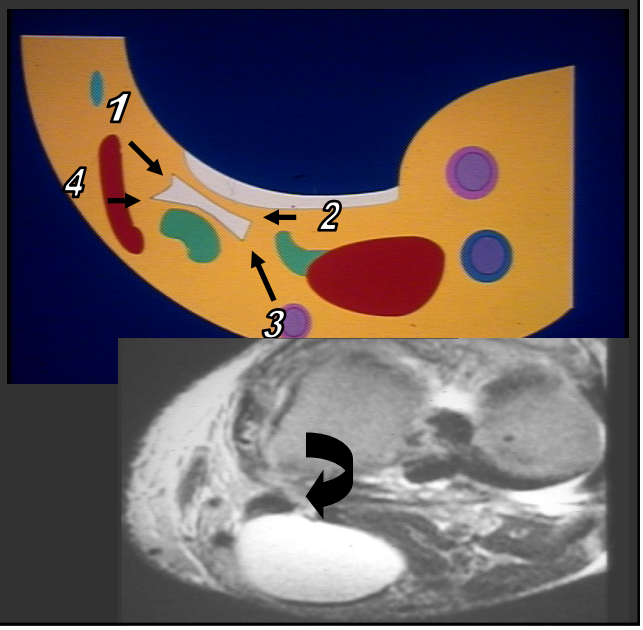

MSK

Pes Anserine Reference



MSK

"Trident Sign" of Pes Anserine Bursitis



