Note: This copy is for your personal non-commercial use only. To order presentation-ready copies for distribution to your colleagues or clients, contact us at www.rsna.org/rsnarights.

Juvenile versus Adult Osteochondritis Dissecans of the Knee: Appropriate MR Imaging Criteria for Instability[1]

Richard Kijowski, MD
Donna G. Blankenbaker, MD
Kazuhiko Shinki, MS
Jason P. Fine, PhD
Ben K. Graf, MD
Arthur A. De Smet, MD

Purpose: To retrospectively compare the sensitivity and specificity of previously described magnetic resonance (MR) imaging criteria for the detection of instability in patients with juvenile or adult osteochondritis dissecans (OCD) of the knee, with arthroscopic findings as the reference standard.

Materials and Methods: Informed consent was waived by the Institutional Review Board for this HIPAA-compliant study. The study group consisted of 32 skeletally immature patients (25 boys, seven girls; mean age, 14.4 years) with 36 juvenile OCD lesions of the knee and 33 skeletally mature patients (25 men, eight women; mean age, 26.2 years) with 34 adult OCD lesions of the knee. All patients had been evaluated with MR imaging and arthroscopy. MR studies were retrospectively reviewed by two radiologists in consensus to determine the presence of previously described MR imaging criteria for OCD instability (ie, high T2 signal intensity rim, surrounding cysts, high T2 signal intensity cartilage fracture line, and fluid-filled osteochondral defect). Sensitivity and specificity of the criteria were calculated separately for juvenile and adult OCD lesions.

Results: Separately, previously described MR imaging criteria for detection of OCD instability were 0%–88% sensitive and 21%–100% specific for juvenile OCD lesions and 27%–54% sensitive and 100% specific for adult OCD lesions. When used together, the criteria were 100% sensitive and 11% specific for instability in juvenile OCD lesions and 100% sensitive and 100% specific for instability in adult OCD lesions.

Conclusion: Previously described MR imaging criteria for OCD instability have high specificity for adult but not juvenile lesions of the knee.

© RSNA, 2008

[1] From the Departments of Radiology (R.K., D.G.B., A.A.D.S.), Biostatistics (K.S., J.P.F.), and Orthopedic Surgery (B.K.G.), University of Wisconsin Hospital, Clinical Science Center E3/311, 600 Highland Ave, Madison, WI 53792-3252. From the 2006 RSNA Annual Meeting. Received July 13, 2007; revision requested September 10; revision received October 12; final version accepted January 28, 2008. **Address correspondence to** R.K. (e-mail: *r.kijowski@hosp.wisc.edu*).

© RSNA, 2008

Osteochondritis dissecans (OCD) is a common source of knee pain and dysfunction in children and young adults. OCD of the knee most commonly involves, in order of decreasing frequency, the medial femoral condyle, the lateral femoral condyle, the femoral trochlea, and the patella (1–3). The exact etiology of OCD is presently unknown. Repetitive microtrauma is thought to be the primary mechanism responsible for the development of OCD (4–7). However, other causes, including acute trauma, ischemia, ossification abnormalities, and genetic factors, have also been proposed (4,8–14).

OCD of the knee is classically divided into juvenile and adult forms on the basis of the skeletal maturity of the patient (15,16). Juvenile OCD occurs in children and young adolescents who have open growth plates. Adult OCD occurs in older adolescents and young adults after the growth plates have closed. Although adult OCD may arise de novo, it is more commonly the result of an incompletely healed previously asymptomatic lesion from juvenile OCD (16). The separation of OCD of the knee into juvenile and adult forms is clinically relevant as the two pathologic conditions have distinctly different clinical courses. Juvenile OCD has a much better prognosis than does adult OCD, with higher rates of spontaneous healing after conservative therapy (17–22).

Magnetic resonance (MR) imaging is commonly used to assess the stability of OCD lesions of the knee. Stability is the single most important prognostic factor for determining the likelihood of an OCD lesion to heal with conservative therapy (15,18–25). Multiple previous studies (26–32) have described the MR imaging findings in patients with stable and unstable OCD lesions. However, to our knowledge, there is no consensus in the literature regarding the most appropriate MR imaging criteria for defining OCD instability. Previously published studies have not distinguished between patients with the juvenile and adult forms of the disease. Thus, this study was performed to retrospectively compare the sensitivity and specificity of previously described MR imaging criteria for indicating instability in patients with juvenile or adult OCD of the knee, by using arthroscopic findings as the reference standard.

Advances in Knowledge

- A high T2 signal intensity rim or cysts surrounding an adult osteochondritis dissecans (OCD) lesion are unequivocal signs of instability.
- A high T2 signal intensity rim surrounding a juvenile OCD lesion indicates instability only if it has the same signal intensity as adjacent joint fluid, is surrounded by a second outer rim of low T2 signal intensity, or is accompanied by multiple breaks in the subchondral bone plate on T2-weighted MR images.
- Cysts surrounding a juvenile OCD lesion indicate instability only if they are multiple or large in size.

Materials and Methods

Study Group

The study was performed in compliance with Health Insurance Portability and Accountability Act regulations and was approved by the Institutional Review Board; informed consent was waived.

The study group consisted of 32 skeletally immature patients (25 boys, seven girls; age range, 12–16 years; mean age, 14.4 years) with 36 juvenile OCD lesions of the knee and 33 skeletally mature patients (25 men, eight women; age range, 17–37 years; mean age, 26.2 years) with 34 adult OCD lesions of the knee. All of the subjects had been evaluated with MR imaging and arthroscopic knee surgery. The study group was selected from a database of MR examinations of the knee performed at our institution between January 1997 and August 2006. The database was used by one of the authors (R.K.) to identify 142 consecutive patients with OCD of the knee who had been evaluated with MR imaging. The medical records of these 142 patients were reviewed by the same author to identify 65 patients who had subsequently had arthroscopic surgery performed on their symptomatic knee. The 65 patients were classified as having juvenile or adult OCD on the basis of their skeletal maturity. To assess skeletal maturity, the MR images of each patient were reviewed in consensus by two of the authors (R.K., D.G.B.) to determine whether the distal femoral physis was open or closed, in accordance with previously described MR criteria (33–35).

Implication for Patient Care

- Revised guidelines for assessing the stability of OCD lesions of the knee by using MR imaging could assist in the clinical management of affected patients.

MR Examination

The 65 patients had undergone MR imaging of the knee by using a 1.5- (n = 63) or 3.0-T (n = 2) magnet (Signa HDx; GE Medical Systems, Milwaukee, Wis) and a phased-array extremity coil. All MR examinations consisted of an axial frequency-selective fat-suppressed T2-weighted fast spin-echo sequence (repetition time msec/echo time msec, 2000–4000/60–80), a coronal T1-weighted spin-echo sequence (400–1000/15–30), a coronal frequency-selective fat-suppressed intermediate-weighted fast spin-echo sequence

Published online before print
10.1148/radiol.2482071234

Radiology 2008; 248:571–578

Abbreviation:
OCD = osteochondritis dissecans

Author contributions:
Guarantors of integrity of entire study, R.K., D.G.B.; study concepts/study design or data acquisition or data analysis/interpretation, all authors; manuscript drafting or manuscript revision for important intellectual content, all authors; approval of final version of submitted manuscript, all authors; literature research, R.K., A.A.D.S.; clinical studies, R.K., D.G.B., B.K.G., A.A.D.S.; statistical analysis, K.S., J.P.F., A.A.D.S.; and manuscript editing, all authors

Authors stated no financial relationship to disclose.

(2000–4000/30–50), a sagittal intermediate-weighted fast spin-echo sequence (2000–4000/30–50), and a sagittal fluid-sensitive sequence. The sagittal fluid-sensitive sequence consisted of a frequency-selective fat-suppressed T2-weighted fast spin-echo sequence (2000–4000/60–80) in 57 examinations and a T2-weighted spin-echo sequence (2000–4000/60–80) in the remaining eight examinations. All MR examinations were performed with a field of view of 14–16 cm, a section thickness of 3–4 mm with an intersection gap of 1–1.5 mm, a matrix of 256 × 256, and two signals acquired.

Arthroscopic Knee Surgery

All 65 patients in the study group had arthroscopic surgery performed on their symptomatic knee within 2 months of their MR examination (range, 3–58 days; mean, 21.7 days; median, 19 days). All arthroscopic surgeries were performed by one of three orthopedic surgeons (including B.K.G.) at our institution who specialize in sports medicine and had 7–20 years of clinical experience at the time of the study. All OCD lesions were assessed for stability at the time of surgery. An OCD lesion was considered to be unstable at surgery if the articular cartilage overlying the lesion was disrupted or if the articular cartilage overlying the lesion was intact but the lesion was ballottable during surgical probing (26,27).

Review of MR Studies

The MR studies of all 65 patients were retrospectively reviewed in consensus by two fellowship-trained musculoskeletal radiologists (R.K., D.G.B.) who had 5–7 years of clinical experience interpreting musculoskeletal MR images at the time of the study. After a 12-month period, to prevent recall bias, the same two radiologists independently reviewed the MR studies of 35 patients (18 with juvenile OCD, 17 with adult OCD) who were randomly selected from the 65 patients in the study group. The Fisher exact test and Wilcoxon test were used to verify that there were no statistically significant differences between the 35 patients selected for the independent reading and the general study group with regard to the proportion of males and females, mean age, mean size of OCD lesions, proportion of juvenile and adult OCD lesions, and proportion of stable and unstable OCD lesions ($P \geq .774$). During both the consensus and independent readings, the radiologists were unaware of the surgical findings for each patient.

During the consensus reading, the radiologists documented the location and size of the OCD lesions. The size of the OCD lesions was measured in three planes by using electronic calibers on a workstation (ALI, version 5; Horizon Medical Imaging Systems, McKesson, San Francisco, Calif).

During both the consensus and independent readings, the radiologists documented the presence of four MR imaging criteria for OCD instability that were previously described by De Smet and colleagues (26,27). These MR imaging criteria are *(a)* a high-signal-intensity rim surrounding an OCD lesion on T2-weighted images (hereafter, "high T2 signal intensity"), *(b)* cysts sur-

Table 1

Sensitivity of MR Imaging Criteria for Instability in Juvenile and Adult OCD Lesions

Criterion	Sensitivity in Juvenile OCD Lesions (%)	Sensitivity in Adult OCD Lesions (%)	*P* Value*
High T2 signal intensity rim	88 (15/17) [64–99]	54 (14/26) [33–73]	.043
Cysts	47 (8/17) [23–72]	38 (10/26) [20–59]	.387
High T2 signal intensity cartilage fracture line	18 (3/17) [4–43]	35 (9/26) [17–56]	.808
Fluid-filled osteochondral defect	0 (0/17) [0–20]	27 (7/26) [12–48]	.055
All criteria together	100 (17/17) [81–100]	100 (26/26) [87–100]	NA

Note.—Numbers in parentheses were used to calculate percentages; 95% confidence intervals are in brackets.

* NA = not applicable.

Table 2

Specificity of MR Imaging Criteria for Instability in Juvenile and Adult OCD Lesions

Criterion	Specificity in Juvenile OCD Lesions (%)	Specificity in Adult OCD Lesions (%)	*P* Value*
High T2 signal intensity rim	21 (4/19) [6–46]	100 (8/8) [63–100]	.001
Cysts	68 (13/19) [43–87]	100 (8/8) [63–100]	.195
High T2 signal intensity cartilage fracture line	100 (19/19) [82–100]	100 (8/8) [63–100]	NA
Fluid-filled osteochondral defect	100 (19/19) [82–100]	100 (8/8) [63–100]	NA
All criteria together	11 (2/19) [1–33]	100 (8/8) [63–100]	<.001

Note.—Numbers in parentheses were used to calculate percentages; 95% confidence intervals are in brackets.

* NA = not applicable.

Table 3

Sensitivity and Specificity of Secondary MR Findings for Instability in Juvenile OCD Lesions Surrounded by Cysts

Secondary Finding	Sensitivity (%)	Specificity (%)
Multiple cysts	38 (3/8) [9–76]	100 (6/6) [54–100]
Single cyst >5 mm in diameter	25 (2/8) [3–65]	100 (6/6) [54–100]

Note.—Numbers in parentheses were used to calculate percentages; 95% confidence intervals are in brackets.

rounding an OCD lesion, *(c)* a high T2 signal intensity fracture line extending through the articular cartilage overlying an OCD lesion, and *(d)* a fluid-filled osteochondral defect.

During both the consensus and independent readings, the radiologists also documented the presence of secondary MR imaging findings for OCD lesions surrounded by a high T2 signal intensity rim or cysts. When there were cysts surrounding an OCD lesion, the radiologists characterized the cysts as single or multiple and measured the size of the largest cyst by using electronic calibers on a workstation (ALI, version 5; Horizon Medical Imaging Systems, McKesson). When there was a high T2 signal intensity rim surrounding an OCD lesion, the radiologists characterized the rim as having the same or lower signal intensity as adjacent joint fluid. The radiologists also documented the presence of a second outer rim of low T2 signal intensity surrounding the OCD lesion. In addition, the radiologists documented the presence of disruption of the subchondral bone plate overlying the OCD lesion. The subchondral bone plate was considered to be disrupted if its normal uniform low signal intensity was replaced by intermediate signal intensity on T1-weighted and intermediate-weighted MR images and by intermediate or high signal intensity on fat-suppressed intermediate-weighted and T2-weighted MR images. When there was disruption of the subchondral bone plate, the radiologists documented whether there were single or multiple breaks in the bone plate and with which sequences the breaks were identified.

Statistical Analysis

All statistical analyses were performed by using statistical software (R, version 2.3.1; *http://cran.r-project.org*).

The Fisher exact test was used to determine the relationship between the location and stability of the OCD lesions. Paired *t* tests were used to determine the relationship between the size and stability of the OCD lesions. Relationships were considered to be statistically significant if the *P* value was less than .05.

By using the data obtained from the consensus readings of the MR examinations, the sensitivity and specificity, with 95% confidence intervals, of previously described MR imaging criteria for OCD instability were determined for both juvenile and adult OCD lesions. Sensitivity and specificity values were calculated for each MR imaging criterion separately and for all MR imaging criteria together. When calculating sensitivity and specificity values for all MR imaging criteria together, an OCD lesion was considered to be unstable when any one criterion was present. Equality of proportion tests were used to compare sensitivity and specificity values between the two groups. Differences were considered to be statistically significant if the *P* value was less than .05. For juvenile OCD lesions surrounded by cysts and for juvenile OCD lesions surrounded by a high T2 signal

Figure 1

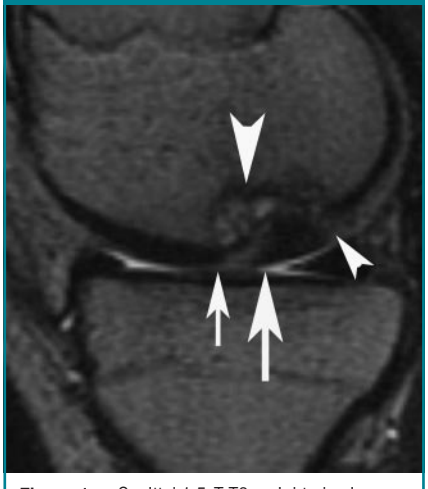

Figure 1: Sagittal 1.5-T T2-weighted spin-echo MR image of knee in 14-year-old girl with surgically confirmed unstable juvenile OCD lesion of medial femoral condyle. OCD lesion has heterogeneous intermediate and low signal intensity (large arrow) and is surrounded by multiple small cysts (large arrowhead). Low-signal-intensity subchondral bone plate is not disrupted at anterior edge of OCD lesion (small arrow) but is disrupted at posterior edge of lesion (small arrowhead).

Figure 2



Figure 2: Sagittal 1.5-T fat-suppressed T2-weighted fast spin-echo MR image of knee in 12-year-old girl with surgically confirmed stable juvenile OCD lesion of medial femoral condyle. OCD lesion has uniform low signal intensity (large arrow) and is surrounded by a single cyst 4 mm in maximal diameter (small arrow). There is no disruption of low-signal-intensity subchondral bone plate at edges of the OCD lesion (arrowheads).

Figure 3

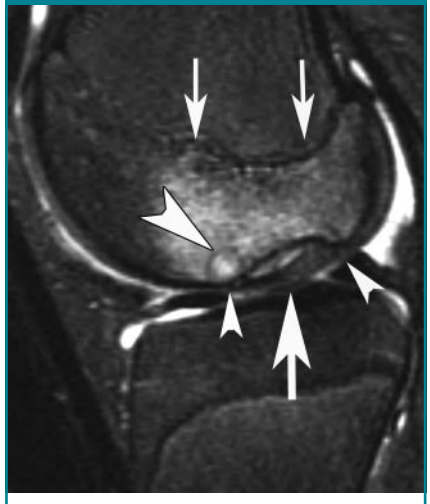

Figure 3: Sagittal 1.5-T fat-suppressed T2-weighted fast spin-echo MR image of knee in 15-year-old boy with surgically confirmed unstable juvenile OCD lesion of medial femoral condyle. OCD lesion has heterogeneous high and low signal intensity (large arrow) and is surrounded by a single cyst 6 mm in maximal diameter (large arrowhead) and extensive bone marrow edema (small arrows). There is no disruption of low-signal-intensity subchondral bone plate at edges of OCD lesion (small arrowheads).

intensity rim, the sensitivity and specificity of secondary MR imaging findings for determining OCD instability were calculated.

By using the data obtained from the independent readings of the MR studies, κ statistics with standard errors were used to assess interobserver agreement between the two radiologists for determining the presence of the MR imaging findings recorded in the study. A κ value of 0–0.20 was considered to indicate slight agreement; 0.21–0.40, fair agreement; 0.41–0.60, moderate agreement; 0.61–0.80, substantial agreement; 0.81–0.99, almost perfect agreement; and 1.00, perfect agreement (36).

Results

Surgical Findings

There were 70 OCD lesions of the knee evaluated at surgery. Forty-nine OCD lesions were located on the medial femoral condyle; 16, on the lateral femoral condyle; and five, on the lateral femoral trochlea. There were 36 juvenile OCD lesions. Nineteen juvenile OCD lesions were stable, and 17 juvenile OCD lesions were unstable at surgery. There were 34 adult OCD lesions of the knee. Eight adult OCD lesions were stable, and 26 adult OCD lesions were unstable at surgery.

MR Evaluation

There was no statistically significant relationship ($P = .149$) between the location and stability of the OCD lesions. There was no statistically significant difference ($P = .108$) between the mean size of stable (1859 mm^3) and unstable (2297 mm^3) OCD lesions.

When used together, the previously described MR imaging criteria had 100% sensitivity and 11% specificity for detection of unstable juvenile OCD lesions and 100% sensitivity and 100% specificity for detection of unstable adult OCD lesions (Tables 1, 2). The difference in the specificity of the MR imaging criteria for detection of unstable juvenile versus adult OCD lesions was statistically significant ($P < .001$).

In juvenile OCD lesions surrounded by cysts (Table 3), the presence of secondary MR findings (multiple cysts [Fig 1] and the presence of a single cyst greater than 5 mm in diameter [Figs 2, 3]) had low sensitivity but high specificity for detection of unstable lesions.

For determining instability in juvenile OCD lesions surrounded by a high T2 signal intensity rim (Table 4), the presence of a rim of fluid signal intensity, multiple breaks in the subchondral bone plate on T2-weighted images, and

Table 4

Sensitivity and Specificity of Secondary MR Imaging Findings for Instability in Juvenile OCD Lesions with a High T2 Signal Rim

Secondary Finding	Sensitivity (%)	Specificity (%)
Rim of fluid signal intensity	27 (4/15) [8–55]	100 (15/15) [78–100]
Multiple breaks in subchondral bone plate		
T1-weighted images	73 (11/15) [45–92]	20 (3/15) [4–48]
Intermediate-weighted images	100 (15/15) [78–100]	7 (1/15) [0–32]
Fat-suppressed intermediate-weighted images	53 (8/15) [27–79]	73 (11/15) [45–92]
T2-weighted images	67 (10/15) [38–88]	100 (15/15) [78–100]
Outer rim of low T2 signal intensity	53 (8/15) [27–79]	100 (15/15) [78–100]
All findings together*	100 (15/15) [78–100]	100 (15/15) [78–100]

Note.—Numbers in parentheses were used to calculate percentages; 95% confidence intervals are in brackets.

* Multiple breaks in subchondral bone plate determined on T2-weighted MR images.

Figure 4

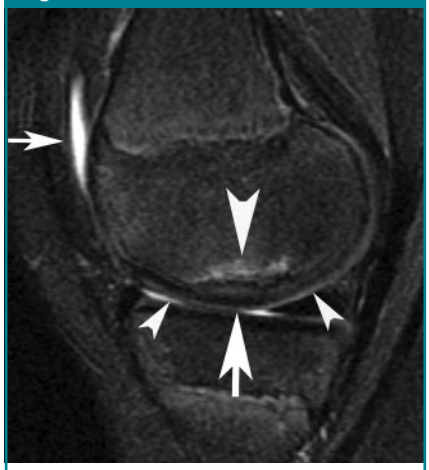

Figure 4: Sagittal 1.5-T T2-weighted spin-echo MR image of knee in 12-year-old girl with surgically confirmed stable juvenile OCD lesion of medial femoral condyle. OCD lesion has heterogeneous intermediate and low signal intensity (large arrow) and is surrounded by high T2 signal intensity rim (large arrowhead) that has lower signal intensity than adjacent joint fluid (small arrow). There is no disruption of low-signal-intensity subchondral bone plate at edges of OCD lesion (small arrowheads).

Figure 5



Figure 5: Sagittal 1.5-T fat-suppressed T2-weighted fast spin-echo MR image of knee in 14-year-old boy with surgically confirmed unstable juvenile OCD lesion of lateral femoral trochlea. OCD lesion has uniform low signal intensity (large white arrow) and is surrounded by inner rim of high T2 signal intensity (large white arrowhead) and second outer rim of low T2 signal intensity (black arrow). The high T2 signal intensity rim has same signal intensity as adjacent joint fluid (paired small arrowheads). There is also extensive bone marrow edema (paired small white arrows) surrounding lesion. Low-signal-intensity subchondral bone plate is not disrupted at the superior edge of the lesion (single small white arrow) but is disrupted at inferior edge of the OCD lesion (single small arrowhead).

76% of adult OCD lesions unstable at surgery, 46% of juvenile OCD lesions unstable at surgery. So higher prevalence of OCD unstable in adult

a second outer rim of low T2 signal intensity all had 100% specificity (Figs 4 and 5). When used together, these three secondary MR imaging findings had 100% sensitivity and 100% specificity for detection of unstable juvenile OCD lesions.

The κ values indicating interobserver agreement between the two radiologists are shown in Table 5. There was perfect agreement, almost perfect agreement, or substantial agreement between the two radiologists for determining the presence of all studied MR imaging findings.

Discussion

To our knowledge, no previous study has documented a difference in the MR imaging findings that predict instability between juvenile and adult cases of OCD of the knee. We believe that this lack of distinction between the juvenile and adult forms of the disease is responsible for the widespread differences of opinion in the literature regarding the most appropriate MR imaging criteria for OCD instability (26–32).

In our study, the presence of a high T2 signal intensity rim, cysts surrounding an OCD lesion, a high T2 signal intensity fracture line extending through the articular cartilage overlying an OCD lesion, or a fluid-filled osteochondral defect was an unequivocal sign of instability in patients with adult OCD of the knee. The MR imaging criteria for instability for adult OCD lesions in our study were identical to the criteria reported by De Smet et al (26,27), Mesgarzadeh et al (28), and Nelson et al (29). In one of the studies performed by De Smet et al (26), 17 of the 21 patients with surgically confirmed OCD were skeletally mature. The skeletal maturity of the patients in the studies performed by Mesgarzadeh et al (28) and Nelson et al (29) was not specified. However, the mean age of patients with OCD was 18 years in the study performed by Mesgarzadeh et al and 26.5 years in the study performed by Nelson et al. Thus, the patient population in both studies likely consisted mainly of skeletally mature individuals.

In our study, the presence of a high T2 signal intensity rim or cysts surrounding the OCD lesion was not an unequivocal sign of instability in patients with juvenile OCD of the knee. These findings are similar to the findings of studies performed by Yoshida et al (30), O'Connor et al (31), and Pill et al (32). Yoshida et al (30) reported a high T2 signal intensity rim and cysts surrounding OCD lesions of the knee, which eventually healed with conservative therapy, in 35 skeletally immature patients. O'Connor et al (31) described a high T2 signal intensity rim around surgically confirmed stable OCD lesions of the knee in 12 pediatric patients. Pill et al (32) reported a high T2 signal intensity rim and subchondral cysts surrounding OCD lesions of the knee in three of 13 skeletally immature patients who were successfully treated with conservative therapy.

The presence of cysts surrounding an OCD lesion was a nonspecific finding in patients with juvenile OCD of the knee. However, the number and size of the cysts may be useful for distinguishing between stable and unstable juvenile OCD lesions. In our study, the presence of multiple cysts and the presence of a single cyst greater than 5 mm in diameter both had a low sensitivity but high specificity for detection of unstable juvenile OCD lesions. De Smet et al (26,27) also used a size cutoff of 5 mm in their studies to distinguish between stable and unstable OCD lesions surrounded by a single cyst.

A high T2 signal intensity rim surrounding an OCD lesion was another nonspecific finding in patients with juvenile OCD of the knee. The most useful secondary MR imaging findings for distinguishing between stable and unstable juvenile OCD lesions with a high T2 signal intensity rim were a rim of fluid signal intensity, multiple breaks in the subchondral bone plate on T2-weighted MR images, and a second outer rim of low T2 signal intensity. The rim of fluid signal intensity surrounding an OCD lesion most likely represents fluid at the interface between the lesion and underlying cancellous bone. Multiple breaks in the subchondral bone plate on T2-weighted MR images most likely represent subchondral bone plate fractures. The exact cause of the second outer rim of low T2 signal intensity surrounding unstable OCD lesions is unknown. It may represent highly organized fibrous tissue or sclerotic bone at the interface between the OCD lesion and underlying cancellous bone. When used together in our study, these three secondary MR imaging findings had 100% sensitivity and 100% specificity for detection of unstable juvenile OCD lesions surrounded by a high T2 signal intensity rim.

The best method for evaluating patients with OCD of the knee remains controversial. Due to conflicting reports in the literature regarding the most ap-

Table 5

Interobserver Agreement between Two Radiologists for Presence of MR Findings

Finding	κ Value
High T2 signal intensity rim	1.000
Rim of fluid signal intensity	0.757 ± 0.149
Cysts	0.862 ± 0.099
Multiple cysts	0.873 ± 0.163
Single cyst >5 mm in diameter	1.000
High T2 signal intensity cartilage fracture line	1.000
Fluid-filled osteochondral defect	1.000
Multiple breaks in subchondral bone plate	
T1-weighted images	0.938 ± 0.063
Intermediate-weighted images	1.000
Fat-suppressed intermediate-weighted images	0.797 ± 0.095
T2-weighted images	0.800 ± 0.098
Outer rim of low T2 signal intensity	0.710 ± 0.117

propriate MR imaging criteria for defining OCD instability, some authors have recommended using direct or indirect MR arthrography for evaluating patients with OCD (37–39). Our findings suggest that when revised criteria for OCD instability that are chosen on the basis of the skeletal maturity of the patient are used, MR imaging may be more useful than previously reported for assessing the stability of both juvenile and adult OCD lesions. Future prospective studies with surgical correlation are needed to determine the accuracy of our revised MR imaging criteria for OCD instability and to directly compare the utility of MR imaging and MR arthrography in the evaluation of patients with OCD of the knee.

Our results support the finding of previous studies (17–22) that juvenile OCD has a much better prognosis than does adult OCD. In our study, there was a larger number of juvenile than adult OCD lesions that were stable and essentially healed at arthroscopic surgery. Furthermore, MR imaging findings that are associated with a poor patient prognosis (eg, cartilage fracture lines, osteochondral defects) (40) were noted in a smaller proportion of unstable juvenile than adult OCD lesions.

There are limitations to our study. One limitation is the presence of selection bias, as the MR imaging findings of only surgically confirmed OCD lesions were evaluated in our study. A second limitation was that arthroscopic knee surgery was performed as long as 2 months after the MR study in some patients. It is possible that some unstable OCD lesions may have healed and that some stable OCD lesions may have become unstable during the interval between the MR examination and surgery. Additional limitations of our study were the small number of juvenile OCD lesions surrounded by cysts and the small number of stable adult OCD lesions. A final limitation of our study was the subjective nature of the MR imaging findings used to assess the stability of OCD lesions.

In summary, juvenile and adult OCD lesions of the knee have different MR imaging criteria for instability. A high T2 signal intensity rim or cysts surrounding an adult OCD lesion are unequivocal signs of instability. A high T2 signal intensity rim surrounding a juvenile OCD lesion indicates instability only if it has the same signal intensity as adjacent joint fluid, is surrounded by a second outer rim of low T2 signal intensity, or is accompanied by multiple breaks in the subchondral bone plate on T2-weighted MR images. Cysts surrounding a juvenile OCD lesion indicate instability only if they are multiple or large in size.

References

1. Desai SS, Patel MR, Michelli LJ, Silver JW, Lidge RT. Osteochondritis dissecans of the patella. J Bone Joint Surg Br 1987;69:320–325.
2. Garrett JC, Kress KJ, Mudano M. Osteochondritis dissecans of the lateral femoral condyle in the adult. Arthroscopy 1992;8:474–481.
3. Linden B. The incidence of osteochondritis dissecans in the condyles of the femur. Acta Orthop Scand 1976;47:664–667.
4. Aichroth P. Osteochondritis dissecans of the knee: a clinical survey. J Bone Joint Surg Br 1971;53:440–447.
5. Linden B. Osteochondritis dissecans of the femoral condyles: a long-term follow-up study. J Bone Joint Surg Am 1977;59:769–776.
6. Mizuta H, Nakamura E, Otsuka Y, Kudo S, Takagi K. Osteochondritis dissecans of the lateral femoral condyle following total resection of the discoid lateral meniscus. Arthroscopy 2001;17:608–612.
7. Smillie IS. Treatment of osteochondritis dissecans. J Bone Joint Surg Br 1957;39-B:248–260.
8. Barrie HJ. Hypertrophy and laminar calcification of cartilage in loose bodies as probable evidence of an ossification abnormality. J Pathol 1980;132:161–168.
9. Caffey J, Madell SH, Royer C, Morales P. Ossification of the distal femoral epiphysis. J Bone Joint Surg Am 1958;40-A:647–654.
10. Campbell CJ, Ranawat CS. Osteochondritis dissecans: the question of etiology. J Trauma 1966;6:201–221.
11. Gardiner TB. Osteochondritis dissecans in three members of one family. J Bone Joint Surg Br 1955;37-B:139–141.
12. Langenskiold A. Osteochondritis dissecans resulting from cartilage fractures due to trauma in early childhood [in Finnish]. Duodecim 1955;71:232–239.
13. Mubarak SJ, Carroll NC. Familial osteochondritis dissecans of the knee. Clin Orthop Relat Res 1979;140:131–136.
14. Ribbing S. The hereditary multiple epiphyseal disturbance and its consequences for the aetiogenesis of local malacias: particularly the osteochondrosis dissecans. Acta Orthop Scand 1955;24:286–299.
15. Cahill BR. Osteochondritis dissecans of the knee: treatment of juvenile and adult forms. J Am Acad Orthop Surg 1995;3:237–247.
16. Garrett JC. Osteochondritis dissecans. Clin Sports Med 1991;10:569–593.
17. Cahill BR, Phillips MR, Navarro R. The results of conservative management of juvenile osteochondritis dissecans using joint scintigraphy: a prospective study. Am J Sports Med 1989;17:601–605.
18. Clanton TO, DeLee JC. Osteochondritis dissecans: history, pathophysiology, and current treatment concepts. Clin Orthop Relat Res 1982;167:50–64.
19. Glancy GL. Juvenile osteochondritis dissecans. Am J Knee Surg 1999;12:120–124.
20. Hefti F, Beguiristain J, Krauspe R, et al. Osteochondritis dissecans: a multicenter study of the European Pediatric Orthopedic Society. J Pediatr Orthop B 1999;8:231–245.
21. Twyman RS, Desai K, Aichroth PM. Osteochondritis dissecans of the knee: a long-term study. J Bone Joint Surg Br 1991;73:461–464.
22. Van Demark R. Osteochondritis dissecans with spontaneous healing. J Bone Joint Surg Am 1952;35:143–148.
23. Schenck RC Jr, Goodnight JM. Osteochondritis dissecans. J Bone Joint Surg Am 1996;78:439–456.
24. Robertson W, Kelly BT, Green DW. Osteochondritis dissecans of the knee in children. Curr Opin Pediatr 2003;15:38–44.
25. Kocher MS, Tucker R, Ganley TJ, Flynn JM. Management of osteochondritis dissecans of the knee: current concepts review. Am J Sports Med 2006;34:1181–1191.
26. De Smet AA, Fisher DR, Graf BK, Lange RH. Osteochondritis dissecans of the knee: value of MR imaging in determining lesion stability and the presence of articular cartilage defects. AJR Am J Roentgenol 1990;155:549–553.
27. De Smet AA, Ilahi OA, Graf BK. Reassessment of the MR criteria for stability of osteo-

chondritis dissecans in the knee and ankle. Skeletal Radiol 1996;25:159–163.

28. Mesgarzadeh M, Sapega AA, Bonakdarpour A, et al. Osteochondritis dissecans: analysis of mechanical stability with radiography, scintigraphy, and MR imaging. Radiology 1987;165:775–780.

29. Nelson DW, DiPaola J, Colville M, Schmidgall J. Osteochondritis dissecans of the talus and knee: prospective comparison of MR and arthroscopic classifications. J Comput Assist Tomogr 1990; 14:804–808.

30. Yoshida S, Ikata T, Takai H, Kashiwaguchi S, Katoh S, Takeda Y. Osteochondritis dissecans of the femoral condyle in the growth stage. Clin Orthop Relat Res 1998;346:162–170.

31. O'Connor MA, Palaniappan M, Khan N, Bruce CE. Osteochondritis dissecans of the knee in children: a comparison of MRI and arthroscopic findings. J Bone Joint Surg Br 2002;84:258–262.

32. Pill SG, Ganley TJ, Milam RA, Lou JE, Meyer JS, Flynn JM. Role of magnetic resonance imaging and clinical criteria in predicting successful nonoperative treatment of osteochondritis dissecans in children. J Pediatr Orthop 2003;23:102–108.

33. Borsa JJ, Peterson HA, Ehman RL. MR imaging of physeal bars. Radiology 1996;199: 683–687.

34. Craig JG, Cody DD, Van Holsbeeck M. The distal femoral and proximal tibial growth plates: MR imaging, three-dimensional modeling and estimation of area and volume. Skeletal Radiol 2004;33:337–344.

35. Craig JG, Cramer KE, Cody DD, et al. Premature partial closure and other deformities of the growth plate: MR imaging and three-dimensional modeling. Radiology 1999;210: 835–843.

36. Landis JR, Koch GG. The measurement of observer agreement for categorical data. Biometrics 1977;33:159–174.

37. Bohndorf K. Osteochondritis (osteochondrosis) dissecans: a review and new MRI classification. Eur Radiol 1998;8:103–112.

38. Kramer J, Recht MP, Imhof H, Stiglbauer R, Engel A. Postcontrast MR arthrography in assessment of cartilage lesions. J Comput Assist Tomogr 1994;18:218–224.

39. Kramer J, Stiglbauer R, Engel A, Prayer L, Imhof H. MR contrast arthrography (MRA) in osteochondrosis dissecans. J Comput Assist Tomogr 1992;16:254–260.

40. De Smet AA, Ilahi OA, Graf BK. Untreated osteochondritis dissecans of the femoral condyles: prediction of patient outcome using radiographic and MR findings. Skeletal Radiol 1997;26:463–467.