Marshmallow and Bagel Esophagram



Marshmallow and Bagel Barium Swallow Protocol for Assessing Esophageal Motility (MMBS)

1) Patient swallows single large bolus of barium in the upright position under fluoroscopic video esophagography. Barium is thinned with water to a 20% suspension.

2) Patient then placed in prone position at 15 degrees Trendelenburg

3) Patient is challenged with a food bolus using a mechanical soft (marshmallow) and then a solid (bagel) food bolus.
    i) Patient is given 1-2 normal marshmallows which can be chewed up followed by a swallow of thinned liquid barium from a straw. Adequate clearance is achieved with passage of marshmallow bolus with two or fewer wave strippings.
    ii) Patient is then given a normal sized bite of a bagel which can be chewed up followed by a swallow of thinned liquid barium from a straw. Adequate clearance is achieved with passage of bagel bite bolus with two or fewer wave strippings.

4) Failure defined as incomplete progression of peristaltic contractions or more than two wave strippings to clear food bolus.

Usage -

We use this in our center for an initial screen of patient's esophageal motility. If they are normal then we do not pursue further testing. If they are abnormal then we proceed to formal high resolution manometry. The premise of the study and attached article is that if they are normal on MMBS then they are normal and a good candidate for a LINX or 360 fundoplication.

Tripp Buckley, MD Stephanie Doggett, PA-C - UT Dell Med School

What is Linx?

Linx is a string of magnetic beads, which stretch/expand to allow a bolus to pass, then return to baseline to prevent reflux (like an elastic band). We should see this expansion at fluoro.

Patient to the left showed no expansion - the marshmallow stayed above the Linx device, and the device never changed its diameter

Lack of expansion means a fibrotic sleeve has formed around the device. Surgeon plans to dilate this to break up the fibrosis.

Patients are asked to eat 1 bite off firm solids every hour for a week or 2 after surgery, so that as the device heals in, it is still has room to expand.



How Does the LINX System Work?

The LINX System is a small flexible band of interlinked titanium beads with magnetic cores. The magnetic attraction between the beads is intended to help the LES resist opening to gastric pressures, preventing reflux from the stomach into the esophagus. (See Fig. 1) LINX is designed so that swallowing forces temporarily break the magnetic bond, allowing food and liquid to pass normally into the stomach. (See Fig. 2) Magnetic attraction of the device is designed to close the LES immediately after swallowing, restoring the body's natural barrier to reflux. (See Fig. 3).

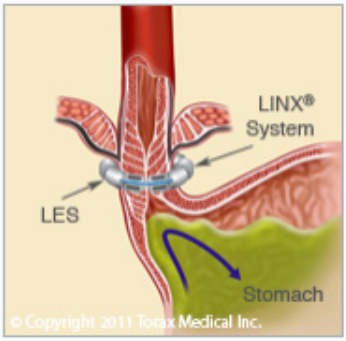

Figure 1: The LINX System is designed to help the LES resist opening to gastric pressures.

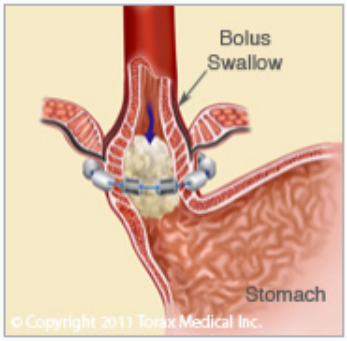

Figure 2: The LINX System is designed to expand to allow for normal swallowing.

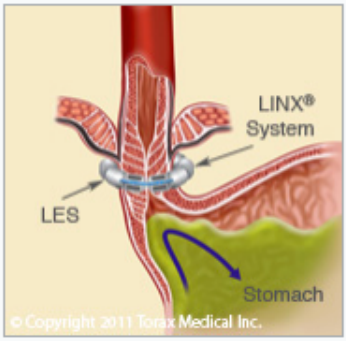

Figure 3: Magnetic attraction of the device is designed to close the LES immediately after swallowing.

MACRO

There is now a "Marshmallow/Bagel" template that launches in powerscribe when one of these studies comes up in ARA--a unique exam code was developed for these cases. It has all the buzz works the surgeons want and there are pick lists for abnormal findings in the "mechanical soft" and "solid" fields.

For now, the hospitals do not have a unique exam code for these studies, so if one comes up, you can insert the appropriate macro as needed, "Barium Swallow-Marshmallow..."

CLINICAL HISTORY: [ ].

COMPARISON: None available.

FINDINGS:

[The patient ingested thin barium as well as a marshmallow and a bite of bagel.] The exam was monitored under fluoroscopy.

Fluoro Time: [ ] minutes.
Fluoro Images: [ ]

Esophageal peristalsis and emptying were examined in prone horizontal and prone 15 degrees Trendelenburg positions.

Initial single large bolus of barium: [Peristalsis was first observed during a single large bolus swallow of barium. Normal uninterrupted progression of the contraction wave and complete emptying of the esophagus with two or fewer stripping waves. Incomplete emptying of the upper third of the esophagus was not considered abnormal.]

Mechanical soft (marshmallow) bolus: *normal default* [Ingestion of the food bolus followed by thin liquid barium. Adequate clearance was identified with clearing of the food bolus with two or fewer stripping motions.] *Abnormal pick list option: [Ingestion of the food bolus followed by thin liquid barium. Failure to clear the esophagus with incomplete progression of peristaltic contractions and observed the need for repeated (more than two) stripping motions for clearance.]*

Solid (bagel) bolus: *normal default* [Ingestion of the food bolus followed by thin liquid barium. Adequate clearance was identified with passage of the food bolus with two or fewer stripping motions.]
Abnormal pick list option: [Ingestion of the food bolus followed by thin liquid barium. Failure to clear the esophagus with incomplete progression of peristaltic contractions and observed the need for repeated (more than two) stripping motions for clearance.]

Other: [Normal esophageal caliber. No evidence of hiatal hernia, reflux, stricture or esophagitis.]

[The patient swallowed the radiopaque tablet without difficulty.]

IMPRESSION:
[Normal barium swallow. Normal esophageal motility was observed with adequate clearing of the mechanical soft and solid food boluses with two or fewer stripping motions.]

LINX and MRI

How will I know post-implant which LINX device I have?

- Patients implanted with LINX **PRIOR** to May 22, 2015 have been implanted with the 0.7T device.
- If you were implanted with LINX **AFTER** May 22, 2015 please check your implant card: Blue card (below) for 1.5T device; White card (below) for 0.7T device.
- Contact the surgeon who performed your LINX procedure.

