RadioGraphics

Imaging Appearances of Lateral Ankle Ligament Reconstruction[1]

Alexander J. Chien, MD • Jon A. Jacobson, MD • David A. Jamadar, MB,BS, FRCS, FRCR • Monica Kalume Brigido, MD • John E. Femino, MD • Curtis W. Hayes, MD

Six patients were retrospectively identified as having undergone lateral ligament reconstruction surgery. The surgical procedures were categorized into four groups: direct lateral ligament repair, peroneus brevis tendon rerouting, peroneus brevis tendon loop, and peroneus brevis tendon split and rerouting. At radiography and magnetic resonance (MR) imaging, the presence of one or more suture anchors in the region of the anterior talofibular ligament indicates direct ligament repair, whereas a fibular tunnel indicates peroneus brevis tendon rerouting or loop. Both ultrasonography (US) and MR imaging demonstrate rerouted tendons as part of lateral ankle reconstruction; however, MR imaging can also depict the rerouted tendon within an osseous tunnel if present, especially if T1-weighted sequences are used. Artifact from suture material may obscure the tendon at MR imaging but not at US. With both modalities, the integrity of the rerouted peroneus brevis tendon is best evaluated by following the tendon proximally from its distal attachment site, which typically remains unchanged. The rerouted tendon or portion of the tendon can then be traced proximally to its reattachment site. Familiarity with the surgical procedures most commonly used for lateral ankle ligament reconstruction, and with the imaging features of these procedures, is essential for avoiding diagnostic pitfalls and ensuring accurate assessment of the ligament reconstruction.

©RSNA, 2004

Abbreviations: CFL = calcaneofibular ligament, TFL = talofibular ligament

Index terms: Ankle, anatomy, 46.92 • Ankle, MR, 46.1214 • Ligaments, 46.486

RadioGraphics 2004; 24:999–1008 • **Published online** 10.1148/rg.244035723 • **Content Codes:** MR MK US

[1]From the Department of Radiology, Pomona Valley Hospital and Medical Center, Pomona, Calif (A.J.C.); the Departments of Radiology (J.A.J., D.A.J., M.K.B.) and Orthopaedic Surgery (J.E.F.), University of Michigan Medical Center, 1500 E Medical Center Dr, TC-2910G, Ann Arbor, MI 48109-0329; and the Department of Radiology, Medical College of Virginia/Virginia Commonwealth University, Richmond, Virginia (C.W.H.). Received September 4, 2004; revision requested December 11 and received February 23, 2004; accepted March 8. **Address correspondence to** J.A.J. (e-mail: *jjacobsn@umich.edu*).

©RSNA, 2004

Introduction

The appearance of the ankle following lateral ankle ligament reconstruction can be confusing because numerous surgical procedures are performed for ankle stabilization (1–4). Familiarity with the more common surgical procedures and their imaging appearances is essential to avoid diagnostic pitfalls such as misinterpreting postsurgical changes as (for example) tendon or bone disease and to ensure accurate assessment of the ligament reconstruction.

The ligaments about the ankle joint maintain the anatomic alignment of the ankle mortise (Fig 1). Ankle injuries most commonly occur when the supinated foot inverts and the weight of the body continues moving forward (5). Under these circumstances, the lateral ligaments of the ankle bear all of the inversion pressure on the foot, and ligament injury may occur. The most frequently injured lateral ankle ligament is the anterior TFL (66% of cases), followed by a combination of this ligament and the CFL (20%) (5). The posterior TFL is rarely disrupted from inversion injury, unless such injury is accompanied by ankle dislocation (3).

Initial management of acute ankle sprain consists of rest, ice, compression, and elevation (the "RICE" regimen), followed by early controlled motion with a functional brace (3). However, up to 20% of patients may experience symptoms of functional ankle instability (3). Surgery for lateral ankle ligament injury is usually performed in patients who sustain multiple recurrent inversion ankle sprains despite undergoing conservative treatment (eg, bracing, rehabilitation) (3,5).

One surgical treatment for lateral ankle ligament abnormality involves direct repair of the anterior TFL, and possibly of the CFL if it also is torn (3). Adjacent soft tissues (eg, tendon, retinaculum) may be used to stabilize the lateral ankle by being either attached to bone or rerouted through bone tunnels to stabilize the osseous structures. Most patients do not require additional soft-tissue augmentation, but only direct repair of the anterior TFL and possibly of the CFL (3). However, adjacent soft tissues are typically used to augment ligament repair in cases of severe ankle laxity, including subtalar laxity (3). The peroneus brevis tendon has been used for this purpose.

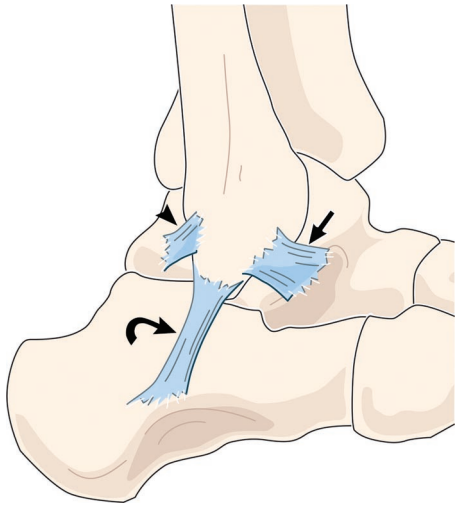

Figure 1. Drawing of the lateral ankle illustrates the normal anterior talofibular ligament (TFL) (straight arrow), calcaneofibular ligament (CFL) (curved arrow), and posterior TFL (arrowhead).

More than 50 procedures or modifications of procedures designed to stabilize the lateral ankle have been described (4). We categorized the more common procedures into four groups: direct lateral ligament repair, peroneus brevis tendon rerouting, peroneus brevis tendon loop, and peroneus brevis tendon split and rerouting.

In this article, we discuss and illustrate these surgical procedures and their imaging appearances at radiography (anteroposterior, lateral, oblique), ultrasonography (US), and magnetic resonance (MR) imaging.

Patients and Procedures

We obtained Institutional Review Board approval prior to initiating this study, then conducted a retrospective search of radiology reports between June 2000 and July 2002 and identified six patients (four females and two males; average age, 36.5 years; age range, 19–55 years) who had undergone some type of lateral ankle ligament reconstruction surgery. All available images were then retrospectively reviewed.

US images were acquired with 10- and 12-MHz linear transducers (HDI 5000; Philips ATL Medical Systems, Bothell, Wash) by a fellowship-trained musculoskeletal radiologist with 13 years of experience in musculoskeletal US. Gel was used in place of a standoff pad. Tendons were

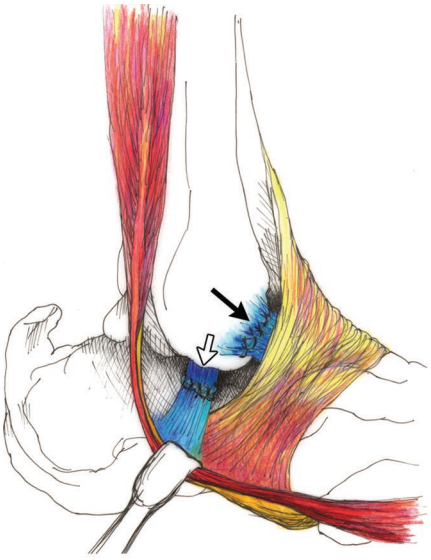

2.

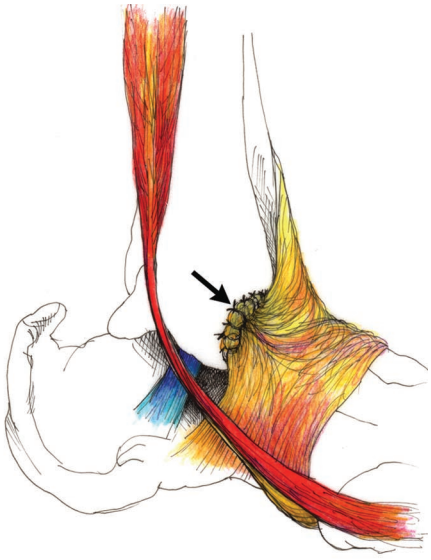

3.

Figures 2, 3. **(2)** Drawing illustrates direct repair of the anterior talofibular (solid arrow) and calcaneofibular (open arrow) ligaments. The peroneus brevis tendon is shown in red and the peroneus longus tendon in yellow. **(3)** Drawing illustrates repair of the anterior TFL with retinaculum attachment to the fibula (arrow). As in Figure 2, the peroneus brevis tendon is shown in red and the peroneus longus tendon in yellow.

identified on the basis of their characteristic fibrillar hyperechoic echotexture and ligaments on the basis of their more compact fibrillar hyperechoic echotexture. Each structure was identified and imaged transverse and perpendicular to its long axis. The anterior TFL was identified in the axial plane between the distal fibula and adjacent talus. The CFL was seen to course obliquely from the tip of the fibula toward the heel.

MR images were acquired using a 1.5-T magnet (Signa; GE Medical Systems, Waukesha, Wis) with the patient supine. These images included *(a)* axial and sagittal spin-echo T1-weighted images (echo time msec/repetition time msec = 9–14/500–700, 12–14-cm field of view, 3-mm-thick sections at 1-mm intervals, 256 × 192 matrix, two or three signals acquired), *(b)* axial and coronal fat-saturated fast spin-echo intermediate-weighted images (40/3,000, 12–14-cm field of view, 3-mm-thick sections at 1-mm intervals, 256 × 192 matrix, three signals acquired, echo train of eight to 10), and *(c)* sagittal short inversion time inversion-recovery images (17/4,000, inversion time msec = 150, 14-cm field of view, 4-mm-thick sections at 0.5-mm intervals, 256 × 160 matrix, four or five signals acquired).

Direct Lateral Ligament Repair

The Broström procedure involves direct repair of the anterior TFL whereby the two ends of the torn ligament are shortened, brought in close apposition, and sutured together (Fig 2) (5–7). In 30% of patients, similar direct repair of the CFL for ligament injury or laxity is also performed (3). The lateral extensor retinaculum and possibly the lateral talocalcaneal ligament (if present as a discrete structure) may be used to reinforce the strength of the repair (modified Broström procedure), especially when extreme or subtalar laxity is present (Fig 3) (3). Another modification involves the use of periosteal flaps to further augment the direct ligament repair (3).

At radiography, suture anchors may be found in the region of the anterior TFL (Fig 4a). At MR imaging, artifact from the sutures and suture anchors can be seen in this region; however, one pitfall is that magnetic susceptibility artifact at the point where the anterior TFL attaches to the fibula can simulate a fibular tunnel (Fig 4b, 4c). At US, shadowing from suture material can be seen (Fig 4d), and intact compact and hyperechoic ligament fibers can be seen between the fibula and talus.

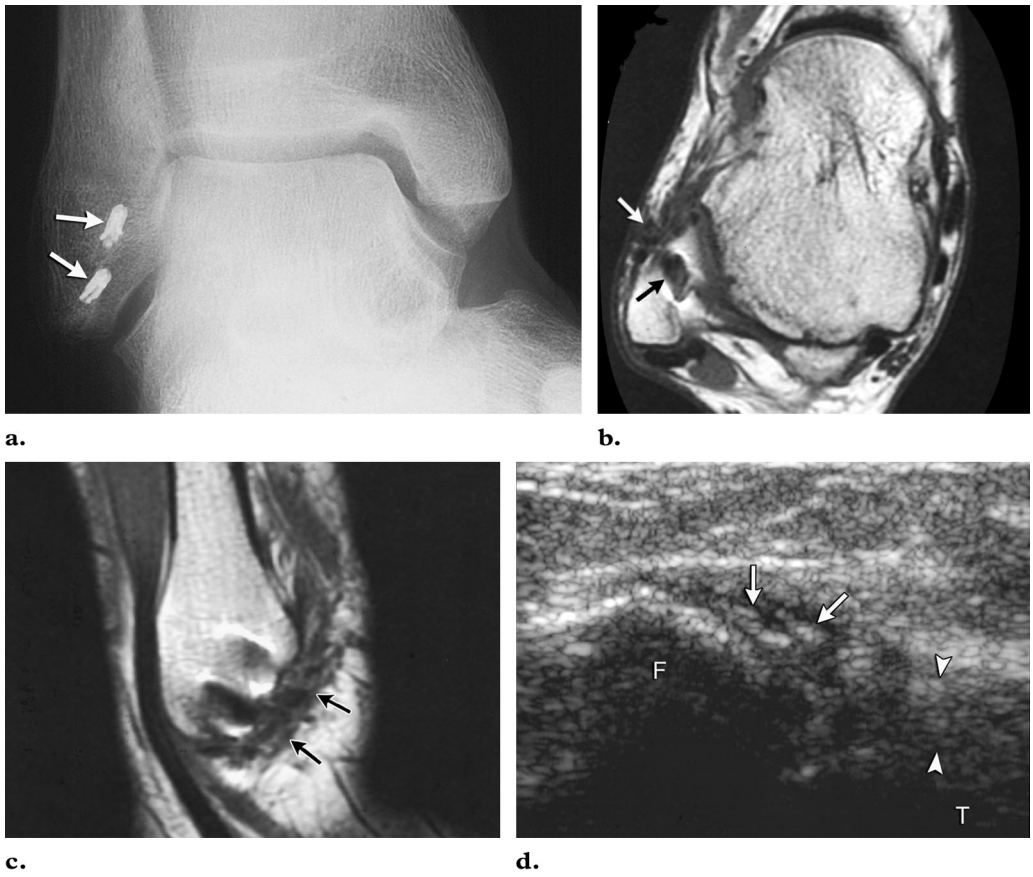

Figure 4. Direct anterior TFL repair (Broström procedure) in a 34-year-old man. **(a)** Oblique radiograph of the ankle shows two suture anchors at the distal fibula (arrows) with no osseous tunnel. **(b, c)** Axial **(b)** and sagittal **(c)** T1-weighted MR images show artifact from suture anchors at the distal fibula in the region of the anterior TFL (arrows). The peroneal tendons are intact. **(d)** Longitudinal US image shows the normal anterior TFL with a compact fibrillar echotexture (arrowheads) and echogenic suture material (arrows). *F* = fibula, *T* = talus.

Peroneus Brevis Tendon Rerouting

In peroneus brevis tendon rerouting, the tendon is transected above the ankle, rerouted in a distal-to-proximal direction through a surgically created tunnel in the fibula, and then reattached at the initial transection site (Fig 5). This procedure represents a modification of the original Evans procedure, in which the transected peroneus brevis tendon is directly attached to the distal fibula (3,5,7,8) and is used to reconstruct the anterior TFL (4).

One clue at imaging that this procedure has been performed is the presence of an oblique vertical fibular tunnel, which typically courses cephalad in the fibula from anterior to posterior (Fig 6a, 6b). At MR imaging and US, the rerouted peroneus brevis tendon can be followed proximally from the fifth metatarsal bone and identified entering the osseous tunnel at the fibular tip.

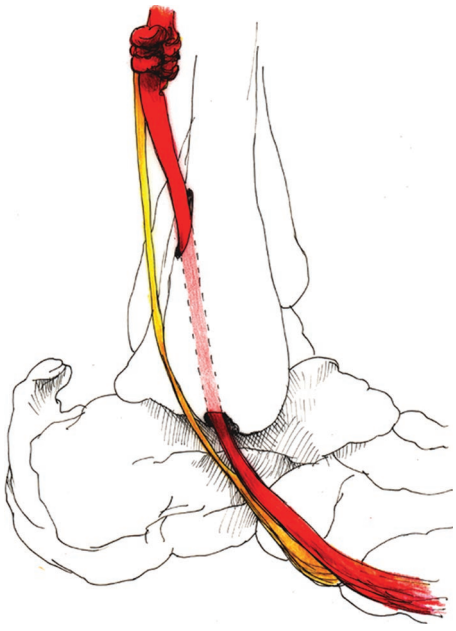

Figure 5. Drawing shows rerouting of the peroneus brevis tendon (red) through a fibular tunnel (dashed lines) with proximal reattachment (Evans procedure). The peroneus longus tendon is shown in yellow.

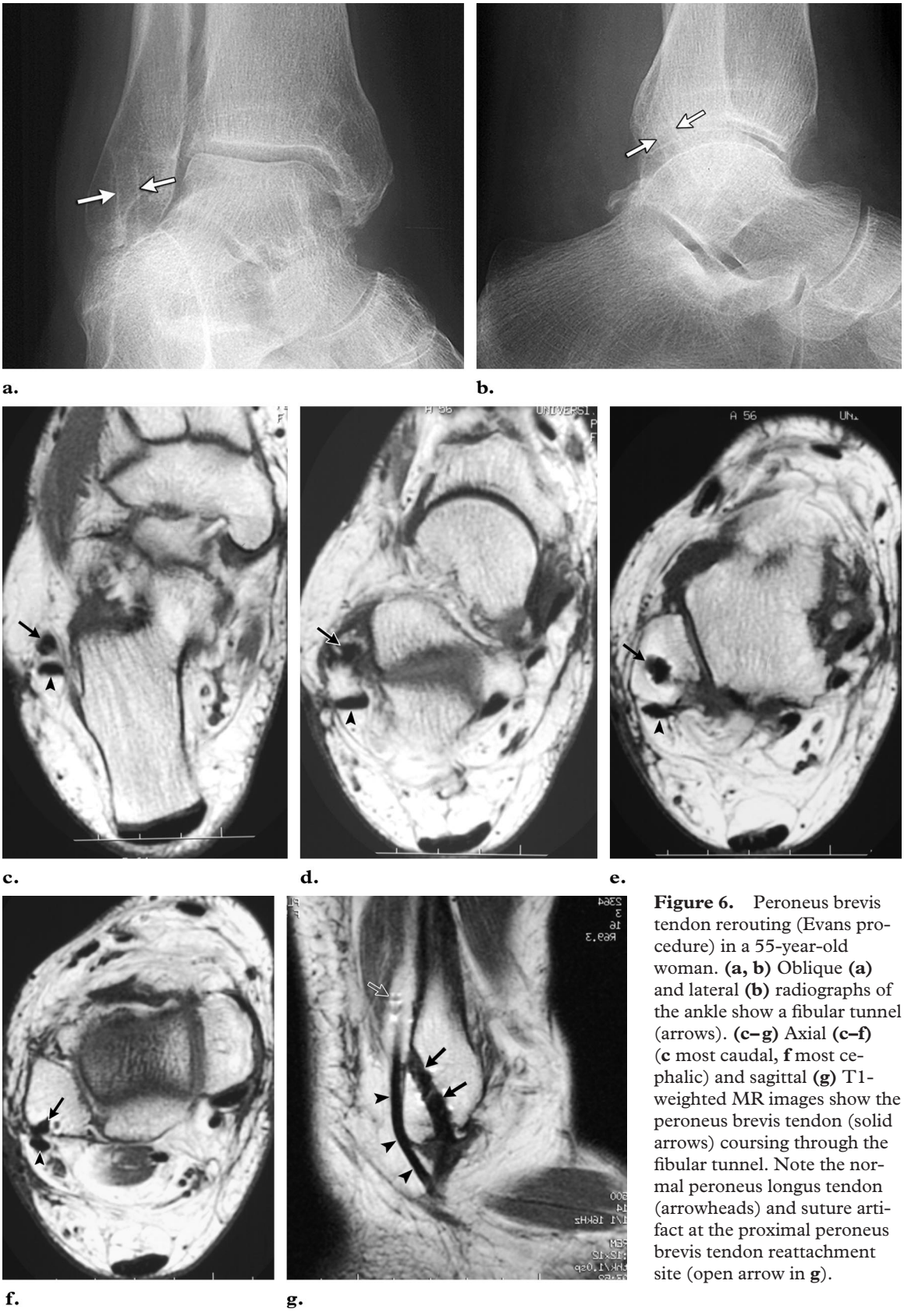

Figure 6. Peroneus brevis tendon rerouting (Evans procedure) in a 55-year-old woman. **(a, b)** Oblique **(a)** and lateral **(b)** radiographs of the ankle show a fibular tunnel (arrows). **(c–g)** Axial **(c–f)** (**c** most caudal, **f** most cephalic) and sagittal **(g)** T1-weighted MR images show the peroneus brevis tendon (solid arrows) coursing through the fibular tunnel. Note the normal peroneus longus tendon (arrowheads) and suture artifact at the proximal peroneus brevis tendon reattachment site (open arrow in **g**).

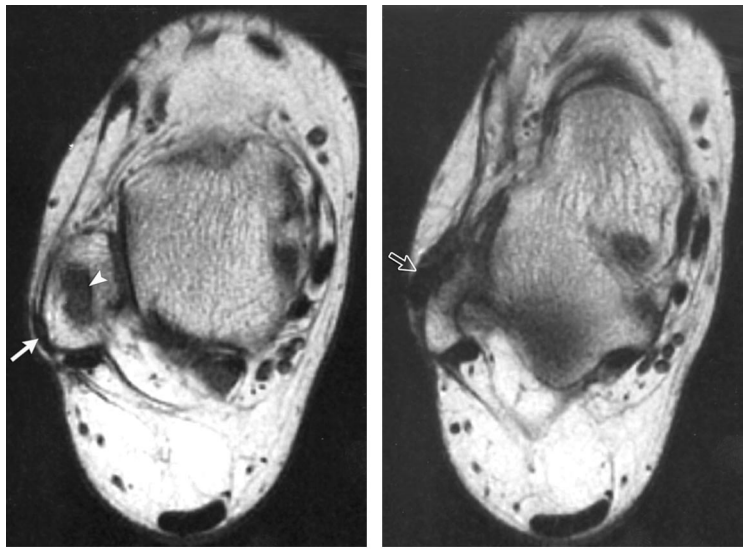

Figure 9. Peroneus brevis tendon loop (Lee procedure) in a 22-year-old woman. Sequential axial T1-weighted MR images (**b** obtained inferior to **a**) show one segment of the peroneus brevis tendon loop lateral to the fibula (arrow in **a**) and another segment coursing through a fibular tunnel (arrowhead in **a**) above the level of the tendon anastomosis (arrow in **b**).

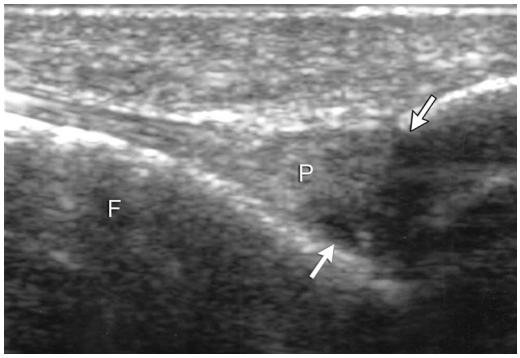

Figure 7. Peroneus brevis tendon rerouting (Evans procedure) in a 42-year-old woman. Longitudinal US image of the fibular diaphysis *(F)* shows the peroneus brevis tendon *(P)* entering the proximal end of a fibular tunnel (arrows). (Left side of image is superior, right side is inferior, top is lateral.)

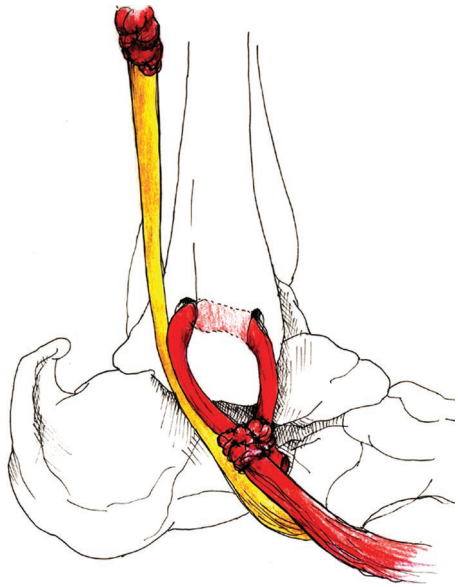

Figure 8. Drawing illustrates the peroneus brevis tendon loop (Lee procedure). Note the rerouting of the tendon (red) through a fibular tunnel (dashed lines) with distal reattachment. The peroneus longus tendon is shown in yellow.

The tendon exits more superiorly from the posterior end of the fibular tunnel (Fig 6c–6g, 7) and continues cephalad. Artifact from suture material may be seen at the proximal peroneus tendon reattachment site.

Peroneus Brevis Tendon Loop

In the creation of a peroneus brevis tendon loop, the tendon is transected above the ankle and rerouted through the fibula but is not reattached at the initial transection site. Instead, it is looped around the distal fibula and sutured distally back upon itself. The Lee procedure (Fig 8) is an example of this surgery (5,7), which is performed to reconstruct the anterior TFL (4).

As with peroneus brevis tendon rerouting, a fibular tunnel with an anteroposterior orientation is seen. At cross-sectional imaging (Figs 9, 10), the peroneus brevis tendon can be traced proximally from the base of the fifth metatarsal bone and then identified at the lateral aspect of the lateral malleolus. The tendon can be seen entering the posterior end of the fibular tunnel. It exits the anterior end of the tunnel and is sutured distally upon itself near the fibular tip. A segment of periosteum from the distal fibula may be used to reinforce the reconstruction site. Artifact from additional suture material can be seen at the proximal

Figure 10. Peroneus brevis tendon loop (Lee procedure) in a 47-year-old man. **(a)** Oblique radiograph of the ankle shows a distal fibular tunnel (arrows). **(b)** Axial computed tomographic scan of the ankle obtained after air-contrast arthrography shows one segment of the peroneus brevis tendon loop lateral to the fibula (arrow) and another segment coursing through the fibular tunnel (arrowhead) (cf Fig 9). **(c)** Longitudinal US image shows a segment of the distal peroneus brevis tendon (arrows) entering the fibular tunnel. *F* = fibula, *PL* = adjacent normal peroneus longus tendon. (Left side of image is proximal.) **(d, e)** Transverse US images show one segment of the peroneus brevis tendon loop (arrow in **d**) lateral to the fibula *(F)*, another segment entering the fibular tunnel (arrowhead), and a distal tendon anastomosis with echogenic suture material (arrow in **e**).

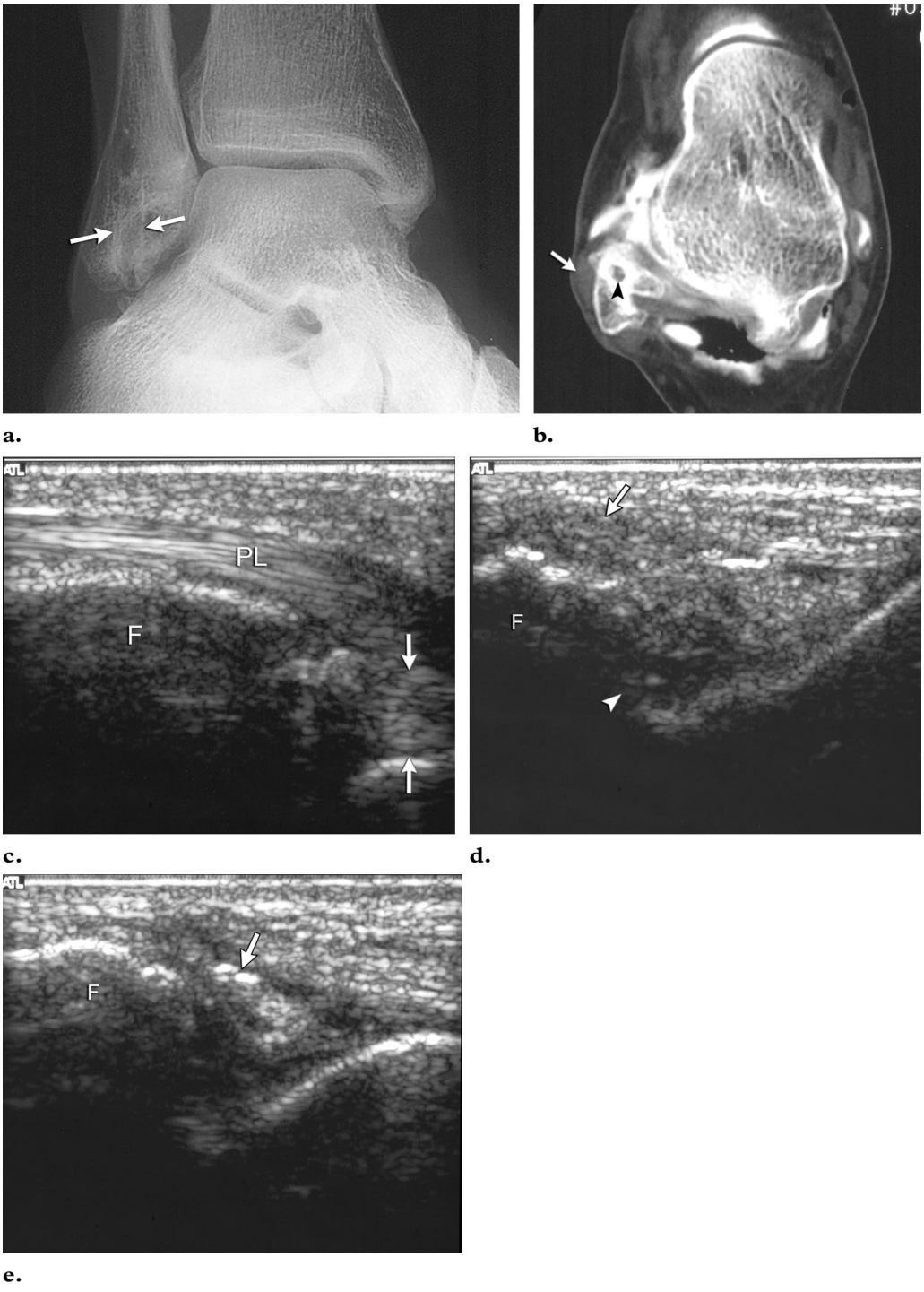

a. **b.** **c.** **d.** **e.**



Figure 11. Drawing illustrates rerouting of the peroneus brevis tendon (red) through fibular (dashed lines) and talar tunnels with distal reattachment (Watson-Jones procedure). The peroneus longus tendon is shown in yellow.

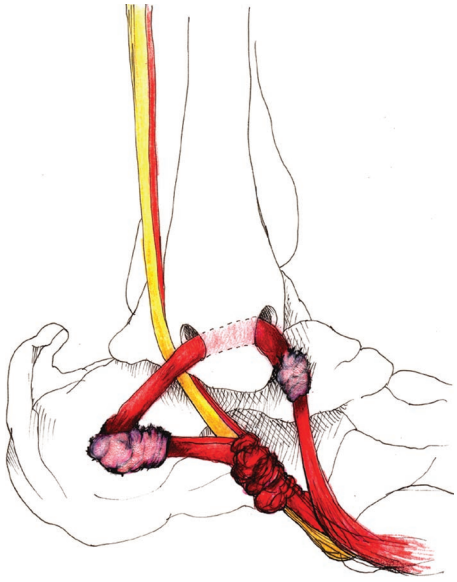

Figure 12. Drawing illustrates peroneal tendon split and rerouting (Chrisman-Snook procedure). A portion of the split peroneus brevis tendon is seen coursing through a fibular tunnel and is secured to the talus and calcaneus with periosteal flaps before reattachment to the distal portion of the tendon. The peroneus longus tendon is shown in yellow.

belly of the peroneus brevis muscle, which is sutured to the peroneus longus tendon. A variation of the peroneus brevis tendon loop procedure involves two fibular tunnels and an additional talar tunnel (Watson-Jones procedure) (Fig 11).

Peroneus Brevis Tendon Split and Rerouting

In peroneus brevis tendon split and rerouting, the tendon is split longitudinally, with half of the tendon separated proximally from the intact peroneus brevis muscle-tendon unit (Fig 12). This separated tendon courses posterior from its attachment to the fifth metatarsal bone and courses beneath the periosteum of the talus, through a fibular tunnel in an anteroposterior direction, and under a segment of calcaneal periosteum (Figs 12, 13). The tendon is then brought anteriorly and sutured upon itself near the fifth metatarsal bone. The Chrisman-Snook procedure is an example of peroneus brevis tendon split and rerouting, which serves to reconstruct the anterior TFL and CFL (5,9). Use of only one-half of the peroneus brevis tendon allows preservation of the dynamic function of the peroneus brevis muscle (3).

At radiography, a fibular tunnel is typically visualized (Fig 13). However, a subperiosteal tunnel within the talus and calcaneus may be difficult to identify. At cross-sectional imaging, the peroneus brevis tendon can be traced proximally from the base of the fifth metatarsal bone to the talus, through the fibular tunnel to the calcaneus, and then back to itself, where suture material is typically evident (Figs 12, 13).

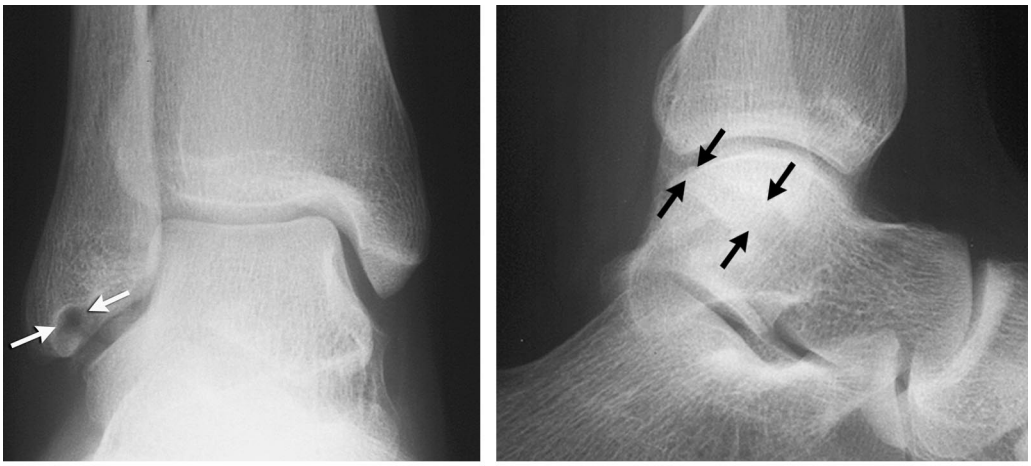

a. b.

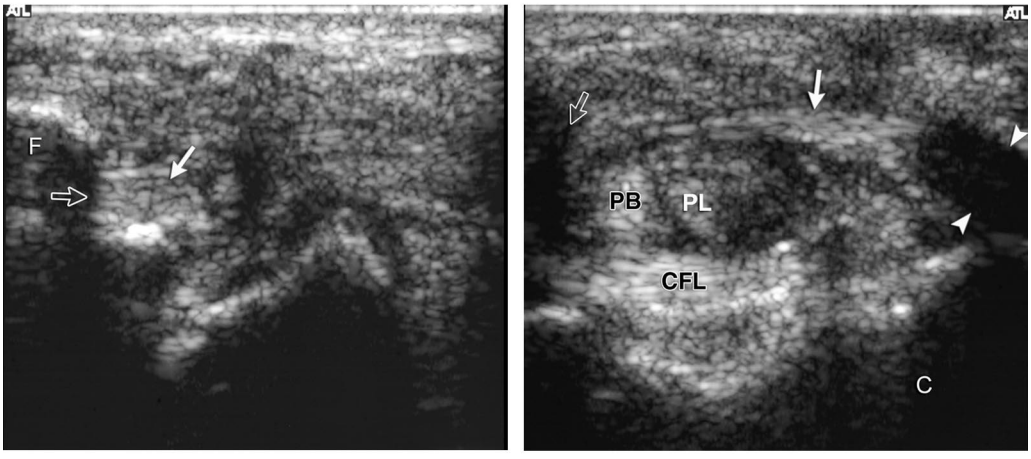

c. d.

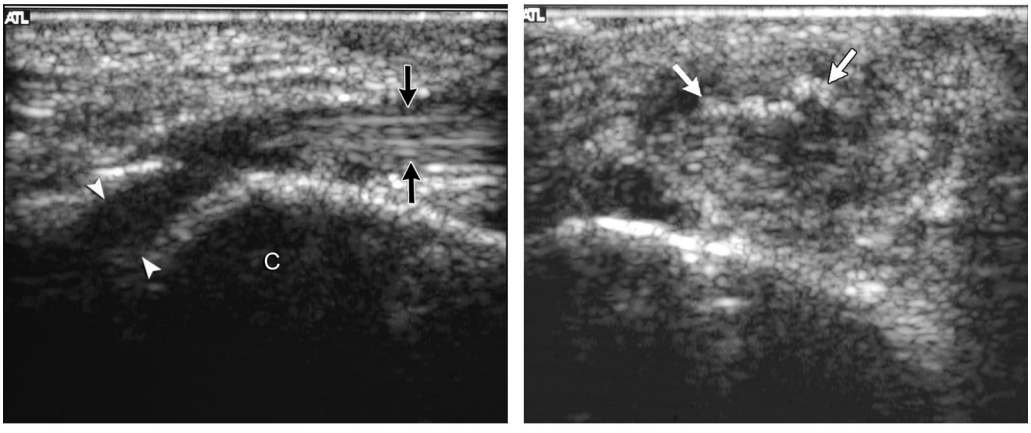

e. f.

Figure 13. Peroneus brevis split and rerouting (Chrisman-Snook procedure) in a 19-year-old woman. **(a, b)** Anteroposterior **(a)** and oblique **(b)** radiographs of the ankle show a fibular tunnel (arrows). **(c)** Longitudinal US image shows a portion of the split peroneus brevis tendon (solid arrow) entering the anterior end of the fibular tunnel (open arrow). *F* = fibula. (Left side of image is proximal.) **(d)** Longitudinal US image shows a segment of the peroneus brevis tendon (solid arrow) between the posterior aspect of the fibular tunnel (open arrow) and the calcaneal periosteal flap (arrowheads). *C* = calcaneus, *CFL* = calcaneofibular ligament, *PB* = spared half of the peroneus brevis tendon, *PL* = peroneus longus tendon. (Left side of image is superior.) **(e)** Longitudinal US image shows the peroneus brevis tendon (arrows) exiting the periosteal calcaneal tunnel (arrowheads). *C* = calcaneus. (Left side of image is posterior.) **(f)** Transverse US image of the split segment of the peroneus brevis tendon shows a distal tendon anastomosis (arrows).

Summary

Radiographs indirectly demonstrate evidence of lateral ankle ligament surgery: Suture anchors in the expected location of the anterior TFL indicate direct ligament repair, whereas visualization of a fibular tunnel indicates peroneus brevis tendon rerouting or loop. Similarly, identification of a suture anchor or fibular tunnel at MR imaging provides clues to the surgical procedure used. Although both US and MR imaging demonstrate rerouted tendons as part of lateral ankle reconstruction, MR imaging has the advantage of depicting the rerouted tendon within an osseous tunnel if present. T1-weighted images are helpful because the low-signal-intensity tendon within the osseous tunnel is easily seen surrounded by marrow with fat signal intensity. Artifact from suture material may obscure the tendon at MR imaging but not at US. With both modalities, the integrity of the rerouted peroneus brevis tendon is best evaluated by following the tendon proximally from its insertion at the base of the fifth metatarsal bone because this distal attachment typically remains unchanged. The rerouted tendon, whether all or only part of the tendon has been rerouted, can then be traced proximally through various osseous tunnels to its reattachment site.

It is important not to misinterpret the imaging appearances of lateral ankle reconstruction as tendon or bone disease. Familiarity with the surgical techniques used in reconstruction helps explain the imaging findings typically seen at radiography, US, and MR imaging.

Acknowledgment: We thank Robert W. Jacobson, MFA, for the medical illustrations.

References

1. St Pierre R, Allman F Jr, Bassett FH, Goldner JL, Fleming LL. A review of lateral ankle ligamentous reconstructions. Foot Ankle 1982; 3:114–123.
2. Liu SH, Baker CL. Comparison of lateral ankle ligamentous reconstruction procedures. Am J Sports Med 1994; 22:313–317.
3. Colville MR. Surgical treatment of the unstable ankle. J Am Acad Orthop Surg 1998; 6:368–377.
4. Renström PA. Persistently painful sprained ankle. J Am Acad Orthop Surg 1994; 2:270–280.
5. Baxter DE, Mann RA, Sammarco GJ. Traumatic injuries to the soft tissues of the foot. In: Mann RA, ed. Surgery of the foot. St Louis, Mo: Mosby, 1986; 456–481.
6. Hamilton WG, Thompson FM, Snow SW. The modified Broström procedure for lateral ankle instability. Foot Ankle 1993; 14:1–7.
7. Broström L. Sprained ankles. Acta Chir Scand 1966; 132:551–565.
8. Björkenheim JM, Sandelin J, Santavirta S. Evans procedure in the treatment of chronic instability of the ankle. Injury 1988; 19:70–72.
9. Snook GA, Chrisman OD, Wilson TC. Long-term results of the Chrisman-Snook operation for reconstruction of the lateral ligaments of the ankle. J Bone Joint Surg Am 1985; 67:1–7.